

Endoscopic-assisted Enucleation of Radicular Cysts — A Case Report

Abdullah KAHAIRI¹, Shamim AHMED KHAN², Ahmad AMIROZI³

Submitted: 28 Jul 2009

Accepted: 6 Oct 2009

¹ Department of Otolaryngology-Head & Neck Surgery, Kulliyah of Medicine, International Islamic University Malaysia

² Department of Otolaryngology-Head & Neck Surgery, School of Medical Sciences, Universiti Sains Malaysia, Jln Raja Perempuan Zainab II, 16150 Kubang Kerian, Kelantan, Malaysia

³ Department of Ear Nose and Throat, Hospital Tengku Ampuan Afzan, Kuantan, Malaysia

Abstract

The standard management for the majority of benign jaw cysts is enucleation, marsupialisation, curettage and decompression. Enucleation has the advantage that the whole specimen is sent for microscopic evaluation so that more sinister pathological processes (i.e. squamous cell carcinoma) may not be missed. In a large cystic lesion, enucleation is still possible, but technical difficulties might be encountered. In such instances, inevitable damage can occur to the surrounding structures. We report a case of a large radicular cyst of the maxilla that was enucleated via endoscopic assistance through the Caldwell Luc approach.

Keywords: jaw cyst, endoscope, enucleation, Caldwell Luc, medical sciences

Introduction

Epithelial jaw cysts are the most common cause of benign swelling of the jaw and can be further divided into inflammatory and developmental types. Radicular cysts are the most common among the inflammatory types and occur solely at the apices of non-vital teeth as a reactive process, especially in adults. They form as a result of the stimulation of the odontogenic epithelium (rests of Malassez) in the vicinity of the root tip, by the necrotic pulp, and the contents of the root canal system. Different forms of treatment of jaw cysts have been described, such as enucleation, curettage, decompression, marsupialisation and resection with or without jaw continuity. However, in large cysts that extend into the maxilla, difficulties may be encountered due to the limited exposure and access for the enucleation unless a generous incision is made. In this situation, a rigid endoscope used in a Caldwell Luc procedure may facilitate the enucleation of the cyst.

Here, we report a case of a large radicular cyst that displaced the floor of the maxillary sinus superiorly and was enucleated via endoscopic assistance via the Caldwell Luc approach.

Case Report

A 26-year-old female presented with persistent frontal headaches that had lasted for four months associated with left-sided facial fullness and pain, rhinorrhoea, itchiness, post-nasal drip, and alternating nasal blockage. She was initially treated for allergy rhinitis with steroid nasal spray and showed some response. However, the frontal headache persisted along with the left facial fullness and pain. There was no significant past medical history. Upon examination, there was a mild swelling on the left side of her face, with obliteration of the nasolabial and nasomaxillary groove but with normal-looking overlying skin. Anterior rhinoscopy revealed a slight bulging of the floor of the left nostril, and it appeared to be soft in consistency upon palpation using a nasal septum elevator. Examination of the middle third of the left nostril by rigid 0-degree endoscopy revealed a medialised uncinat process, and no mass or pus was observed in the middle meatus. There were no enlarged regional lymph nodes. All cranial nerves were intact. The occipito-mental view of her sinus X-ray revealed only haziness of her left maxillary sinus area. A CT scan of the paranasal sinus revealed a well-defined expansile, non-enhancing, homogenous soft tissue mass occupying the whole left maxillary sinus, massively affecting the surrounding

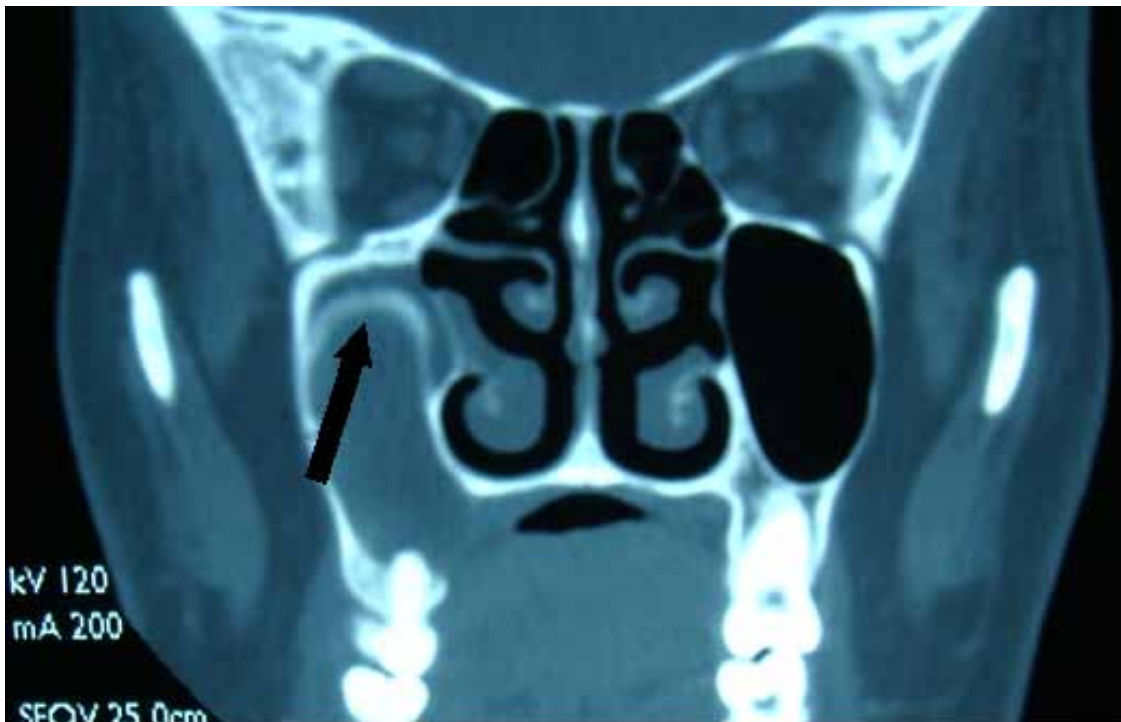

Figure 1: CT scan picture illustrating a cystic mass displacing the floor of maxillary sinus (arrow) giving a double wall appearance

walls and exhibiting a double wall appearance superiorly (Figure 1). The mass was arising from the alveolar process of the left maxilla without the presence of the impacted tooth within. Based on the patient's history, physical examination and CT scan findings, we concluded that she had a benign jaw cyst. Excision of the cyst was planned and intraoperatively under general anaesthesia, a sublabial incision was employed after local anaesthesia was administered at the upper left gingivobuccal sulcus. Initially, enucleation was performed under direct visualisation, but as the cyst extended superiorly, pushing the floor of the maxillary sinus until it approached the roof of the maxillary sinus, further enucleation was hampered by poor visibility and illumination. From this point onward, enucleation was carried out with the assistance of a rigid (0-degree) endoscope, which was held with the most dominant hand while the other hand performed the enucleation. The cyst was noted to have been attached firmly to the root of the erupted left upper canine, which was subsequently extracted. The patient's postoperative period was uneventful, and she was discharged on the second postoperative day. Postoperative histopathological examination reported the mass as a radicular cyst.

Discussion

Endoscopy is the visual examination of the inside part of a body cavity, structure or hollow organ. The word endoscopy comes from the Greek words 'endo,' meaning 'inside,' and 'skopein,' meaning 'to examine.' (1). One of the advantages of an endoscopic technique is the avoidance of extensive tissue damage during the operation, thus minimising blood loss and reducing postoperative morbidity. There are many options in the management of benign jaw cysts, such as enucleation, curettage, decompression, marsupialisation, and resection with or without jaw continuity. However, enucleation has the advantage that the whole specimen can be sent for a complete histological evaluation. This is recommended to ensure that a more sinister pathological lesion is not missed, such as squamous cell carcinoma (2). In smaller-sized cysts, enucleation can be accomplished without many problems. However, in some instances, the cyst can be very big and can occupy the entire maxillary sinus, making complete removal difficult unless a generous incision is made either sublabially or via a lateral rhinotomy incision. This approach is overly aggressive for such a benign lesion. In this situation, the assistance from a rigid nasoendoscope (4.0-mm, 0-degree

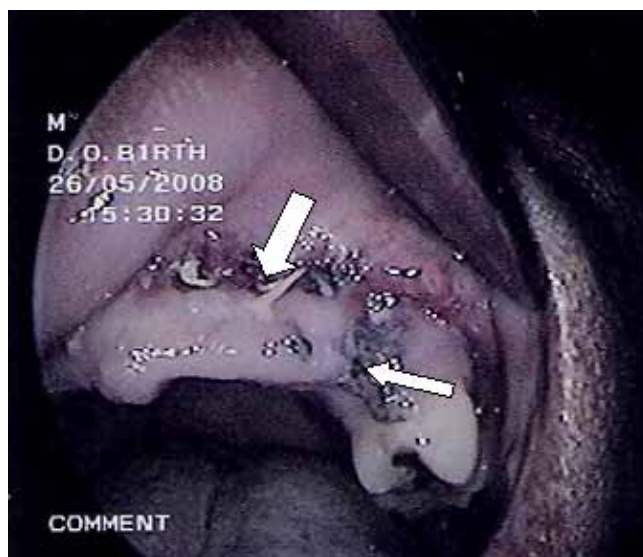


Figure 2: Sublabial incision scar (thick arrow) and site of extracted left canine (thin arrow)

Hopkins endoscope) is helpful in guiding the enucleation of the cyst safely without affecting the surrounding tissues. A suction elevator was used to separate the cyst from the surrounding bone, as the surgical field was slightly bloody. This technique not only reduces the size of the incision required, but it also offers a superior visualisation of the difficult corners and angles around the posterior and superior aspects of the lesion. Furthermore, it provides good illumination and a clear and magnified visualisation of the operating field, and thus it results in a more conservative surgery with precise enucleation. Furthermore, with the presence of important structures nearby, such as the orbital apex, infra-orbital nerve and internal maxillary artery, meticulous enucleation is necessary and can be safely performed via endoscopic assistance.

There is very little literature describing the use of an endoscope for the removal of large benign jaw cysts transorally, although many surgeons have used an endoscope to extract the impacted tooth transnasally. Micozkadioglu and Erkan reported a case in which they removed a dentigerous cyst and extracted the tooth transnasally (3). Similarly, Di Pasquale and Shermetoro used the same technique in their patient (4). Suarez-Cunqueiro et al. described a case in which they used an endoscope to facilitate the enucleation of a jaw cyst (1). However, in that case, the cyst arose from the right lower third molar region, as compared to our case, which involved the maxilla.

In our case, the benign cyst pushed the floor of the left maxillary sinus and further displaced it superiorly to meet the roof of the maxillary sinus, thus exhibiting a double wall appearance on the coronal CT scan. Our initial plan was to remove the cyst via a sublabial approach. However, we encountered difficulties when approaching the superior and posterior aspect of the cyst wall. From this point onward, enucleation was carried out with the assistance of a rigid endoscope, which clearly outlined the difficult corners and provided good illumination and visualisation to the surgeon for further precise enucleation. Jaw cysts are commonly managed by the oromaxillofacial team, but in certain circumstances the presentation is not as straightforward as in our case, and referral to the otorhinolaryngology (ORL) unit was required. Handling of a rigid endoscope is a routine practice in the ORL clinic as well as in the operating room. Therefore, in cases with large cystic lesions, a combined approach between the oromaxillofacial and ORL teams is imperative to provide the most effective treatment for the patient. The decision to extract the tooth was probably unjustified in this case, after it was reviewed and discussed retrospectively with the oromaxillofacial team. Root treatment could probably have been done, and the tooth could have been saved from unnecessary extraction.

In conclusion, endoscopic-assisted enucleation of benign jaw cysts is a useful technique for large cysts because it provides superior intraoperative illumination, magnification and visualisation. This technique provides the surgeon

with an alternative approach for the removal of large jaw cysts. It reduces postoperative morbidity and avoids unnecessary tissue damage (the size of our sublabial incision was ~ 1.5 cm (Figure 2), and the size of the cyst was ~ 2.0 x 3.5 cm). A combined approach between maxillofacial and ORL teams is recommended in isolated cases of large cyst for the maximum benefit to the patients.

Author's contributions

Conception and design: KA

Data analysis and interpretation: SAK

Drafting of the article: AA

Correspondence

Dr Kahairi Abdullah
 MBBS, MMed (ORL-HNS) (USM)
 Department of Otolaryngology-Head & Neck Surgery
 Kulliyyah of Medicine,
 International Islamic University Malaysia
 Jalan Hospital
 25100 Kuantan
 Pahang, Malaysia
 Tel:+6013-939 9581
 Fax:+609-517 7624
 E-mail: kahairiabd@yahoo.com

References

1. Suarez-Cunqueiro MM, Schoen R, Schramm A, Gellrich NC, R. Schmelzeisen. Endoscopic Approach to Removal of an Ectopic Mandibular Third Molar. *Brit J Oral Max Surg.* 2003;**41(5)**:340–342.
2. Bradley N, Thomas DM, Antoniadis K, Anavi Y. Squamous Cell Carcinoma Arising in an Odontogenic Cyst. *Int J Oral and Max Surg.* 1988;**17(4)**:260–263.
3. Micozkadioglu SD, Erkan AN. Endoscopic Removal of a Maxillary Dentigerous Cyst. *B-ENT.* 2007; **3(4)**:213–216.
4. Di Pasquale P, Shermetoro C. Endoscopic Removal of a Dentigerous Cyst Producing Unilateral Maxillary Sinus Opacification on Computed Tomography. *Ear Nose Throat J.* 2006; **85**:747–748.