

Bilateral idiopathic optic perineuritis in a young Malay woman: A case report

Ayesha Mohd Zain, Umi Kalthum Md Noh, Mushawiahti Mustapha, Norshamsiah Md. Din, Mae Lynn Catherine Bastion

Department of Ophthalmology, Universiti Kebangsaan Malaysia Medical Centre, Kuala Lumpur, Malaysia

Abstract

A 28-year-old Malay woman presented with severe loss of vision in both eyes associated with periocular pain on eye movement. She was completely blind at presentation and examination showed optic discs swelling. Optic nerve imaging showed 'doughnut sign', characteristic of optic perineuritis. Steroid was given over six months. Visual function improved gradually and was maintained at one year follow-up. This case highlights the importance of differentiation between optic neuritis and optic perineuritis as visual recovery depends on prolonged management with corticosteroid in optic perineuritis.

INTRODUCTION

Optic perineuritis (OPN) is an inflammatory condition involving the meningeal sheath which surrounds the optic nerve. Visual loss in OPN results from mechanical compression to the optic nerve from surrounding mass, which causes optic nerve ischaemia.¹ OPN should be treated with corticosteroids and prolonged treatment is important to ensure visual recovery and remission of the condition. We report an interesting case of bilateral OPN with severe visual loss in a young Malay woman which was successfully managed with prolonged oral steroid.

CASE REPORT

A 28-year-old Malay woman presented with bilateral severe loss of vision of three days duration. It was rapidly deteriorating with associated pain on eye movement. She reported a history of upper respiratory tract infection and fever a week previously, which spontaneously resolved without treatment. There was no skin rash, headache or vomiting.

On examination, she had no perception to light in the right eye, and hand motion vision in the left eye at all quadrants. Both pupils were dilated and non-reactive to light. The anterior segment examination and intraocular pressure was normal. Funduscopy revealed bilateral hyperemic and swollen optic discs. (Figure 1). She did not have any other focal neurological deficit. She could not perceive colours and was not able to perform visual field test.

The laboratory test revealed normal haematological profile, connective tissue screening test and serum B12 level. Serum aquaporin 4 antibody and Mantoux test were negative. An urgent computed tomography showed evidence of maxillary sinusitis with normal optic nerve calibre. On T2-weighted image of magnetic resonance imaging (MRI), there was hyperintensity of the perineural sheath in both optic nerves with characteristic 'doughnut' sign.

The patient was started on a week course of antibiotic for maxillary sinusitis. Intravenous methylprednisolone 250 mg four times a day was initiated for the first three days, which was followed by oral prednisolone 1 mg/kg daily. There was no visual improvement following completion of intravenous steroid, and for the first two weeks of treatment. The oral prednisolone was tapered by 5mg every two weeks.

At third weeks of treatment, the right eye vision had improved to hand motion and counting finger for the right and left eyes respectively. By sixth week, her vision continued to improve, with resolution of optic discs swelling. (Figure 3) Visual acuity at this stage was 6/24, N48 on the right eye and 6/60, N48 on the left eye. Visual field test revealed bilateral ring scotoma with preservation of central vision. The oral prednisolone was continued for six months, the dose was reduced by 2.5 mg every two weeks. By six months, her vision has improved to 6/9, N6 for the right eye and 6/12, N8 for the left eye. Both colour vision test and visual field returned to normal. The visual acuity was maintained at one year follow-up.

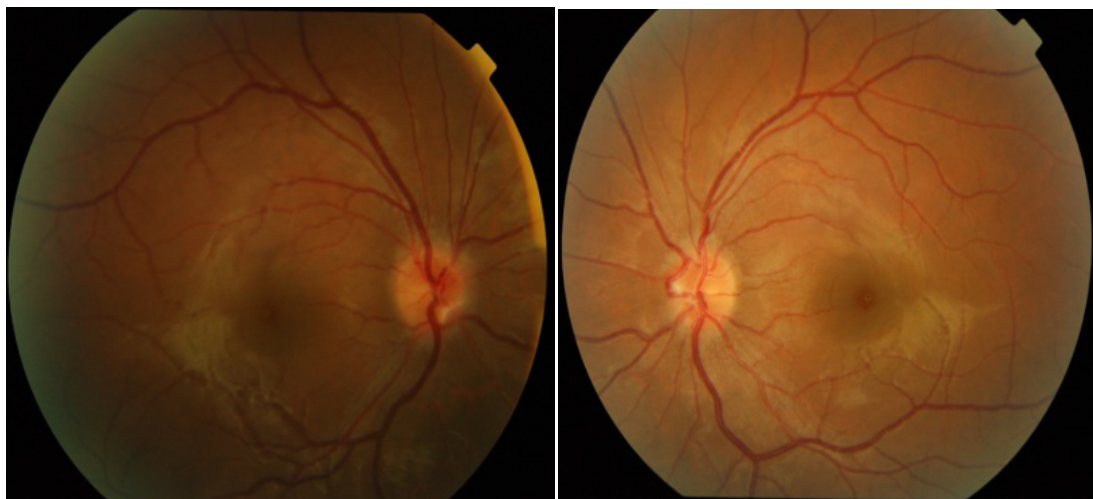


Figure 1: Fundus photograph shows hyperemic and swollen optic disc on both right and left eyes

DISCUSSION

OPN describes a condition characterized by optic nerve sheath inflammation, and is thought to be an idiopathic orbital inflammatory disease. Despite being sub-grouped as idiopathic, OPN may have infective causes, although no aetiology cause is found in most cases.² The typical magnetic resonance imaging (MRI) features is the characteristic enhancement surrounding the optic nerve, either the 'tramtrack' sign on axial view, or 'doughnut' sign on coronal view, from the inflamed optic nerve sheath.³ The characteristic post-contrast MRI of the optic nerve is seen even in cases with optic atrophy.⁴ Radiographic features is important in distinguishing the OPN from optic neuritis, as the clinical presentations of both

conditions are similar.⁴ MRI may distinguish the intraneural enhancement of optic neuritis from the perineural hyperintensity seen in OPN. Optic nerve sheath meningioma may also give rise to similar MRI findings seen in OPN, hence, the diagnosis should be based both on clinical presentations and neuroimaging. On the other hand, CT scan does not provide adequate special resolution to differentiate the perineural pathology in OPN from optic neuritis.

Idiopathic OPN presents in the older age group than the demyelinating optic neuritis.⁵ Although rare, OPN can also presents with insidious onset of progressive visual deterioration over weeks, associated with typical periocular discomfort or pain exacerbated by eye movement. Subacute

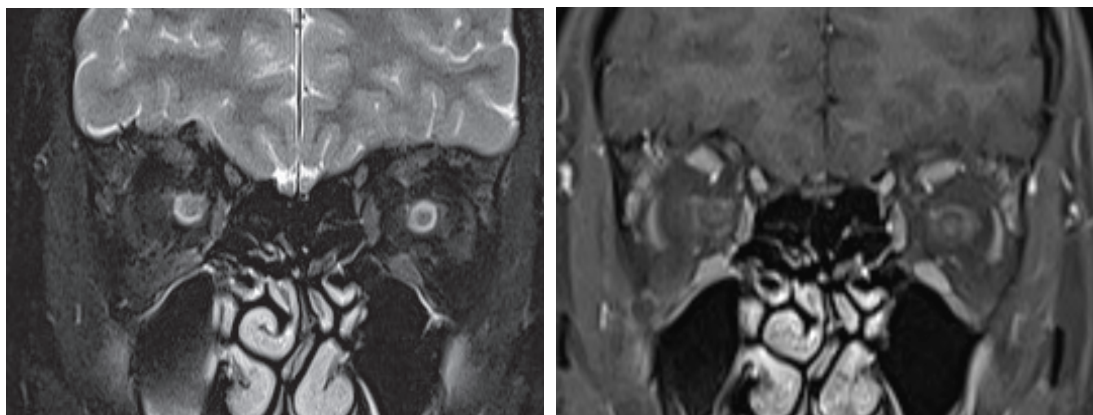


Figure 2: Coronal T2-weighted image of the orbits showing the 'doughnut sign' of fluid in the swollen optic nerve sheath suggestive of perineural sheath inflammation (right). The coronal T1 fat suppressed contrast enhanced image shows the perineural sheath enhancement (left).

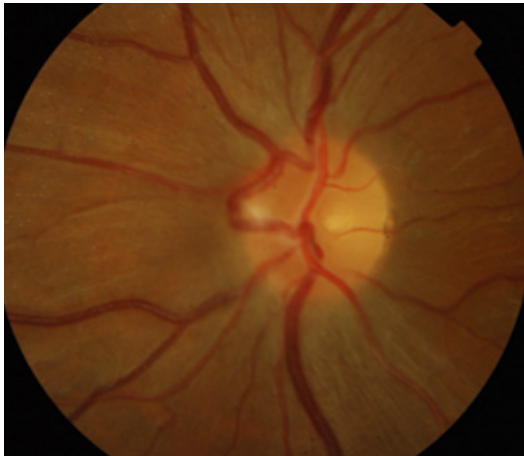


Figure 3: Marked improvement of optic disc swelling at six weeks of treatment

severe loss of vision is therefore an uncommon clinical feature. The more common scenario is a rapid visual deterioration over a few days.

The management of idiopathic inflammatory OPN requires long-term systemic corticosteroid. In most cases, early and dramatic visual improvement occurs following institution of steroid, although there continues to be slow progress of the disease process and visual deterioration over weeks.² Our patient presented with acute rapid deterioration of vision. Corticosteroid treatment was initiated at the early phase of the disease. No improvement was noted after completion of high dose intravenous steroid. Good vision was only obtained after four months of oral steroid. Although there have been reports of poor response to corticosteroid, these are usually due to treatment delay.² However, according to a previous report, despite more than three months of treatment initiation delay, OPN can show improvement with the immunosuppressant therapy. Optic atrophy is the only factor which predicts unresponsiveness towards steroids.³

Prolonged systemic steroid therapy is associated with many adverse effects, such as weight gain, reduced bone density and infection.⁶ Compliance is thus an important aspect of management, and counselling to patients is required to improve compliance.

Data on the prevalence, natural history and treatment response of Asian patients with OPN is limited, although there is a report that OPN is more common among Chinese population compared to the Caucasian population.⁴ In 2015, two cases of idiopathic OPN were reported in Malaysia. Both patients were females, age 15 and

44 year respectively with sudden onset of visual deterioration. Diagnoses of OPN were based on MRI findings, and the patients were given high dose steroid with slow tapering. No recurrence was noted after one year.^{7,8}

Another case of OPN secondary to tuberculosis was reported in 2012. Clinically the patient had unilateral gradual loss of vision associated with features of orbital apex syndrome. The patient had history of contact with tuberculosis, markedly raised erythrocytes sedimentation rate, and strongly positive Mantoux test of 20mm. MRI of the orbit was highly suggestive of optic perineuritis. Despite receiving anti-tuberculosis and oral prednisolone, there was no significant visual improvement, though there was full return of extraocular muscle function.⁹

In conclusion, it may be difficult clinically to differentiate OPN from optic neuritis. MRI plays a vital role in the differentiation. As OPN may require long term steroid, such a differentiation is important.

DISCLOSURE

Financial support: None

Conflict of interest: None

REFERENCES

1. Margo CE, Levy MH, Beck RW. Bilateral idiopathic inflammation of the optic nerve sheath. *Ophthalmology* 1989; 96:200-6.
2. Purvin V, Kawasaki A, Jacobson DM. Optic perineuritis: clinical and radiographic features. *Arch Ophthalmol* 2001; 119:1299-306.
3. Tatsugawa M, Noma H, Mimura T. High dose steroid therapy for idiopathic optic perineuritis: a case series. *J Med Case Rep* 2010;4:404.
4. Cheng ACO, Chan NCY, Chan CKM. Acute and subacute inflammation of the optic nerve and its sheath: clinical features in Chinese patient. *Hong Kong Med J* 2012;18:115-22
5. Kang HK, Kim HY. Clinical manifestations of idiopathic optic perineuritis in Korea. *J Korean Ophthalmol Soc* 2012; 53:1016-22.
6. Stanbury RM, Graham EM. Systemic corticosteroid therapy- side effects and their management. *Br J Ophthalmol* 1998;82:704-8.
7. Ahmad A, Shatriah I, Hitam WHW, Yunus R. A unilateral optic perineuritis in a teenager – A case report. *Brain Dev* 2015; 37:635-7.
8. Teh WM, Ibrahim M, Hitam WHW. Bilateral idiopathic optic perineuritis with severe vision loss: A case report. *Asian Pac J Trop Dis* 2015;5:583-5.
9. Raghobi A, Hitam WHW, Noor RAM, Embong Z. Optic perineuritis secondary to tuberculosis: A rare case presentation. *Asian Pac J Trop Biomed* 2012; S1206-8.