

CASE REPORT

Triple cancer: chronic lymphocytic leukemia with bladder and prostate carcinoma

Smeeta GAJENDRA MD, Rashi SHARMA DCP and Manas Kumar SAHOO* MD

Department of Pathology and Laboratory Medicine, Medanta-The Medicity, Haryana and *Department of Nuclear Medicine, All India Institute of Medical Science, New Delhi, India

Abstract

B-cell chronic lymphocytic leukemia/small lymphocytic lymphoma (CLL/SLL) is a common lymphoproliferative disorder with an increased risk of developing subsequent neoplasms of epithelial and mesenchymal origin. The decreased immunity and B-cell dysfunction in CLL probably accounts for this emergence of second malignancies. We report a case of synchronous bladder transitional cell carcinoma (TCC) and prostatic carcinoma with CLL. A 74-year-old male who underwent transurethral resection of the prostate (TURP) for benign prostatic hyperplasia 2 years before, presented with recurrent urinary tract infection. Peripheral blood smear revealed leukocytosis with absolute lymphocytosis (absolute lymphocyte count: 37870 cells/mm³). Flow cytometric immunophenotyping revealed 75% abnormal lymphoid cells which were positive for CD 19, CD5, CD23, CD22, CD200, CD20 (moderate) with lambda light chain restriction and negative for CD3, CD10, FMC7, CD38, CD138, IgM, CD103, CD123. ¹⁸F Fluorodeoxyglucose (FDG) positron emission tomography/computed tomography (PET/CT) showed increased metabolic activity of the left lateral wall of the urinary bladder extending to the left UV junction, adjacent part of trigone and bladder neck region along with multiple heterogeneous enhancing areas with increased FDG avidity within the prostate. Transurethral resection of the bladder tumour by cystoscopy was performed. Histopathology showed high grade, muscle invasive urothelial carcinoma. Due to presence of uptake in the prostate, transurethral resection of the prostate was done and histopathology revealed adenocarcinoma of prostate (prostate specific antigen- positive), Gleason grade III+III and Gleason score 6. A high index of suspicion is required to detect synchronous and metachronous malignancies. Ancillary studies such as immunohistochemistry, flow cytometry and PET/CT are often essential for detection and an accurate diagnosis.

Keywords: synchronous malignancy, transitional carcinoma bladder, chronic lymphocytic leukemia, PET/CT, prostate adenocarcinoma

INTRODUCTION

B-cell chronic lymphocytic leukemia/small lymphocytic lymphoma (CLL/SLL) is one of the common lymphoproliferative disorders with an increased risk of developing subsequent neoplasms of epithelial and mesenchymal origin. The decreased immunity and B-cell dysfunction in CLL probably accounts for this emergence of secondary malignancy. Malignant lymphomas have been reported previously to coincide with adenocarcinomas of the stomach and, rarely, the kidney, breast, colon, liver or lung.^{1,2} We report a rare case of a 74-year-old male with

synchronous bladder transitional cell carcinoma (TCC) and prostatic carcinoma with CLL. The occurrence of multiple primary cancers (MPC) is very rare. They commonly occur more in elderly individuals, as the incidence of malignancies increases with age. MPC is classified into two categories depending on the time of diagnosis of each primary site: synchronous/simultaneous occurrence of more than one tumour or metachronous/ successive occurrence of another tumour in a known case of carcinoma. Only very few cases of triple malignancy have been reported in the literature.³

CASE REPORT

A 74-year-old male who underwent transurethral resection of the prostate (TURP) for benign prostatic hyperplasia 2 years before, presented with recurrent urinary tract infection for a few months, and hematuria and frequency of micturition for 1 to 2 months. His haemoglobin level was 130 gm/L, total leucocyte count was $50.27 \times 10^9/L$ and platelets count was $242 \times 10^9/L$. Peripheral blood smear revealed leukocytosis with absolute lymphocytosis (absolute lymphocyte count: 37870 cells/ mm^3) and many smudge cells were seen. Flow cytometric immunophenotyping revealed 75% abnormal lymphoid cells which were positive for CD 19, CD5, CD23, CD22, CD200, CD20 (moderate) with lambda light chain restriction and negative for CD3, CD10, FMC7, CD38, CD138, IgM, CD103, CD123, confirming the diagnosis of chronic lymphocytic leukemia (Figure 1). CD200 expression in chronic lymphocytic leukemia was

as bright as or brighter than normal peripheral blood B cells and also helped in differentiating it from mantle cell lymphoma.⁴

Abdominal sonography was done which disclosed three tumour masses on the dome of the bladder, 1 cm each. Contrast-enhanced computed tomography (CECT) abdomen showed asymmetrically thickened bladder wall along left lateral/ posterior / inferior margin with left ureter-vesicle (UV) junction involvement and left hydroureteronephrosis (Figure 2 A :upper panel). ¹⁸F Fluorodeoxyglucose (FDG) positron emission tomography/computed tomography (PET/CT) showed diffuse thickening with increased metabolic activity of the left lateral wall of the urinary bladder extending to the left UV junction, adjacent part of trigone and bladder neck region (Figure 2 A: lower panel). There were also multiple heterogeneous enhancing areas with increased FDG avidity within the prostate.

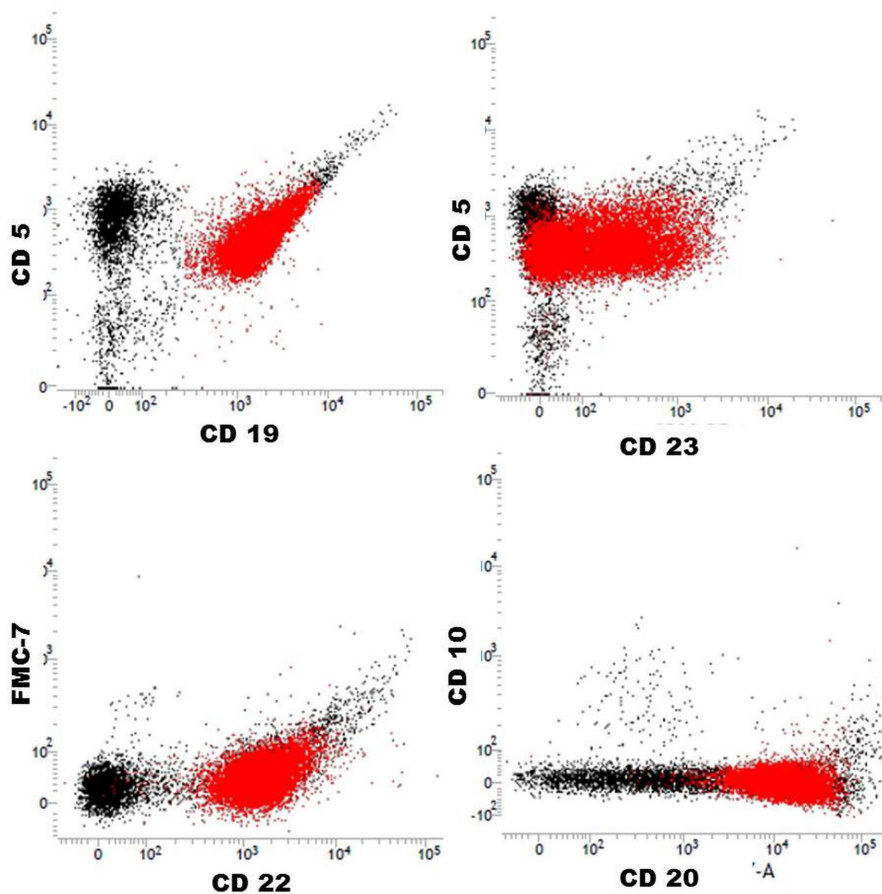


FIG. 1: Flow cytometric immunophenotyping showing abnormal lymphoid cells which are positive for CD19, CD5, CD23, CD20, CD22 and negative for CD10, FMC-7.

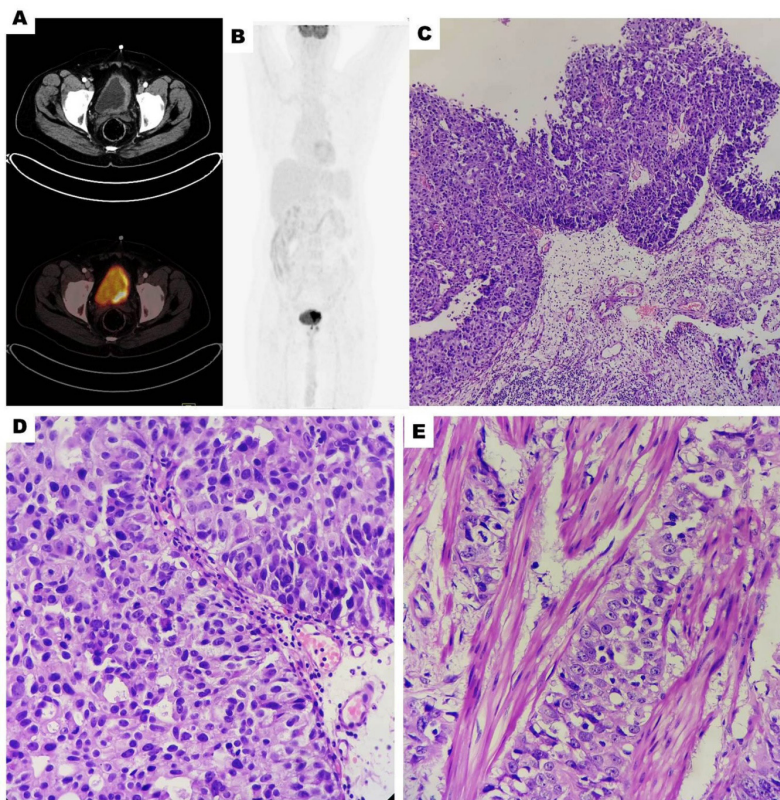


FIG. 2: (A) CT and ^{18}F -FDG PET/CT, Cross section images. (B) Maximum intensity projection (MIP) image showing diffuse thickening with increased metabolic activity of left lateral wall of urinary bladder. (C) Histopathology of bladder tumour, Hematoxylin & eosin x100, (D) higher magnification of bladder tumour, Haematoxylin & eosin x400, (E) Bladder tumour showing muscle invasion. Haematoxylin & eosin x400)

Cystoscopy revealed that the whole of the left postero-lateral wall was full of tumour mass and transurethral resection of the bladder tumour by cystoscopy was performed.

Histopathological examination showed high grade, muscle invasive urothelial carcinoma (Figure 2- C,D,E). Due to the presence of FDG uptake in PET/CT scan trans-urethra resection of prostate was done and histopathology revealed adenocarcinoma of prostate, Gleason grade III+III and Gleason score 6. Immunohistochemistry showed strong positivity for prostate specific antigen (PSA) whereas no expression of carcinoembryonic antigen (CEA) was detected in tumour cells (Figure 3). These findings confirmed the diagnosis of primary prostate adenocarcinoma. PSA immunostaining was also performed for the bladder tumour which was negative, thus ruling out the possibility of prostatic adenocarcinoma spread to the bladder.

Bone marrow aspiration showed infiltration

by approximately 80% abnormal small lymphoid cells. Bone marrow biopsy revealed diffuse infiltration by small lymphoid cells of morphology consistent with CLL. There was no evidence of metastatic tumour cells in the bone marrow preparation.

Systemic chemotherapy with carboplatin and gemcitabine was administered.

DISCUSSION

Synchronous malignancy is defined as the occurrence of two tumours within a period of 6 months.⁵ Certain organs, such as gastrointestinal tract, skin, liver and lungs, seem to have an increased predilection for synchronous epithelial and hematopoietic neoplasms.⁶ In 2001, the SEER Program analyzed 16,367 patients with CLL and quantified the risk of second cancers. They estimated the overall observed/expected (O/E) ratio to be 1.2. The O/E ratio of bladder cancer was 1.52, but it was restricted to women.⁷

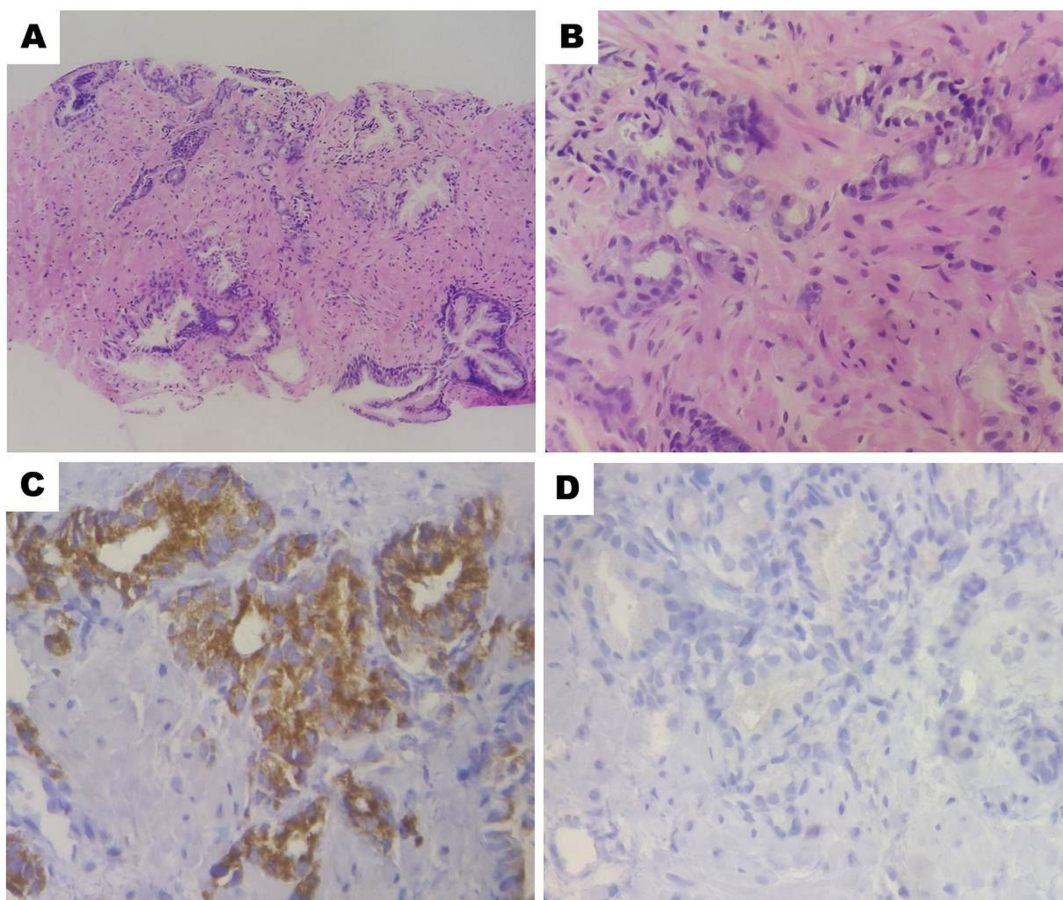


FIG. 3: Histopathology of prostate tumor showing adenocarcinoma, Gleason grade III+III and Gleason score 6 (A) Hematoxylin & eosin x40, (B), Hematoxylin & eosin x400, (C) Immunohistochemical showing positivity for prostate specific antigen, (D) No expression of carcinoembryonic antigen (D).

Tsimberidou *et al* demonstrated that subsequent second malignancies have been reported to occur in 11.2% in CLL/SLL patients at a median of 2.9 years (range, 0 to 17 years). They found that other malignancies occurred 2.2 times more frequently in CLL/SLL patients than in general population.⁸ A large variety of chemical agents, including tobacco, aniline dyes, benzidine, aromatic amines and rubber, and infectious agents have been reported to be causes of bladder cancer.⁹ The aetiology of multiple primary malignant tumors is complex and includes environmental factors, genetic predisposition, immunological impairment, previous medical treatment, gender and hormonal factors.¹⁰

Few cases of bladder and prostate carcinomas in the same patient are reported in the literature. Chun reported that the rate of bladder carcinoma in patients with prostate carcinoma is eighteen times higher ($p < 0.01$) and the rate of prostate

carcinoma in those with bladder carcinoma is nineteen times higher ($p < 0.01$) than expected.¹¹

Rovinescu *et al* reported a case of three primary malignancies; the first tumour was a clear cell carcinoma of the kidney, followed by a transitional cell carcinoma of the bladder and then adenocarcinoma of the prostate.¹² Satoh *et al* also reported the same combination of multiple primary malignancies of urogenital tract in a patient.¹³ Although bladder and prostate carcinoma can coexist in the same individual, appearance of a third malignancy as CLL/SLL is very rare. Occurrence of another tumour in a patient suffering from one cancer could be either a metastasis from primary cancer or another malignancy. Cancer patients should always investigate to rule out the possibility of a metachronous (successive) or a synchronous (simultaneous) malignancy. A high index of suspicion is required to detect synchronous malignancy.

Ancillary studies such as immuno-histochemistry, flow cytometry and PET/CT are often essential for an accurate and complete diagnosis and staging of disease. PET/CT plays an important role in staging of patients with CLL/SLL and can detect Richter's transformation of CLL to diffuse large B-cell lymphoma with a high sensitivity and a high negative predictive value.¹⁴ It is also very helpful to detect multiple coexisting cancers. Presence of lymph nodes may suggest metastasis in a known case of malignancy and can be misdiagnosed as an advance stage of disease. A possibility of second malignancy as lymphoma should be kept in mind and biopsy should be done for a definite diagnosis and staging of disease.

ACKNOWLEDGEMENT

The authors declare no conflict of interest

REFERENCES

1. Koschmieder S, Fauth F, Kriener S, Hoelzer D, Seipelt G. Effective treatment of simultaneous small cell lung cancer and B-cell lymphoma. *Leuk Lymphoma*. 2002; 43(3): 645-7.
2. Gajendra S, Gogia A, Tanwar P, *et al*. Synchronous metastatic pulmonary adenocarcinoma with small cell lymphoma. *Leuk Lymphoma*. 2014; 55(7): 1678-80.
3. Koutsopoulos AV, Dambaki KI, Datseris G, Giannikaki E, Froudarakis M, Stathopoulo E. A novel combination of multiple primary carcinomas: urinary bladder transitional cell carcinoma, prostate adenocarcinoma and small cell lung carcinoma--report of a case and review of the literature. *World J Surg Oncol*. 2005; 3: 51.
4. Challagundla P, Medeiros LJ, Kanagal-Shamanna R, Miranda RN, Jorgensen JL. Differential expression of CD200 in B-cell neoplasms by flow cytometry can assist in diagnosis, subclassification, and bone marrow staging. *Am J Clin Pathol*. 2014; 142(6): 837-44.
5. Lee TK, Myers RT, Scharyj M, Marshall RB. Multiple primary malignant tumors (MPMT): study of 68 autopsy cases (1963-1980). *J Am Geriatr Soc*. 1982; 30(12): 744-53.
6. Afify A, Das S, Mingyi C. Two smalls in one: Coincident small cell carcinoma and small lymphocytic lymphoma in a lymph node diagnosed by fine-needle aspiration biopsy. *Cytojournal*. 2012; 9: 5.
7. Hisada M, Biggar RJ, Greene MH, Fraumeni JF Jr, Travis LB. Solid tumors after chronic lymphocytic leukemia. *Blood*. 2001; 98(6): 1979-81.
8. Tsimberidou AM, Wen S, McLaughlin P, *et al*. Other malignancies in chronic lymphocytic leukemia/small lymphocytic lymphoma. *J Clin Oncol*. 2009; 27(6): 904-10.
9. Lin CL, Lin CY, Chen SW, *et al*. Coexisting transitional cell carcinoma and chronic lymphocytic leukemia/small lymphocytic lymphoma in urinary bladder. *J Chinese Oncol Soc*. 2009; 25(3): 222-8.
10. Müller D, Tomasović-Loncarić C, Galeić-Iljubanić D, Heinzl R, Savić I, Marusić P. Renal cell carcinoma with concurrent urothelial carcinoma of urinary bladder and non-Hodgkin lymphoma. *Coll Antropol*. 2012; 36(3): 1049-52.
11. Chun TY. Coincidence of bladder and prostate cancer. *J Urol*. 1997; 157(1): 65-7.
12. Rovinescu I, Rousseau E. [Considerations relating to multiple primary carcinomas of the urinary tract (author's transl)]. *J Urol Nephrol (Paris)*. 1976; 82(7-8): 621-6.
13. Satoh H, Momma T, Saito S, Hirose S. [A case of synchronous triple primary carcinomas of the kidney, bladder and prostate]. *Hinyokika Kyo*. 2003; 49(5): 261-4.
14. Bruzzi JF, Macapinlac H, Tsimberidou AM, *et al*. Detection of Richter's transformation of chronic lymphocytic leukemia by PET/CT. *J Nucl Med*. 2006; 47(8): 1267-73.