

[DOI]10.12016/j.issn.2096-1456.2023.09.006

· 临床研究 ·

# 门型个体化唇弓治疗上颌唇向易位阻生尖牙的临床效果研究

何武成<sup>1</sup>, 何琴<sup>2,3</sup>, 鲁光炜<sup>1</sup>, 李迎兰<sup>1</sup>, 吴泽琳<sup>1</sup>, 焉姝鹤<sup>1</sup>

1. 西宁市第一人民医院口腔正畸科, 青海 西宁(810099); 2. 宁夏口腔疾病研究重点实验室, 宁夏回族自治区 银川(750004); 3. 宁夏医科大学口腔医学院口腔正畸学系, 宁夏回族自治区 银川(750004)

**【摘要】** 目的 探讨门型个体化唇弓对上颌唇向易位阻生尖牙移动的效果和该装置对易位尖牙的移动机制,为临床提供参考。方法 共收集单侧唇向上颌尖牙易位病例8例,用门型个体化唇弓进行矫治。分别于矫治前(T1)和矫治中(T2)易位尖牙牙冠移动至与同象限正常邻牙邻接但偏唇侧位置时拍摄全口曲面断层片,测量牙尖点和根尖点到中线的位移变化及长轴角度变化,进行移动机制的研究。采用牙周探针测量易位尖牙和对侧正常尖牙探诊深度和颊侧临床牙冠高度进行矫治前(T1)、矫治后(T3)牙周变化评估。结果 所有8颗易位尖牙均成功通过门型个体化唇弓移动到牙弓正常近远中位置,平均耗时(11.5±2.7)个月,总的矫治疗程(28.3±4.7)个月。T1~T2期牙尖位移8.1 mm,根尖位移1.5 mm,牙尖位移大于根尖位移( $P < 0.05$ ),尖牙长轴发生17.5°倾斜。T1、T3期牙周测量指标探诊深度和颊侧临床牙冠高度测量差异均无统计学意义( $P > 0.05$ )。结论 上颌唇向易位阻生尖牙通过门型个体化唇弓在偏唇侧位置移动是可行的和有效的,该装置对易位尖牙的位移方式是控制性倾斜移动。

**【关键词】** 易位尖牙; 上颌; 阻生; 错位; 个体化唇弓; 正畸治疗; 全口曲面断层片; 牙周袋; 临床牙冠高度

**【中图分类号】** R78 **【文献标志码】** A **【文章编号】** 2096-1456(2023)09-0647-06

**【引用著录格式】** 何武成,何琴,鲁光炜,等. 门型个体化唇弓治疗上颌唇向易位阻生尖牙的临床效果研究[J]. 口腔疾病防治, 2023, 31(9): 647-652. doi:10.12016/j.issn.2096-1456.2023.09.006.

**Clinical effect of a door shaped individualized dental archwire on the treatment of maxillary transposed canines** HE Wucheng<sup>1</sup>, HE Qin<sup>2,3</sup>, LU Guangwei<sup>1</sup>, LI Yinglan<sup>1</sup>, WU Zelin<sup>1</sup>, YAN Shuhe<sup>1</sup>. 1. Department of Orthodontics, Xining First People's Hospital, Xining 810099, China; 2. Ningxia Key Laboratory of Oral Disease Research, Ningxia Medical University, Yinchuan 750004, China; 3. Department of Orthodontics, School of Stomatology, Ningxia Medical University, Yinchuan 750004, China

Corresponding author: HE Qin, Email: 250579316@qq.com, Tel: 86-951-6743682

**【Abstract】 Objective** To discuss the effectiveness and mechanism for movement of maxillary buccally transposed canines by using a door-shaped individualized dental archwire mechanic and to provide a reference for clinicians. **Methods** Eight patients with unilateral maxillary transposed canines were enrolled. All patients were treated with door-shaped individualized archwires. Before treatment (T1) and after the crowns of the transposed canines were moved to the right buccal positions in the dental arch during the treatment (T2), orthopantomograms were taken both at T1 and T2 to compare the linear changes (distance changes of the crown and root apex) and angular changes to study the mechanisms of tooth movement. The probing depth and buccal crown height were measured using a periodontal probe to compare periodontal changes before treatment (T1) and after treatment (T3) between the transposed canines and contralateral canines. **Results** All eight transposed canines were successfully brought back to their normal dental arch position

**【收稿日期】** 2023-01-03; **【修回日期】** 2023-03-15

**【基金项目】** 宁夏回族自治区重点研发项目(2021BEB04036);西宁市科技计划项目(2020-M-39)

**【作者简介】** 何武成, 医师, 硕士研究生, Email: hwc172@163.com

**【通信作者】** 何琴, 副主任医师, 博士, Email: 250579316@qq.com, Tel: 86-951-6743652



微信公众号

but were made more buccal by using the door-shaped individualized dental archwire, with a mean of  $(11.5 \pm 2.7)$  months. The average overall duration was  $(28.3 \pm 4.7)$  months. The crown distance changes of the canines from T1 to T2 (8.1 mm) were greater than those of the root apices (1.5 mm) ( $P < 0.05$ ). The mean angulation changes of the long axes of the canines were  $17.5^\circ$ . There was no significant difference in the depth of periodontal measurement and buccal crown height measurement between T1 and T3 ( $P > 0.05$ ). **Conclusion** The buccal movement of maxillary transposed canines under a door-shaped individualized dental archwire was effective and feasible. The movement pattern under this mechanism was controlled tipping.

**【Key words】** transposed canine; maxilla; impaction; ectopic; individualized dental archwire; orthodontic treatment; panoramic radiography; pocket depth; crown height

**J Prev Treat Stomatol Dis, 2023, 31(9): 647-652.**

**【Competing interests】** The authors declare no competing interests.

This study was supported by the grants from Science and Technology department of Ningxia Hui Autonomous Region (No. 2021BEB04036); Xining Technology Bureau of Qinghai Province (No. 2020-M-39).

易位牙定义为牙弓内两个相邻牙齿位置的互换,特别是牙根位置的互换,或者是牙齿发生阶段或萌出阶段其位置被非相邻的牙齿占据<sup>[1-2]</sup>。既往文献报道上颌尖牙是牙弓内最易发生牙齿易位的牙位,其发生率为0.135%~0.510%<sup>[3-4]</sup>。根据学者Peck等<sup>[5]</sup>的分类,上颌尖牙与第一前磨牙、上颌尖牙与侧切牙是临床最常见的两种牙齿易位类型。易位牙的易位程度分为完全易位和不完全易位两种<sup>[6]</sup>,如果涉及易位的两个牙齿长轴在影像学上呈现的是一种相互平行的状态则为完全易位或称为真性易位;如果涉及的两个牙齿长轴在影像学上呈现的是交叉状态或是相互重叠的状态则称为不完全易位或称为假性易位。造成牙齿易位的病因机制尚不明确,目前普遍认为基因和环境因素都可能与病因机制有关<sup>[1-3,6]</sup>。将易位的两颗牙齿恢复正常牙弓位置顺序一直是正畸医师面临的巨大挑战,目前对于其治疗的研究国外仅见于一些个案报道,国内报道少见。本研究收集一系列上颌唇侧尖牙易位病例,所有病例均通过同一种矫治装置即门型个体化唇弓恢复了易位尖牙正常牙弓顺序,并通过全口曲面断层片上相关线距、角度和牙周指标的测量明确该矫治装置下易位阻生尖牙的移动机制及牙周变化。

## 1 资料和方法

### 1.1 病例资料

依据易位阻生尖牙的定义方法<sup>[1-2]</sup>,收集自2019年1月至2020年12月就诊于西宁市第一人民医院口腔正畸科上颌唇向易位阻生尖牙病例8例,女性7例,男性1例,平均年龄 $(14.2 \pm 1.8)$ 岁。所有

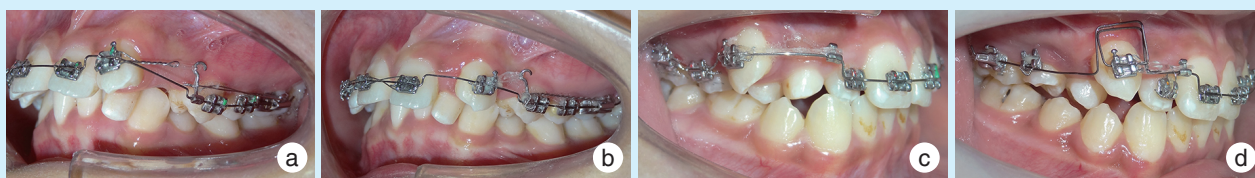
病例临床表现为上颌一侧尖牙呈萌出状态重叠错位于相邻邻牙唇侧,其中6例尖牙与侧切牙发生易位,2例尖牙与第一前磨牙发生易位。6例左侧易位,2例右侧易位。全口曲面断层片上4例易位尖牙与邻牙长轴交叉,4例易位尖牙与邻牙长轴呈现平行状态。所有患者均采用门型个体化唇弓早期进行易位尖牙向牙弓正常近远中位置的移动。该矫治方法由医院伦理道德委员会审核并批准(审批号:XNSYYLP2020015),所有患者均签署矫治前知情同意书。

### 1.2 门型个体化唇弓的制作

基于早期即能将严重唇向错位的易位尖牙纳入矫治范围,利用弓丝与托槽间的力偶距能够控制牙根移动,本研究自主设计了门型个体化唇弓矫治弓丝。每个患者依据矫治前初始牙弓形态用0.016英寸不锈钢圆丝弯制个体化唇弓,在易位尖牙处向龈方弯制门型弓,门型弓水平段与两侧牙弓形态一致并纳入易位尖牙托槽内,分别于侧切牙远中或第一前磨牙近中在水平段弓丝末端夹牵引钩与易位尖牙托槽通过弹性牵引进行易位尖牙的近中或远中移动,如图1。施加轻力,力值约30g,每月更换弹性橡皮链1次。弓丝结扎前进行口内微调,理想状态下弓丝被动进入所有上颌托槽槽沟(不包括相邻的邻牙)。

### 1.3 测量项目

分别计算安放门型个体化唇弓移动易位尖牙时间和易位尖牙纳入牙弓上颌矫治弓丝后至0.019英寸 $\times$ 0.025英寸不锈钢丝1个月后的总矫治完成时间。分别于矫治初期(T1)和矫治中(易位尖牙移动至与同象限正常邻牙邻接但偏唇侧位置



a: the door shaped individualized archwire was placed on the teeth of a 15 years old girl with 23 and 22 transposition. b: 23 was distalized using the door shaped individualized archwire with 11 months duration. c: the door shaped individualized archwire was placed on the teeth of a 12 years old boy with 13 and 14 transposition. d: 13 was mesialized using the door shaped individualized archwire with 13 months duration and a drawer loop was used to upright the canine

Figure 1 Intraoral photographs of the orthodontic treatment of two cases with transposed canines using the door shaped individualized archwire

图1 门型个体化唇弓正畸治疗移动2例异位尖牙实例图

时)(T2)拍摄全口曲面断层片,进行相关线距和角度测量(图2)。计算牙尖位移(dc)、根尖位移(dr)进行统计学分析,由于异位尖牙在与侧切牙和第一前磨牙不同异位类型下移动方向的不同,为方便统计学研究采用正值统计。尖牙与侧切牙异位类型中位移值计算公式:T2期d值-T1期d值。尖牙与第一磨牙异位类型中位移值计算公式:T1期d值-T2期d值。全口曲面断层片采用同一放大比例,线距测量值公式: $y = \frac{x}{x'}y'$  (x:模型右上中切牙宽度;x':全口曲面断层片右上中切牙宽度;y':全口曲面断层片长度测量值;y:长度校正值)进行校正。采用牙周探针进行矫治前(T1)、上颌0.019英寸×0.025英寸不锈钢丝矫治后(就位1个月后)(T3)异位尖牙和对侧正常尖牙颊侧近中、中间、远中6个点探诊深度(probing depth, PD)的测量和唇侧牙龈中点到牙尖高度即颊侧临床牙冠高度测量。所有放射片用Planmeca ProMax(Planmeca OY, Helsinki, 芬兰)曲面断层机由同一技师拍摄,拍摄时采用曲面断层机自带的垂直和水平激光线对患

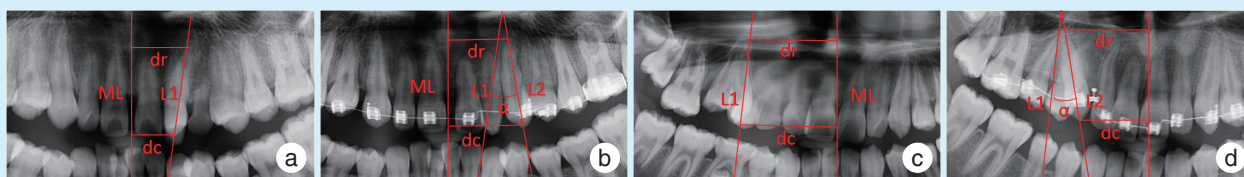
者头颅进行固定,保证治疗前后头颅处于同一姿势,其中垂直激光线对准患者面部正中线上颌左右尖牙连线水平。

#### 1.4 统计学分析

采用SPSS20.0统计软件进行数据分析,符合正态分布数据采用 $\bar{x} \pm s$ 进行描述,不符合正态分布数据采用 $M(P_{25}, P_{75})$ 进行描述,正态分布方差齐性数据采用独立样本t检验,非正态分布数据采用Mann-Whitney U检验,检验水准 $\alpha=0.05$ 。

## 2 结果

8例患者异位阻生尖牙前期均成功通过门型个体化唇弓移动到了预期位置,平均矫治时间(11.5±2.7)个月,总的矫治疗程(28.3±4.7)个月。T1、T2期异位尖牙牙尖和根尖位移变化见表1,牙尖位移8.1 mm,根尖位移1.5 mm,牙尖位移大于根尖位移,两者比较差异具有统计学意义( $P < 0.05$ )。异位尖牙长轴角度变化值为17.5°(11.7°, 24.3°)。T1、T3期异位尖牙和对照尖牙探诊深度均正常(表2)。异位尖牙唇侧临床冠高度在T1、T3



a & b: the local radiographic orthopantomogram amplifications of the 15 years old girl in the corresponding figure 1 at T1 (a) and T2 (b). c&d: the local radiographic orthopantomogram amplifications of the 12 years old boy in the corresponding figure 1 at T1 (c) and T2 (d). ML: the middle line. dc, dr: the perpendicular distance from the crown tip and root apex to the ML. L1, L2: the long axis of the canine at T1 and T2.  $\alpha$ : the angulation between L1 and L2. T1: before treatment. T2: during treatment

Figure 2 Distance changes of the crown and root apex and angulation changes of the transposed canines during orthodontic treatment measured on orthopantomograms

图2 全口曲面断层片测量正畸治疗中异位尖牙牙尖、根尖位移及长轴角度变化

表1 门型个体化唇弓移动易位尖牙牙尖、根尖位移变化  
Table 1 Distance change of the crown and root apex of the canines using the door shaped individualized archwire

Measurements	Distance change (T1-T2)	$M (P_{25}, P_{75}), \text{mm}, n=8$	
		Z	P
dc	8.1 (6.9, 11.4)	-2.4	0.016
dr	1.5 (-2.4, 6.0)		

dc, dr: the perpendicular distance from the crown tip and root apex to the middle line. T1: before treatment. T2: during the treatment

表2 门型个体化唇弓正畸治疗后上颌唇向易位阻生尖牙探诊深度测量  
Table 2 Probing depth measurement of maxillary transposed canines after orthodontic treatment using the door shaped individualized archwire

Tooth position	Location number	$\bar{x} \pm s, \text{mm}, n=8$	
		Probing depth (T1)	Probing depth (T3)
Transposed canines	48	1.6 ± 0.7	2.0 ± 0.5
Contralateral canines	48	1.8 ± 0.8	1.9 ± 0.5

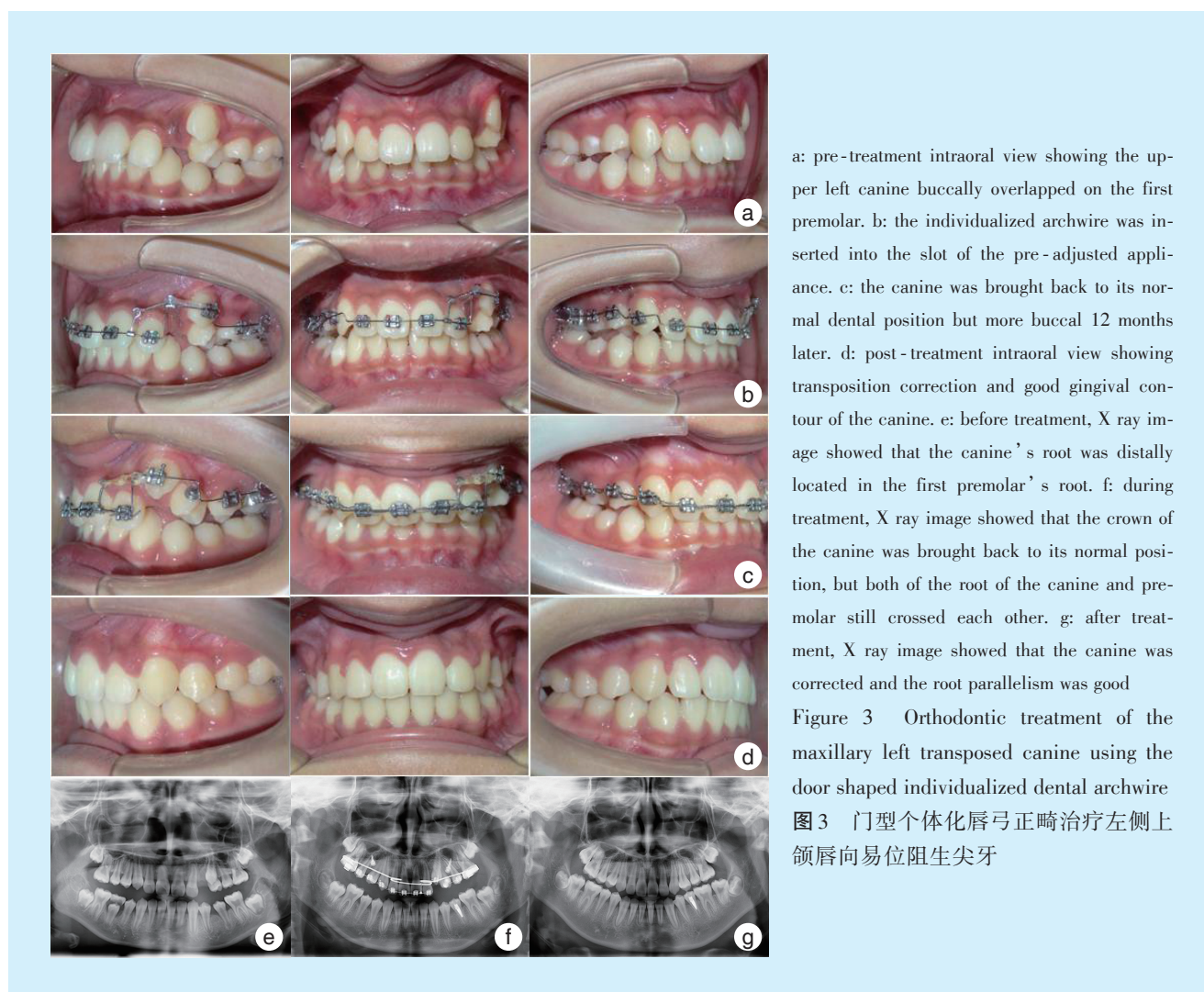
T1: before treatment. T3: after treatment

期对比无明显变化( $P > 0.05$ ), 与对侧尖牙对比差异也无统计学意义( $P > 0.05$ )(表3)。图3展示的为其中1例12岁女性患者左侧上颌尖牙与前磨牙易位, 通过门型个体化唇弓成功矫治后的口内照和全口曲面断层片对比照, 总疗程20个月。

表3 门型个体化唇弓正畸治疗前后上颌唇向易位阻生尖牙颊侧临床牙冠高度测量  
Table 3 Buccal crown height measurement of maxillary transposed canines before and after orthodontic treatment using the door shaped individualized archwire

Tooth position	Buccal crown height (T1)	Buccal crown height (T3)	$\bar{x} \pm s, \text{mm}, n=8$	
			t	P
Transposed canines	9.4 ± 0.8	9.7 ± 0.8	-2.20	0.08
Contralateral canines	10.1 ± 0.4	9.8 ± 0.5	0.98	0.37
t	1.61	0.43		
P	0.17	0.68		

T1: before treatment. T3: after treatment



a: pre-treatment intraoral view showing the upper left canine buccally overlapped on the first premolar. b: the individualized archwire was inserted into the slot of the pre-adjusted appliance. c: the canine was brought back to its normal dental position but more buccal 12 months later. d: post-treatment intraoral view showing transposition correction and good gingival contour of the canine. e: before treatment, X ray image showed that the canine's root was distally located in the first premolar's root. f: during treatment, X ray image showed that the crown of the canine was brought back to its normal position, but both of the root of the canine and premolar still crossed each other. g: after treatment, X ray image showed that the canine was corrected and the root parallelism was good  
Figure 3 Orthodontic treatment of the maxillary left transposed canine using the door shaped individualized dental archwire  
图3 门型个体化唇弓正畸治疗左侧上颌唇向易位阻生尖牙

### 3 讨论

目前大致有4种易位尖牙矫治策略:拔除相关的易位尖牙或邻牙;将易位尖牙排齐在其易位位置;通过正畸移动恢复易位尖牙正常牙弓位置;易位尖牙正常牙弓位置再植<sup>[7-12]</sup>。通过正畸恢复易位尖牙患者正常牙弓顺序治疗的难度极大,由于易位尖牙错位明显,传统固定矫治早期无法将其纳入治疗,不能进行排齐和移动;透明牙套也由于牙套无法完全包裹易位牙进而影响移动效果<sup>[13-14]</sup>。既往成功矫治的个案报道中,易位尖牙的移动多需要设计一些复杂的矫治装置,其矫治理念也大致分为两种,一种是利用腭侧腭杆等装置先进行相关邻牙的腭向移动让出尖牙在牙槽骨内移动通道<sup>[1,7,15]</sup>,当尖牙在牙槽骨内移动到正常位置后再将腭侧相关邻牙拉回牙弓内位置;另一种是利用一些特殊的矫治装置如悬梁臂、T型曲、L型曲、微螺钉等直接在偏唇侧的位置先进行尖牙的移动<sup>[16-18]</sup>,等尖牙牙冠移动至牙弓正常近远中位置后再进行正轴、排齐等的常规正畸矫治。既往对于阻生尖牙的正畸牵引过程基本上是通过矫治装置与粘接在尖牙上的舌扣进行弹力牵引,在该作用力下阻生尖牙发生的是单纯性倾斜移动,对于近中倾斜类阻生尖牙该倾斜移动是合适的<sup>[19-22]</sup>,但对于易位尖牙,牙根的反向移动会增加后期尖牙正轴的困难和时间,甚至会导致矫治的失败。在对易位尖牙局部空间的三维研究中发现,绝大多数的易位尖牙有偏唇侧的移动空间<sup>[23]</sup>。因此本研究创新采用门型个性化连续唇弓提供一个上颌易位尖牙唇侧移动轨道,代替上述特殊的矫治装置,通过门型弓与托槽间的力偶距控制牙根的同向移动,实现矫治装置简单化、加力复诊简单化和后期正轴简单化,且上颌所有牙齿可作为支抗牙不需要额外的支抗设计。所有8颗易位阻生尖牙通过门型个性化唇弓均移动到牙弓正常近远中但偏唇侧位置,平均移动时长11.5个月,总的疗程仍长达28.3个月,说明该类牙齿矫治的难度仍偏大。

大尺寸矩形个性化唇弓因弓丝和托槽间更小的间隙理论上可以进行易位阻生尖牙的整体移动,从而减少后期正轴时间和难度,但实际中大尺寸个性化唇弓弯制困难,CBCT检查也发现该类阻生尖牙唇侧骨质比较薄弱、牙齿靠近骨皮质<sup>[24-25]</sup>,骨皮质阻力大不利于尖牙的整体移动并消耗过多的支抗和有更多的唇侧骨皮质吸收风险,利用小

尺寸圆丝与托槽沟间更大的间隙允许尖牙做一定的倾斜移动可减小该类牙齿移动的难度,毕竟在所有牙齿正畸移动方式中,倾斜移动是最简单的移动方式<sup>[26-27]</sup>,而且小尺寸圆丝易弯曲成形,因此本研究采用0.016英寸不锈钢丝进行个体化唇弓的弯制,利用其有一定的刚性特质为易位尖牙唇侧的移动提供稳定的滑行轨道。通过门型个性化唇弓移动前后易位尖牙牙尖和根尖位移数据对比发现,牙尖、根尖位移平均值均为正值,但牙尖位移值明显大于根尖位移值,尖牙长轴也发生了17.5°的倾斜,说明易位尖牙的移动方式为控制性倾斜移动,相较单纯性倾斜移动而言,该类移动能明显降低易位尖牙牙冠移动到位后牙根的正轴时间和难度。易位尖牙移动前后其与对侧尖牙探诊深度及临床牙冠高度测量都未发生明显变化,说明小尺寸个性化唇弓作用下的易位尖牙控制性倾斜移动及轻力加载方式未对易位尖牙唇侧移动过程中的牙周造成损伤,进一步说明个性化唇弓偏唇侧移动易位阻生尖牙是可行的、安全的。但由于易位尖牙较低的发病率,本研究只收集到8例病例,今后仍需扩大样本量对上述结论进行更加客观的研究。

**【Author contributions】** He WC designed the study, processed the research, collected data and wrote the article. Lu GW, Li YL, Wu ZL, Yan SH assisted in the research process. He Q revised the article. All authors read and approved the final manuscript as submitted.

### 参考文献

- [1] Pedalino A, Matias M, Gaziri D, et al. Treatment of maxillary canine transposition[J]. *Angle Orthod*, 2020, 90(6): 873-880. doi: 10.2319/121719-808.1.
- [2] Nyakale MD. Orthodontic treatment of bilateral transposition of maxillary canines and lateral incisors[J]. *Case Rep Dent*, 2022, 2022: 8094008. doi: 10.1155/2022/8094008.
- [3] Finkelstein T, Shapira Y, Pavlidi AM, et al. Canine transposition - prevalence, distribution and treatment considerations among orthodontic patients[J]. *J Clin Pediatr Dent*, 2020, 44(4): 268-273. doi: 10.17796/1053-4625-44.4.9.
- [4] Jain S, Debbarma S. Patterns and prevalence of canine anomalies in orthodontic patients[J]. *Med Pharm Rep*, 2019, 92(1): 72-78. doi: 10.15386/cjmed-907.
- [5] Peck S, Peck L. Classification of maxillary tooth transpositions[J]. *Am J Orthod Dentofac Orthop*, 1995, 107(5): 505-517. doi: 10.1016/S0889-5406(95)70118-4.
- [6] Tseng YC, Chang HP, Chou TM. Canine transposition[J]. *Kaohsiung J Med Sci*, 2005, 21(10): 441-447. doi: 10.1016/s1607-551x(09)70148-2.
- [7] Lorente C, Lorente P, Perez-Vela M, et al. Orthodontic manage-

- ment of a complete and an incomplete maxillary canine-first premolar transposition[J]. *Angle Orthod*, 2020, 90(3): 457-466. doi: 10.2319/080218-561.1.
- [8] Maia FA. Orthodontic correction of a transposed maxillary canine and lateral incisor[J]. *Angle Orthod*, 2000, 70(4): 339-348. doi: 10.1043/0003-3219(2000)070<0339:OCOATM>2.0.CO;2.
- [9] Mereani S, Alotaibi A, Bokhari A. Orthodontic management of a rare incidence bilateral maxillary canine-first premolar transposition using fixed appliance[J]. *Case Rep Dent*, 2022: 9973333. doi: 10.1155/2022/9973333.
- [10] Martins IP, Martins RP, Guimarães G, et al. Concomitant permanent maxillary canine agenesis and transposition treated with extractions and lingual brackets[J]. *Am J Orthod Dentofac Orthop*, 2020, 157(4): 550-560. doi: 10.1016/j.ajodo.2018.12.026.
- [11] Matsumoto MAN, Stuaní MBS. Tooth transposition: a multidisciplinary approach[J]. *Dental Press J Orthod*, 2018, 23(1): 97-107. doi: 10.1590/2177-6709.23.1.097-107.bbo.
- [12] Curtis JMT, Foster E, Ananth S, et al. Autotransplantation of a surgically removed canine using a customised 3D-printed surgical template[J]. *J Orthod*, 2020, 47: 82-90. doi: 10.1177/1465312519891738.
- [13] Ke Y, Zhu Y, Zhu M. A comparison of treatment effectiveness between clear aligner and fixed appliance therapies[J]. *BMC Oral Health*, 2019, 19(1): 24. doi: 10.1186/s12903-018-0695-z.
- [14] Papageorgiou SN, Koletsi D, Iliadi A, et al. Treatment outcome with orthodontic aligners and fixed appliances: a systematic review with meta-analyses[J]. *Eur J Orthod*, 2020, 42(3): 331-343. doi: 10.1093/ejo/cjz094.
- [15] Pithon MM. Therapeutic approach in class I malocclusion with impacted maxillary canines[J]. *Dental Press J Orthod*, 2022, 27(2): e22bbo2. doi: 10.1590/2177-6709.27.2.e22bbo2.
- [16] Bilinska M, Kristensen KD, Dalstra M. Cantilevers: multi-tool in orthodontic treatment[J]. *Dent J (Basel)*, 2022, 10(7): 135. doi: 10.3390/dj10070135.
- [17] Ferreira JB, Santos Silveira G, Mucha JN. A simple approach to correct ectopic eruption of maxillary canines[J]. *Am J Orthod Dentofac Orthop*, 2019, 155(6): 871-880. doi: 10.1016/j.ajodo.2017.11.046.
- [18] Lee MY, Park JH, Jung JG, et al. Forced eruption of a palatally impacted and transposed canine with a temporary skeletal anchorage device[J]. *Am J Orthod Dentofac Orthop*, 2017, 151(6): 1148-1158. doi: 10.1016/j.ajodo.2016.06.051.
- [19] Grisar K, Luyten J, Preda F, et al. Interventions for impacted maxillary canines: a systematic review of the relationship between initial canine position and treatment outcome[J]. *Orthod Craniofac Res*, 2021, 24(2): 180-193. doi: 10.1111/ocr.12423.
- [20] Grisar K, Fransen J, Smeets M, et al. Surgically assisted orthodontic alignment of impacted maxillary canines: a retrospective analysis of functional and esthetic outcomes and risk factors for failure [J]. *Am J Orthod Dentofac Orthop*, 2021, 159(6): e461-e471. doi: 10.1016/j.ajodo.2020.12.019.
- [21] Yang JS, Cha JY, Lee JY, et al. Radiographical characteristics and traction duration of impacted maxillary canine requiring surgical exposure and orthodontic traction: a cross-sectional study[J]. *Sci Rep*, 2022, 12(1): 19183. doi: 10.1038/s41598-022-23232-7.
- [22] Arriola-Guillén LE, Aliaga-Del Castillo A, Ruíz-Mora GA, et al. Influence of maxillary canine impaction characteristics and factors associated with orthodontic treatment on the duration of active orthodontic traction[J]. *Am J Orthod Dentofac Orthop*, 2019, 156(3): 391-400. doi: 10.1016/j.ajodo.2018.10.018.
- [23] Chi J, Du W, Sun H, et al. The relationship between local alveolar bone housing and size of canine in maxillary canine-lateral incisor transposition: a retrospective cone-beam computed tomography-based study[J]. *Am J Orthod Dentofac Orthop*, 2022, 162(3): 331-339. doi: 10.1016/j.ajodo.2021.03.026.
- [24] Arboleda-Ariza N, Schilling J, Arriola-Guillén LE, et al. Maxillary transverse dimensions in subjects with and without impacted canines: a comparative cone-beam computed tomography study[J]. *Am J Orthod Dentofac Orthop*, 2018, 154(4): 495-503. doi: 10.1016/j.ajodo.2017.12.017.
- [25] Sharhan HM, Almashraqi AA, Al-Fakeh H, et al. Qualitative and quantitative three-dimensional evaluation of maxillary basal and dentoalveolar dimensions in patients with and without maxillary impacted canines[J]. *Prog Orthod*, 2022, 23(1): 38. doi: 10.1186/s40510-022-00434-3.
- [26] Lombardo L, Arreghini A, Ramina F, et al. Predictability of orthodontic movement with orthodontic aligners: a retrospective study [J]. *Prog Orthod*, 2017, 18(1): 35. doi: 10.1186/s40510-017-0190-0.
- [27] Bilello G, Fazio M, Amato E, et al. Accuracy evaluation of orthodontic movements with aligners: a prospective observational study [J]. *Prog Orthod*, 2022, 23(1): 12. doi: 10.1186/s40510-022-00406-7.

(编辑 张琳,何武林)



官网