

Transverse Sacral Fracture-Dislocation with Anterior Displacement: A Case Report

SK Tiew, MD, Terence Tay, MRCS (Edin)

Department of Orthopaedics, Hospital Tengku Ampuan Rahimah, Klang, Malaysia

ABSTRACT

Transverse sacral fracture is a very rare injury and frequently missed or delayed in diagnosis. We present a case with this injury and discuss its management.

Key Words:

Transverse, sacral fracture- dislocation, displacement

INTRODUCTION

Sacral fractures are uncommon injuries. Most are longitudinal fractures, only 3% to 5% are transverse fractures. Transverse fractures are usually observed following a fall from height, thus it is also named "suicide jumper's fracture"¹. A combination of flexion and shearing force is responsible for this fracture, and the forces propagated through the weakest point of sacrum, the foramina. Neurological deficit involving sacral roots are common and have been reported at rates of 96% to 100% in the literature.

CASE REPORT

We present the case of a 14-year-old teenager who was thrown under a lorry following a road traffic accident, and the rear tyre rolled over his lower back. On admission, the patient was conscious and haemodynamically stable. He complained of low back and right hip pain. On examination, he had mild tenderness at right lower quadrant of abdomen. Tyre tread marks were seen on his buttock. There was also bladder incontinence and saddle anaesthesia. Muscle strength of both lower limbs was full.

Radiographs and computed tomography (CT) scans showed right iliopsoas muscle and retroperitoneal haematoma and fracture-dislocation of S1 over S2 (Figure 1) with fracture of bilateral S1 and S2 alae. CT 3D reconstruction revealed an associated fracture of spinous processes from L1 to L5 and bilateral sacroiliac joint diastases. Magnetic resonance imaging (MRI) was performed to assess neurological damage. Indeed, results showed fracture-dislocation of S1/S2 level with spinal canal stenosis and compression of

traversing nerve roots at this level (Figure 2). Surgical intervention was undertaken on day 5 post-trauma.

A dorsal midline approach was used with the patient in prone position. No laminectomy attempt was made. The fracture-dislocation was reduced and stabilized by inserting pedicle screws at both L5 and S1, and one lower pedicle screw inserted inferior to posterior iliac spine, aimed towards the acetabular dome (Figure 3). Fusion was accomplished using an autogenous bone graft harvested from the posterior superior iliac spine, mixed with Chronos Block (Synthes).

Postoperative recovery and rehabilitation were good. The patient was able to ambulate with a walking frame 6 days after the operation and was discharged with intermittent urine catheterization. At one-month follow-up, the patient was ambulating well and his urinary incontinence had improved tremendously. Radiological study on subsequent follow-up showed solid union of the fusion site. However, the implant was removed one and a half years later due to implant irritation (prominence of iliac screw).

DISCUSSION

Transverse sacral fractures are rare and constitute less than 1% of all spinal fractures. Whilst the majority are longitudinal fractures, only 3% to 5% are transverse fractures². As a result of low incidence and the radiological difficulties in visualizing the fracture, accurate diagnosis is often delayed or unrecognized. In the report of Denis and associates², regarding patients with neurological deficit, 49% of fractures were not noted on the chart. In patients without neurological deficit, only 5% were diagnosed on initial hospitalization. In another series by Roy-Camille and colleagues, 54% of patients had the diagnosis delayed by one to 18 months¹.

Conventional radiographs are often inadequate for clear visualization of the fracture as two iliac bones cover the sacrum. In patients with a history of high-energy trauma and clinical signs suggestive of lumbosacral injury, additional radiographs, such as lateral sacral, pelvic inlet and outlet, and Ferguson's view may improve the visualization of a

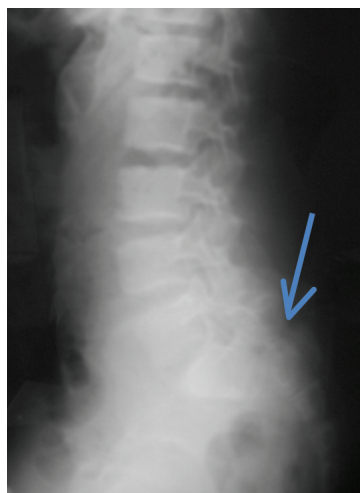

Fig. 1: Plain radiography showing dislocation of S1 and S2 (blue arrow), which could easily be missed.

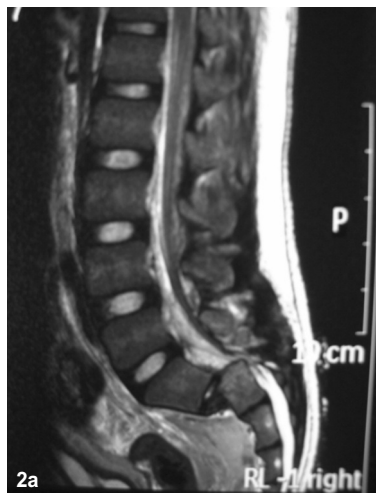

Fig. 2: (a) T2-weighted MRI sagittal view showed dislocation of S1/S2 compressing the nerve roots; Figure 2(b) T2-weighted MRI axial view showing compression of traversing nerve roots.

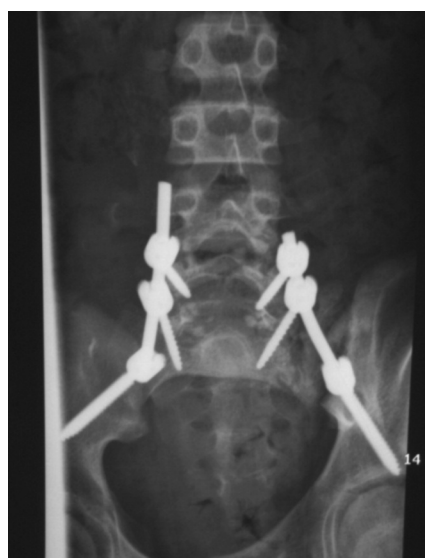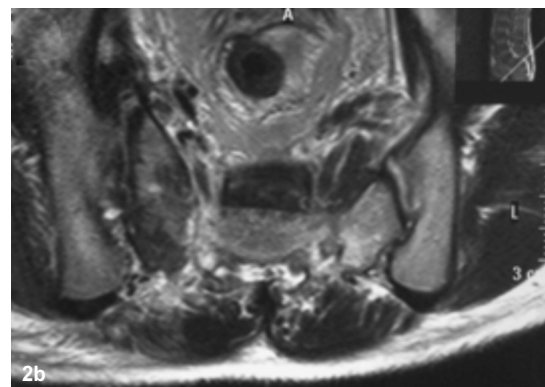


Fig. 3a: Plain radiograph showed lumbopelvic fixation (Pedicle screws inserted at both L5 and S1, and one lower pedicle screw inserted inferior to posterior iliac spine, aimed towards the acetabular dome).

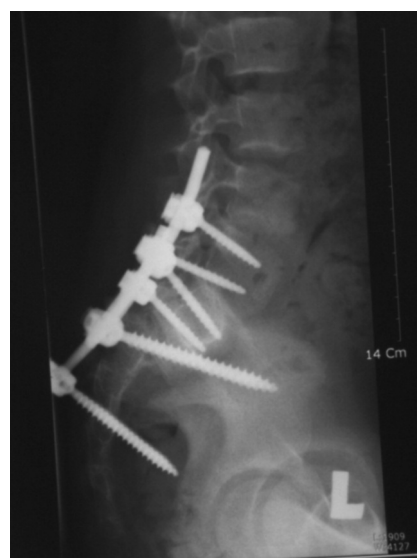

Fig. 3b: Radiograph showed limited reduction of S1/S2 dislocation stabilised by lumbopelvic fixation.

sacrum fracture. CT scans with 3D reconstruction are very useful to demonstrate the full extent of this injury. The role of MRI is to determine spinal cord or nerve root injuries when neurological deficit is present. In this case, the presence of bladder incontinence and saddle anaesthesia alerted us to a possible lumbosacral injury, and CT scan was performed to confirm the diagnosis.

Denis *et al* proposed a classification system based on anatomic location of fractures as follows: zone I involves the alar region; zone II fracture occurs at the sacral foraminal area; and zone III involves the central canal. Transverse fractures are considered zone III injuries, as there is

involvement of the spinal canal². Roy-Camille further classified transverse sacral fracture into three types¹, and a new type of fracture was added later to this classification paradigm by Strange-Vognsen: type I injury is angulated but not translated; type II is angulated and translated; type III shows complete translational displacement of the cephalad and caudal parts of the sacrum; and type IV is segmentally comminuted as a result of axial compression. By definition, this case represents a type III Roy-Camille fracture.

Neurological disturbances are quite common in transverse sacral fractures. Denis *et al*. report neurological deficit in 56% of zone III injuries². In some larger series of transverse

sacral fracture, 96% to 100% of patients had some neurological deficit^{1,3}, mainly in the form of bowel and bladder dysfunction and saddle anaesthesia, similar to what we found in this patient.

Management of these injuries remains controversial. Various treatments have been reported in the literature. These include conservative management, initial conservative treatment followed by surgical treatment after failure of conservative treatment, and primary surgical treatment. Conservative treatment includes bed rest with or without traction for 3 to 8 weeks. The proponents of conservative treatment stated that spinal nerves have the ability to progressively restore function although the recovery may be incomplete⁴. The drawbacks of non-operative treatment are residual pelvic discomfort, low back pain and neurological deficit. A trial of closed reduction may be attempted using heavy two-pole traction to improve sagittal alignment of the lumbosacral junction. However, due to the unstable nature of this injury, loss of reduction may occur over time and necessitate surgery.

Surgical treatment is indicated for significant displacement, neurological deficit, instability or deterioration after non-operative treatment. Options include decompression with laminectomy, laminectomy and stabilization, or stabilization alone. Various methods of stabilization have been reported, including Harrington, Luque, plating, lumbosacral pedicle screws extending to S2, percutaneous sacroiliac screws, and lumbopelvic constructs.

Due to the rarity of the injury, we reviewed the literature before embarking on treatment decision. In this patient, S1/S2 fracture-dislocation with diastases of bilateral sacroiliac joint was the cause of the separation of upper sacral fragments from pelvic and lower sacral segments,

giving rise to a condition called “spino-pelvic dissociation”. The literature suggests that lumbopelvic fixation is best indicated for spino-pelvic dissociation as it mimics the normal load transfer by unloading the sacral fracture. To our knowledge, Schildhauer *et al*⁵ reported on the largest series of patients treated successfully using lumbopelvic fixation. They used two pairs of pedicle screws for fixation of the lumbosacral spine, and two points of iliac fixation bilaterally with either iliac screw alone or in combination with iliosacral screws. In his results, sacral fractures healed in all 18 patients without loss of reduction. Average kyphosis improved more than 50%, and 83% of patients had full or partial recovery of bowel and bladder deficits.

Based on the above reasons, we advocated similar surgical method for our patient. Laminectomy was not performed as the neurological deficit was caused by compression at the dislocation site. Intraoperatively, we intended to insert two pairs of iliac screws, but we only managed to insert 1 pair due to technical difficulty. Although the reduction was limited, neurological recovery was good at follow-up.

The patient later underwent removal of the implant as a result of prominence of iliac screw. Schildhauer *et al*⁵ had also reported this as a hardware complications. Other complications reported were wound-related problems such as infection, hematoma or seroma formation, which were not seen in this patient.

In conclusion, a transverse sacral fracture is an uncommon but severe injury. It is frequently missed and unrecognized, the upper sacrum is usually involved and most patients present with neurological deficit. Operative treatment is often recommended for significant displacement, neurological deficit or deterioration in condition after non-operative treatment.

REFERENCES

1. Roy Camille R, Saillant G, Gagna G, Mazel C. Transverse fracture of the upper sacrum. Suicidal jumper's fracture. *Spine*. 1985; 10: 838-45.
2. Denis F, Davis S, Comfort T. Sacral fractures: an important problem. Retrospective analysis of 236 cases. *Clin Orthop*. 1988; 227: 67-81.
3. Sabiston CP, Wing PC. Sacral fractures: Classification and neurologic implications. *J Trauma*. 1986; 26: 1113-5.
4. Phelan ST, Jones DA, Bishay M. Conservative management of transverse fractures of the sacrum with neurological features. A report of four cases. *J Bone Joint Surg Br*. 1991; 73(6): 969-71.
5. Schildhauer TA, Bellabarba C, Nork SE, Barei DP, Chip Routt ML, Chapman JR. Decompression and lumbopelvic fixation for sacral fracture-dislocation with spino-pelvic dissociation. *J Orthop Trauma*. 2006; 20: 447-57.