

Fibula Osteocutaneous Flap for Mandible Reconstruction after Ameloblastoma Resection: Amending Technique to Reduce Ischaemic Time

EK Chee, MD, T Sara Ahmad, FRCS, ES Ng, MS (Ortho)

*Department of Orthopaedic Surgery, University Malaya Medical Centre, 50603 Kuala Lumpur, Malaysia

ABSTRACT

A 27-year-old patient with ameloblastoma of the mandible underwent anterior mandibulectomy and reconstruction with left fibula osteocutaneous flap. The bone was shaped at the lower limb before cutting the pedicle. Vascularised free fibula flap provides a good alternative to other bone grafts in mandible reconstruction as it is relatively easy to perform, carries a low complication rate, and mandibular shaping with intact pedicle cuts down on ischaemic as well as total operative time.

Key Words:

Fibula osteocutaneous flap, Ameloblastoma, Mandible

INTRODUCTION

Ameloblastoma, the most common odontogenic tumour, is locally invasive with a high rate of recurrence if not adequately removed. In the mandible, ameloblastoma can grow to great size and cause facial asymmetry, displacement of teeth, loose teeth, malocclusion and pathological fracture. Treatment by wide excision is curative in up to 95% of cases. Chana *et al.*¹ proposed a 1 to 2 cm normal margin, and the large defect left after resection warrants reconstruction preferably with the fibula osteocutaneous flap.

Vascularised fibula graft was first described by Taylor in 1975². Later Chen and Yen incorporated an overlying skin paddle for composite reconstruction of the bone and soft tissue defect³. After demonstrating that osteotomies can be performed in vascularised fibula grafts without compromising the viability of the bone segment, vascularised free fibula flap became the state of art reconstruction method after mandible ablation. The free fibula flap provides the greatest bone length, is suitable to accept dental implants and allows incorporation of a skin island for mouth floor or lip reconstruction. Donor site morbidity is low and its location facilitates the 2 team approach.

CASE REPORT

Mr. T, a 27-year-old gentleman, developed right mandible swelling in the year 2000 which was diagnosed with ameloblastoma of the right side of the mandible. Right hemimandibulectomy with iliac bone graft and plating was performed in 2001. In 2003 he developed osteomyelitis of the reconstructed mandible and wound debridement, sequestrectomy and sinus track excision was performed. The patient was then well until 2006 when he again developed swelling over the same site, at which time he was diagnosed with recurrent ameloblastoma [Fig. 1]. An anterior segmental mandibulectomy and reconstruction with left fibula osteocutaneous flap was planned. A pre-operative CT angiogram was performed to evaluate the peroneal circulation. Segmental mandibulectomy was performed by the maxillofacial team and the fibula osteocutaneous flap was accomplished simultaneously by the hand and microsurgery team. Intraoperatively a tourniquet was applied and the standard lateral approach previously described by Gilbert was used. The skin paddle was planned and centred over the pre-planned intraoral mucosal deficit. The anterior margin was raised and the posterolateral intermuscular septum was exposed to identify the septocutaneous branch. We were able to obtain two septal perforators to the skin pedicle. The fibula was exposed and a 14 cm segment was cut with oscillating saw. The distal cut was 6 cm from the ankle joint so as not to compromise joint stability. The vascular pedicle was carefully dissected. Four osteotomies were performed with the pedicle still attached. Care was taken to protect the periosteal branch of the peroneal artery and the septocutaneous branch by raising the periosteal tunnel before performing an osteotomy as described by Jones *et al.*⁵. Shaping of the resected fibula was done according to the preoperative template. A titanium miniplate with locking screws was used to secure the osteotomized fibula and the mandible [Fig. 2]. This was carried out at the leg itself, with the pedicle intact. When the recipient site and vessels were ready, the pedicle was cut and the newly formed "mandible" was transferred and revascularised after selecting the suitable position. The graft

pedicle was anastomosed to the superior thyroid artery and two tributaries of external jugular vein. Circulation was verified by periosteal bleeding, bleeding from the skin edge and skin capillary return. A meshed split skin graft was used to cover the donor area defect. Post operatively, the patient was maintained on Dextran 40 and aspirin. On day 9, a bone scan was performed to ensure uptake of the fibula graft [Fig. 3]. The patient was discharged with partial weight bearing for 6 weeks.

DISCUSSION

Historically, multicystic or solid ameloblastoma are treated with curettage and enucleation. However, curettage is associated with a high recurrence rate thus wide excision has become the standard practice. Normally if the tumour is small (< 5cm) the defect can be repaired with a free bone graft⁴. However, the tumour is often larger and a large defect reconstruction is challenging and may require a microsurgical flap either from fibula, iliac crest, scapula, radius or ribs. This is necessary to achieve adequate function, cosmesis and for restoration of mastication and speech, so as to enhanced the quality of life. In addition to the bone defect, the mucosal defect needs to be addressed. Since this patient has a large bony defect, a free fibula osteoseptocutaneous flap was chosen to address both the bony and soft tissue defect. This flap is easily accessible along with reliable vascular pedicle and it is possible to harvest the flap while tumour resection is being carried out. Furthermore, a vascularised bone graft enables the insertion of an osteo-integrated implant which facilitates full functional oral rehabilitation¹.

Routine preoperative angiography of the donor leg was performed before fibula resection in order to assess peroneal vascular anatomy, however it should be noted that some surgeons claim that this procedure is not justified as it does

not add relevant new information about donor leg vascularity (provided that proper clinical evaluation of the pedal pulses is conducted).

We performed the mandibular shaping and osteotomy in situ while the pedicle was still attached. Some surgeons divide the graft first since the warm ischaemic time of 4 hours may be adequate to perform both osteotomies and fixations and complete the anastomosis. We aimed for minimal ischaemic time so as to enhance the survival rate. Furthermore, working simultaneously reduces the total operation time.

We feel that the technique of shaping the graft in situ has definitive advantages. However there are recognized disadvantages of using the fibula as its height is limited, possibly making it difficult to re-establish normal alveolar ridge height. It appears that preoperative CT scan is not helpful in locating peroneal blood vessels, and locating the

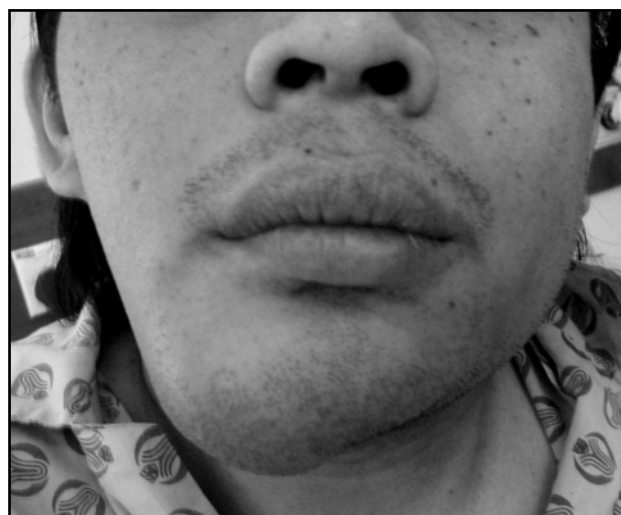


Fig. 1: Preoperative picture showing right mandible growth.



Fig. 2: Fibula was osteotomised and reconstructed to resemble mandible shape and fixed to reconstruction plate with intact pedicle.

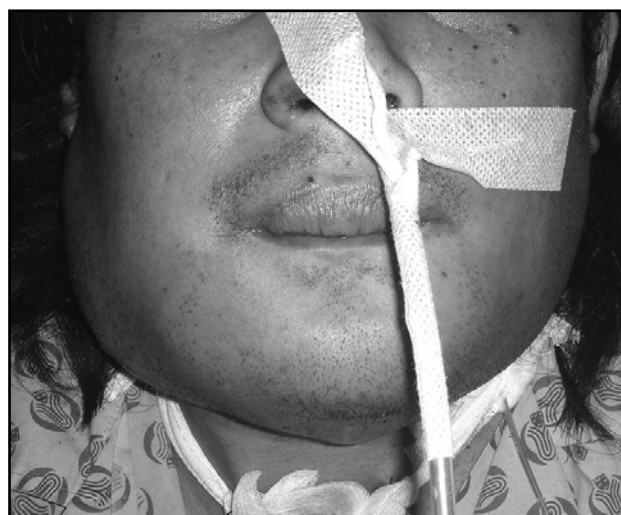

Fig. 3: Post operative picture after tumour resection and reconstruction with fibula osteocutaneous flap.

Fibula Osteocutaneous Flap for Mandible Reconstruction after Ameloblastoma Resection

septal branch can be challenging. Proper preoperative planning and calculation is needed to ensure adequate fibula length without compromising ankle stability as well as a properly seated skin flap for mouth floor reconstruction. Care must also be taken so as not to excise an unnecessarily large skin island that could potentially leave an unsightly donor defect.

CONCLUSION

The vascularised free fibula graft provides a The vascularised free fibula graft provides a good alternative to other bone grafts for mandible reconstruction. It is relatively easy to perform and carries a low complication rate. In addition, mandibular shaping in situ with intact pedicle cuts down on ischaemic as well as total operative time.

REFERENCES

1. Chana JS, Chang YM, Wei FC, *et al.* Segmental mandibulectomy and immediate free fibula osteoseptocutaneous flap reconstruction with endosteal implants: an ideal treatment method for mandibular ameloblastoma. *Plast Reconstr Surg* 2004; 113: 80-7.
2. Taylor GI, Miller GD, Ham FJ. The free vascularized bone graft: A clinical extension of microvascular techniques. *Plast Reconstr Surg* 1975; 55(5): 533-44.
3. Chen ZW, Yan W. The study and clinical application of the osteocutaneous flap of fibula. *Microsurgery* 1983; 4(1): 11-6.
4. Gerzenshtein J, Zhang F, Caplan J, Anand V, Lineaweaver W. Immediate mandibular reconstruction with microsurgical fibula flap transfer following wide resection for ameloblastoma. *J Craniofac Surg* 2006; 17(1): 178-82.
5. Jones NF, Monstrey S, Gambier BA. Reliability of the fibular osteocutaneous flap for mandibular reconstruction: anatomical and surgical confirmation. *Plast Reconstr Surg* 1996; 97(4): 707-16.