

Case Report

Fournier's Gangrene: A Case of Neglected Symptoms with Devastating Physical Loss

Praveen SINGAM¹, Khor Tze WEI², Ammar RUFFEY², James LEE²,
Teh Guan CHOU²

Submitted: 18 Dec 2011

Accepted: 11 Feb 2012

¹ Department of Urology, UKM Medical Center, 56000 Cheras,
Kuala Lumpur, Malaysia

² Department of Urology, Sarawak General Hospital, 93586 Kuching,
Sarawak, Malaysia

Abstract

Fournier's gangrene is a severe life-threatening infection involving the perianal area, perineum, and external genitalia. It demands prompt recognition, critical care therapy, surgical therapy, and a combination of antibiotics. The infection commonly spreads via the fascial planes and causes superficial vascular thrombosis within the Colles' fascia around the external genitalia. It can extend cephalad to involve the Scarpa's fascia and Camper's fascia in the abdominal wall. The treatment would include multiple debridements, which would result in disfiguring scars of the perineum and might lead to significant physical and psychological complications. We describe a case of a 58-years-old man presenting with Fournier's gangrene resulting from an infection of an impacted urethral stone. The patient previously had obstructive voiding symptoms for 1 month but chose to neglect them. The resultant infection was severe and caused penile and right testicular gangrene. He underwent multiple wound debridements, which included a total penectomy and right orchiectomy. Psychological and rehabilitative support was necessary for him to overcome his loss and disfigurement.

Keywords: gangrene, genitalia, orchidectomy, perineum, psychology

Introduction

Fournier's gangrene is a severe and life-threatening infection of the perineum and perianal region. Despite established management protocols, the mortality and morbidity range from 10%–20% and up to 60%, respectively. Patients who do survive the ordeal are frequently left with a disfiguring wound, a sense of altered body image, psychological trauma, and prolonged rehabilitation to normality. Here, we describe such a case in which delayed presentation of the disease resulted in devastating disfigurement and morbidity.

Case Report

A 58-years-old man had a one-month history of obstructive voiding symptoms. He worked as a security guard and was from a low socio-economic income group. He had not sought proper medical help but instead tried traditional remedies to overcome his symptoms. He then presented to the emergency department with acute urinary retention associated with 3 days of penile and scrotal swelling. He had no

fever, hematuria, or previous instrumentation of the urinary tract. A physical examination demonstrated that he was tachycardic (120 beats/min) and hypotensive (80/60 mmHg). There was discoloration and swelling of his external genitalia with an associated priapism (Figure 1a). A diagnosis of Fournier's gangrene was made. He had severe metabolic acidosis and a random blood sugar level of 8.4 mmol/L. Following fluid resuscitation, he was treated with broad-spectrum antibiotics and inotropic support, and an immediate wound debridement was performed.

Intra-operatively, the skin overlying the external genital was gangrenous and removed. The corpus cavernosum was engorged with deoxygenated blood and the corpus spongiosum had extensive necrosis (Figure 1b). The superficial and deep dorsal penile veins were thrombosed. An impacted urethral stone was observed and removed from the membranous urethra (Figure 1c). It was unclear whether the corporal bodies of the penis and both testes were viable. They were therefore not removed to preserve the genital anatomy. A suprapubic catheter was

inserted to drain the bladder.

The patient post-operatively developed pneumonia. He then developed gangrene of the digits of both the lower and upper limbs, which resulted from a 20 mg/min noradrenaline infusion. Within 3 days, the right testis and the corporal bodies of the penis became gangrenous (Figure 1d). He underwent a total penectomy, right orchiectomy, and further wound debridement. Upon discharge, the wound had contracted with healthy granulation at its base. However, the patient was distraught due to the loss of the penis and right testis. The patient and his family received psychological counselling and are still under active observation and follow up.

Discussion

Fournier's gangrene is a devastating disease with an estimated mortality of 10%–20%, depending on the severity of presentation (1). It was initially described by Jean Alfred Fournier in 1883. He described 3 features of this disease, which include the abrupt onset of scrotal pain

and swelling in a healthy adult, rapid progression to gangrene, and the absence of a definitive cause (2). It is now no longer considered idiopathic, as its etiology is usually a pathological process from the overlying skin, urinary tract, or colorectal area (1). The disease usually involves the scrotum (30%), perineum (50%), or anterior abdominal wall (20%). Predisposing factors, such as systemic immunosuppression, diabetes mellitus, chronic alcoholism, and steroid therapy favour its rapid progression (3).

Fournier's gangrene represents a polymicrobial infection. Both aerobic and anaerobic organisms are usually present. *Enterobacteriaceae*, *bacteroides* and *streptococcus* species are the most commonly isolated. The infection begins in an area adjacent to the site of bacterial entry and progresses as a spreading inflammatory reaction that involves the superficial and deep-tissue planes. As it progress, the infection causes endarteritis, leading to cutaneous and subcutaneous vessel thrombosis and tissue necrosis due to the synergistic actions of the

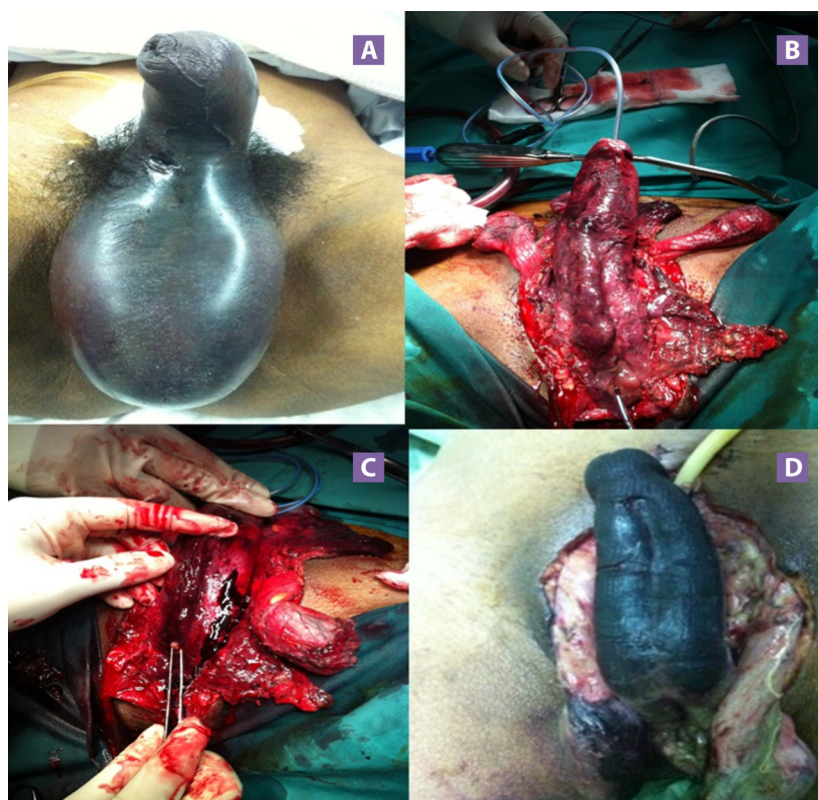


Figure 1: (A) Gangrene and swelling of the external genitalia. (B) Gangrenous corpus spongiosum and perineal necrosis. (C) A stone removed from the membranous urethra. (D) Penile and right testicular gangrene.

aerobic and anaerobic organisms; which produce various proteins and enzymes that lead to intravascular clotting. The microorganisms produce various endotoxins and exotoxins that cause prolonged vasoconstriction and a thrombotic occlusion of the blood vessels. These toxins are also released into the systemic circulation and resulting in systemic inflammatory response syndrome (SIRS) and septic shock. Certain bacteria, including *streptococci* and *staphylococci*, produce hyaluronidase, streptokinase, and streptodornas, which directly destroy connective tissue. Hydrogen and nitrogen gasses are produced by the anaerobes, resulting in crepitus (4). As such, potential antibiotic therapies include a metronidazole combination for anaerobic microorganisms and broad-spectrum third- or fourth-generation cephalosporins and an aminoglycoside, such as gentamicin, for gram-positive and gram-negative microorganisms, respectively.

Urogenital causes of Fournier's gangrene include urethral strictures, indwelling catheters, traumatic catheterisation, urethral calculi, and prostate biopsies. Stricture and calculi may produce minimal symptoms, and therefore go unrecognised unless the appropriate investigations are undertaken, such as urinary tract imaging and cystoscopy. Infected urine proximal to the obstruction enters the periurethral glands. The invading organisms then spread within the corpus spongiosum before penetrating the tunica albuginea to reach Buck's fascia. Infections then travel posteriorly along the dartos fascia to enter Colles' fascia (3,4). Colles' fascia is posteriorly attached to the perineal body, and therefore, infections arising from the urogenital structures do not reach the anal margin. By contrast, an infection with an anorectal focus penetrates the anal sphincter muscles to reach Colles' fascia before involving the scrotum. This difference helps to identify the likely origin of infection because the perianal involvement of Fournier's gangrene indicates an anorectal source of infection (4).

The corporal bodies and testes are rarely affected because they have independent blood supplies that originate intra-abdominally. However, severe infections may penetrate the urogenital diaphragm and the perivesicle space and gain entry into the inguinal canal via the internal and external fascia of the spermatic cord (4), which occurred in this patient's right side, causing testicular gangrene. An ischemic priapism was present and is believed to have

resulted from a venous thrombosis of the superficial and deep dorsal veins.

Prompt recognition and treatment may limit the spread and metabolic consequences of a gangrenous infection. However, our patient, as in previously reported studies, showed a consistent delay of 1–7 days (mean of 2.5 days) between disease onset and the first debridement.

A total penectomy is rarely necessary, but an orchiectomy is reportedly performed in 21% of cases (1). Post-debridement, most patients have a flap or skin graft cover the tissue loss on the penis. The scrotal skin heals well and is usually left to regenerate itself (1,2). Our patient had both of the above-mentioned procedures performed, which gave him a sense of physical loss and altered body image. Psychological counselling was obtained for the patient and the family. Further rehabilitation was necessary to hasten his recovery process and allow him to return to work.

This case illustrates the severity and fast spread of necrotising fasciitis of the perineal region resulting from a neglected treatable condition. It is likely that low economic status, cultural beliefs, and a fear of modern medicine kept this patient away from early definitive treatment. Immediate recognition, prompt resuscitation, and extensive debridement with broad-spectrum antibiotic coverage are necessary to limit the spread and severity of a gangrenous infection. Nonetheless, the physical and psychological damage is sometimes already present. Major lifestyle adjustments may be needed and could include role reversal of the family breadwinner, a change in occupation and financial uncertainties. Thus, it is important that early psychological counselling, aggressive rehabilitation, and social support are obtained. These added supportive measures will allow the patient and family members to come to terms with their loss and keep them focused on their future aspirations and goals.

Conclusion

Fournier's gangrene is a surgical emergency which demands prompt recognition and aggressive treatment. A delay in diagnosis would result in devastating outcomes. The etiology is often found through proper investigations and not idiopathic as previously believed. Definitive management still includes multiple surgical debridement which saves lives but leaves traumatic scars on a patient.

Authors' Contributions

Conception and design and analysis and interpretation of the data: PS
Drafting of the article: KTW
Critical revision of the article for important intellectual content: TGC
Provision of study materials or patients: AR
Collection and assembly of data: JL

Correspondence

Praveen Singam
MD (UKM), MS (UKM)
Department of Urology, UKM Medical Center
Jalan Yaacob Latif
Bandar Tun Razak, 56000 Cheras
Kuala Lumpur, Malaysia
Tel: +6019 373 2381
Fax: +603 917 37831
Email: drpsingam@gmail.com

References

1. Eke N. Fournier's gangrene: A review of 1726 cases. *Br J Surg.* 2000;**87(6)**:718–728.
2. Mohamed JH, Jose ES, Richard B, Christopher LC. Genital Fournier's gangrene: Experience with 38 patients. *Urology.* 1996;**47(5)**:734–739.
3. Ullah S, Khan M, Asad Ullah Jan M. Fournier's gangrene: A dreadful disease. *Surgeon.* 2009;**7(3)**:138–142.
4. Smith GL, Bunker CB, Dinneen MD. Fournier's gangrene. *Br J Urol.* 1998;**81(3)**:347–355 .