

## Endoscopic Nipple-Sparing Mastectomy for Early Breast Cancer: A Case Series of a Minimally-invasive Technique

**Clarence Pio Rey C. Yacapin, MD, FPCS; Karen D. Mascardo, MD, FPCS;  
Judy Carissa M. Atazan, MD, FPCS and Jose Joven V. Cruz, MD, FPCS**

Department of Surgery, Asian Hospital and Medical Center

This study aimed to share the authors' preliminary experience with endoscopic nipple-sparing mastectomy in the Philippines. All medical records of patients who underwent endoscopic mastectomy done by the same surgeons in two institutions from March to October 2019 were collected and analyzed. Surgical margin, operating time, blood loss volume, and post-operative complications were noted. Three cases were recorded during the study period. The mean operative time was 341 minutes and the mean blood loss volume was < 20 mL. All cases had negative margins of resection on final histopathology. One patient developed ecchymosis on the axilla, while the other patients had unremarkable post-operative courses. Endoscopic nipple-sparing mastectomy is a potentially safe and feasible alternative in breast cancer management. Further evaluation of the procedure is recommended.

**Key words:** breast cancer, mastectomy, nipple-sparing, endoscopy

The incidence of breast cancer in the Philippines is among the highest in Asia and shows an increasing trend since the 1980s.<sup>1</sup> Modified radical mastectomy has been the standard treatment for breast cancer.<sup>2</sup> However, several advancements and techniques allowing breast conservation and sentinel node biopsy have been made over the last decade which showed comparable oncologic results, better cosmetic outcomes, and lesser morbidities compared to modified radical mastectomy.<sup>3-7</sup> A recent addition to the technique is nipple-sparing mastectomy with immediate breast reconstruction which has been shown to be feasible and oncologically safe.<sup>8-10</sup>

Another advancement in the field of surgery is the evolution towards minimally invasive procedures. The

initial application of minimally invasive techniques for breast surgery was for breast augmentation.<sup>11-13</sup> Eventually, endoscopic mastectomy, specifically endoscopic nipple-sparing mastectomy (ENSM), was used for dissection of malignant tumors because of its superior cosmetic result and patient satisfaction.<sup>14-16</sup>

This study aimed to describe the first cases and early outcomes of ENSM done in the Philippines. The authors will specifically describe the adequacy of histopathology margins, complications, operating time, and blood loss.

The objective was to describe the outcomes of endoscopic nipple-sparing mastectomy in the management of early breast cancer patients.

### The Case Series

#### *Case Materials*

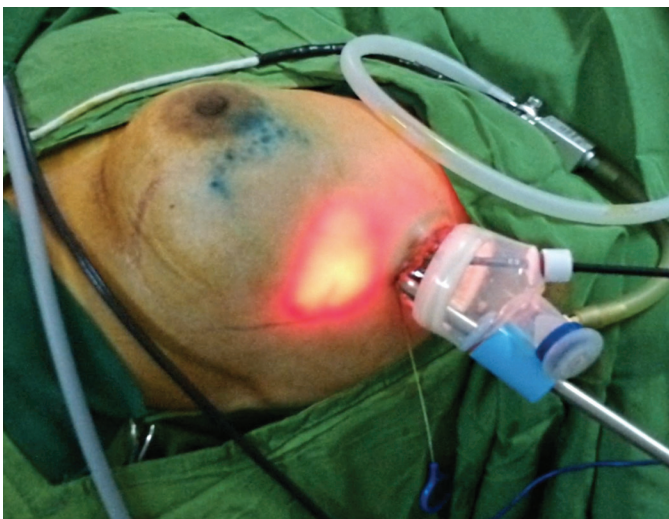This descriptive study was exempted for ethics review by the Research Ethics Committee. All medical records of patients who underwent ENSM with immediate breast reconstruction done by the same team of surgeons in Asian Hospital and Medical Center and Ospital ng Muntinlupa from March to October 2019 were collected and analyzed. Surgical margin, operating time, blood loss volume, and complications were noted. Follow-up was done after 1 week and 1 month. Post-operative images were collected to record the results of the implant insertion and progression of wound healing.

### *Operative Technique*

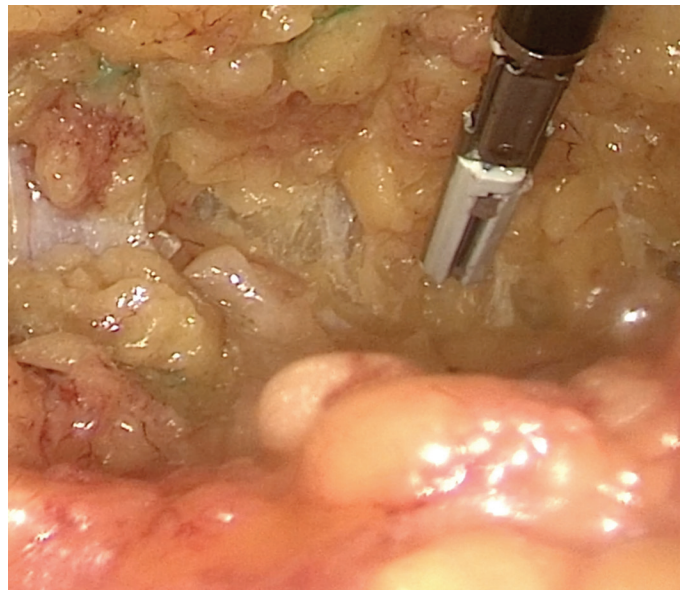
The patients were positioned supine with both arms abducted, and the surgical team was situated on the side of the mastectomy site. Patent Blue Dye (Bleu Patenté V Guerbet 2.5%) was injected subcutaneously at the sub-areolar and peri-areolar areas. Sentinel lymph node biopsy (SLNB) was done using an incision on the axillary area. The sentinel nodes with blue discoloration were then sent for frozen section. If they were positive for malignant cells, axillary node dissection would be performed before proceeding with ENSM.

A single port device was inserted in the same axillary incision used for SLNB (Figure 1). Carbon dioxide insufflation of up to 10 – 12 mmHg was done to create a space for dissection. Dissection of the breast was started on the superficial plane between the subcutaneous fat and the breast tissue. A LigaSure™ Maryland jaw device (Medtronic, Minneapolis, USA) was used for dissection to minimize bleeding was used for dissection to minimize bleeding (Figure 2).

After the retroareolar area has been dissected, tissue from the posterior retroareolar margin was taken and submitted for frozen section examination. If it was positive for malignancy, the operation was converted to skin-sparing mastectomy and the nipple-areola complex was excised.



**Figure 1.** Image showing a single port device inserted in the axillary area at the incision site used for sentinel node biopsy.



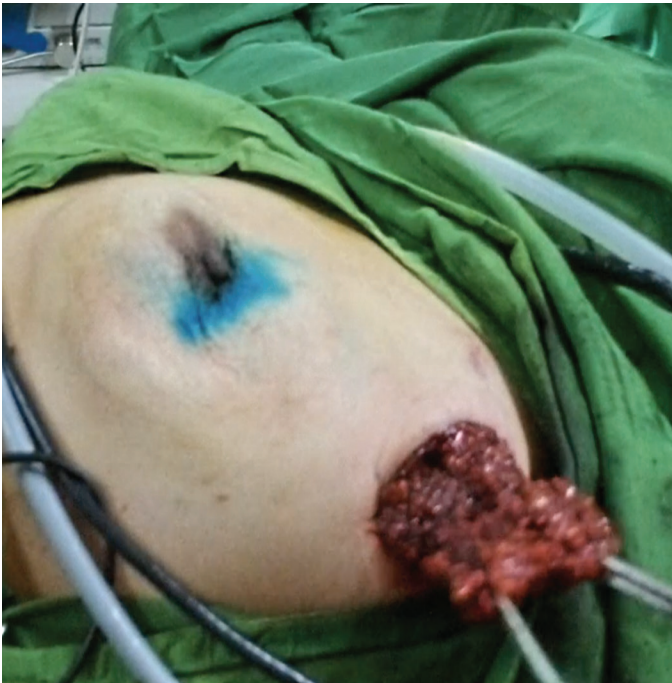**Figure 2.** Image showing dissection between the subcutaneous tissue and breast tissue using the LigaSure™ Maryland jaw device.

Dissection of the deep plane between the breast tissue and the pectoralis muscle was then done. The borders of dissection were the same as an open mastectomy: inferior border of the clavicle superiorly, para-sternal border medially, inframammary fold inferiorly, and medial border of the latissimus dorsi laterally. The breast tissue was then extracted through the same incision in the axilla which could be enlarged to 3-5cm if necessary (Figure 3).

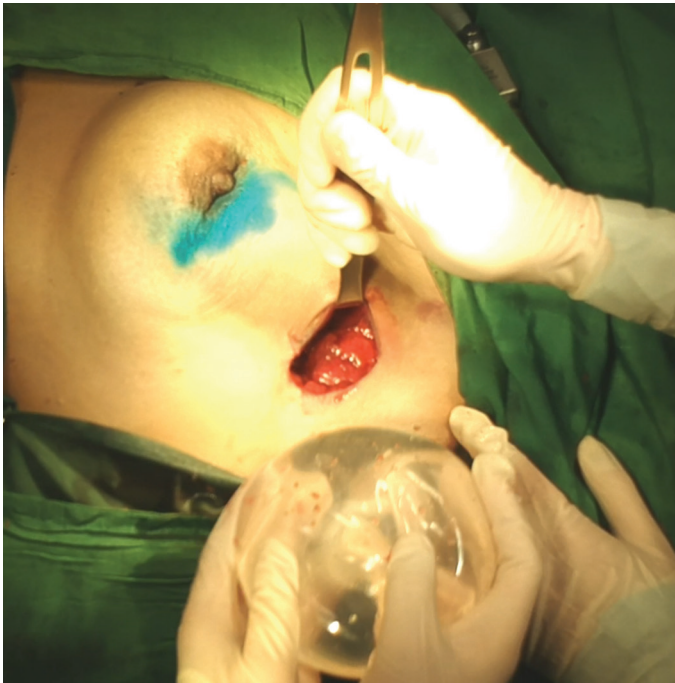Dissection of the area posterior to the pectoralis major was done to create enough space for the implant. Volume of the silicone implant was determined pre-operatively by the plastic surgeon and intra-operatively by inserting a breast implant sizer. Washing and hemostasis were then done prior to inserting the implant at the subpectoral space (Figure 4). JP drains were inserted subcutaneously, and the subcutaneous tissue and skin were closed in layers.

### **Results**

Three cases were recorded during the study period (Table 1). All were females diagnosed with breast cancer. Pre-operative evaluation to assess the patient's



**Figure 3.** Image showing the dissected breast specimen being extracted through the axillary incision.



**Figure 4.** Image showing the implant before insertion through the axillary incision.

**Table 1.** Summary of cases.

	Case 1	Case 2	Case 3
Age	54	55	52
Stage	Stage IA (T1N0M0)	DCIS*	Stage IIA (T1N1M0)
Tumor size (cm)	1.5	1.5	1.8
Distance from areola (cm)	6	2	2
Breast cup size	32B	32A	34B
Implant size (cc)	250	175	275
SLNB results	Negative	Negative	Positive (1/16)
Tumor margins	Negative	Negative	Negative
Operative time (min)	330	333	360
Blood loss (mL)	< 20	< 20	< 20
JP drain removal	1 week post-op	1 week post-op	1 week post-op
Complications	None	None	Ecchymosis axilla

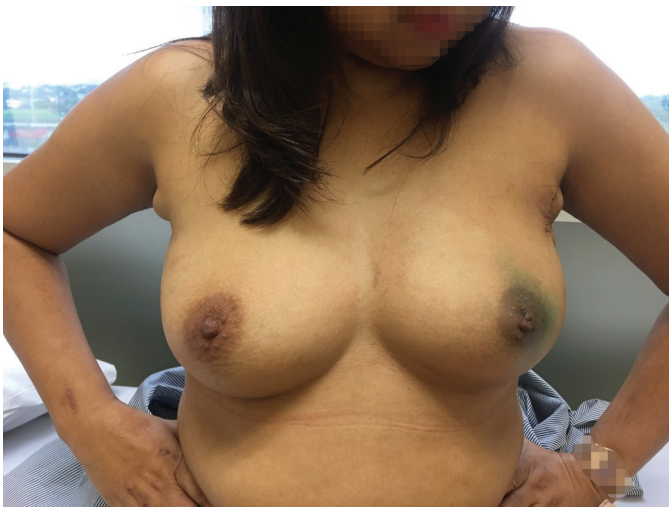\*DCIS = Ductal Carcinoma in Situ

qualification for the procedure included: core-needle biopsy to confirm the diagnosis, mammogram to rule out multi-centricity and multi-focality, breast and axillary ultrasound to confirm the tumor size and presence of enlarged axillary lymph nodes, pre-operative evaluation

by a plastic surgeon to determine the implant volume, and cardiopulmonary evaluation to determine the patient’s anticipated risks for the procedure. After all the pre-operative evaluation were done, consent was taken after risks and benefits were explained to the patients.



The three cases recorded had a mean operative time of 341 minutes and a mean blood loss volume of < 20 mL. One of the cases had positive malignancy cells on frozen section after SLNB, and axillary dissection was done. All cases had negative margins of resection on final histopathology. One patient developed ecchymosis on the axilla post-operatively which resolved after 1 week, while the other patients had unremarkable post-operative courses. Overall post-operative cosmetic outcome showed good wound healing of the incision site at the axillary region (Figure 5). The skin discoloration at the peri-areolar area due to the Patent Blue Dye (Bleu Patenté V Guerbet 2.5%) was still visible after 1 month of follow-up and the patients were advised that these would usually resolve after 18-24 months.



**Figure 5.** Post-operative image of a patient who underwent ENSM with immediate breast reconstruction on the left breast. The visible peri-areolar discoloration due to the Patent Blue Dye (Bleu Patenté V Guerbet 2.5%) will resolve after 18-24 months.

## Discussion

This study shows the potential of ENSM as a feasible alternative for open nipple-sparing or total mastectomy with immediate breast reconstruction among early breast cancer patients. Endoscopic mastectomy is already accepted as a viable and safe option for selected breast cancer patients in some countries.<sup>14-16</sup> It is commonly

used as an alternative for conventional mastectomy among Asian countries, particularly in Japan<sup>16-18</sup>, China<sup>19-20</sup>, and Korea<sup>21</sup>, due to the smaller breast volume of Asian patients. A retrospective study of 20 ENSM patients versus 25 conventional or open nipple-sparing mastectomy patients in Korea by Lee, et al. showed significantly longer average operative time of 33.2 minutes for ENSM cases (ENSM = 269.1±39.6 mins, Conventional NSM=235.9±43.8 mins), but no difference was found in post-operative complication rates.<sup>22</sup>

The criteria for patient selection in ENSM are similar to open nipple-sparing mastectomy, which include: tumors up to 5 cm (T1-T2) with or without axillary involvement (any N), tumor location of at least 2 cm or greater from the areola, and cup size C or less.<sup>23-26</sup> Pre-operative mammogram and breast and axillary ultrasound are important to identify qualified patients and to assess multi-centricity or multi-focality.

A retrospective cohort study in Korea by Wu, et al. involving 944 patients who underwent open nipple-sparing mastectomy showed 39 (4.1%) cases having recurrence at the nipple-areolar complex during a median follow-up of 85 months.<sup>27</sup> Multi-focality or multi-centricity, negative hormone receptor, high histologic grade, and extensive intraductal component were found to be independent risk factors for recurrence after open nipple-sparing mastectomy.<sup>27</sup>

On the other hand, a review by Mok, et al. involving 8 case series and 6 cohort studies of ENSM with a follow-up period of 19-74 months showed a local recurrence rate of up to 2.2%, distant metastasis rate of up to 10%, and overall survival rate of 96.8-100%.<sup>26</sup> There are no prospective studies yet comparing recurrence and survival rates among open versus endoscopic nipple-sparing mastectomies. In the review by Mok, et al., majority of the studies had negative margins of resection, while two studies showed positive margins in 4.8% and 1.1% of cases.<sup>26</sup> The most common complication among ENSM patients was implant infection and nipple-areola complex necrosis.<sup>26</sup> Nipple-areola necrosis is attributed to the insertion of trocars in that area which similarly occurs when an incision is placed near the areola during open nipple-sparing mastectomies.<sup>28</sup>

This study observed post-operative ecchymosis at the axillar area in one patient which resolved spontaneously

after 1 week of follow-up. This could have been caused by forceful retraction during the procedure. A similar bruising was reported by Ho, et al. in 2 out of 9 patients who underwent ENSM, which subsided after 3-4 weeks.<sup>29</sup>

The operative time for the cases in this study ranged from 330 to 360 minutes which is above the average published operating time of 229 minutes.<sup>30</sup> The most difficult part of the dissection was along the parasternal border. However, the operative time is expected to decrease with operator experience as shown by Hung, et al. where the average operating time of endoscopic total mastectomy of 275 minutes can be significantly reduced to 229 minutes once the surgeon reaches the learning curve of 15 cases.<sup>30</sup>

Endoscopic nipple-sparing mastectomy can achieve the same negative oncologic margin as with open mastectomy and the operative time can be improved by experience. The use of advanced electrosurgical devices contributed to the minimal blood loss, while nipple-areolar necrosis was prevented by not inserting trocars near the peri-areolar area. Pre-operative evaluation to carefully screen qualified patients is important to reduce the risk of recurrence.

Being a preliminary report of initial cases, this study is limited by the number of patients and the duration of observation. A longer observation period is recommended to compare the survival rate and recurrence rate of open and endoscopic nipple-sparing mastectomy. The sample size is too small to precisely reflect the average operating time, blood loss volume, and complication rates. A bigger cohort is recommended to represent the population accurately.

## Conclusion

This preliminary report of cases shows the feasibility and safety of ENSM in breast cancer management. Further evaluation of the procedure is recommended.

## References

1. Laudico A, Redaniel MT, Mirasol-Lumague MR, Mapua CA, Uy GB, Pukkala E, et al. Epidemiology and clinicopathology of breast cancer in Metro Manila and Rizal Province, Philippines. *Asian Pac J Cancer Prev* 2009 Jan-Mar;10(1):167-72.
2. Patey DH, Dyson WH. The prognosis of carcinoma of the breast in relation to the type of operation performed. *Br J Cancer* 1948; 2(1):7-13.
3. Veronesi U, Cascinelli N, Mariani L, Greco M, Saccozzi R, Luini A, et al. Twenty-year follow-up of a randomized study comparing breast-conserving surgery with radical mastectomy for early breast cancer. *N Engl J Med* 2002; 347(16):1227-32. DOI: 10.1056/NEJMoa020989
4. Fisher B, Anderson S, Bryant J, Margolese RG, Deutsch M, Fisher ER, et al. Twenty-year follow-up of a randomized trial comparing total mastectomy, lumpectomy, and lumpectomy plus irradiation for the treatment of invasive breast cancer. *N Engl J Med* 2002; 347(16):1233-41. DOI: 10.1056/NEJMoa022152
5. Giuliano AE, McCall L, Beitsch P, Whitworth PW, Blumencranz P, Leitch AM, et al. Locoregional recurrence after sentinel lymph node dissection with or without axillary dissection in patients with sentinel lymph node metastases: the American College of Surgeons Oncology Group Z0011 randomized trial. *Ann Surg* 2010; 252(3):426-32.
6. Anderson BO, Masetti R, Silverstein MJ. Oncoplastic approaches to partial mastectomy: an overview of volume-displacement techniques. *Lancet Oncol* 2005; 6(3):145-57. DOI: 10.1016/S1470-2045(05)01765-1
7. Holmes DR, Schooler W, Smith R. Oncoplastic approaches to breast conservation. *Int J Breast Cancer* 2011; 2011:303879. DOI: 10.4061/2011/303879
8. Petit JY, Veronesi U, Orecchia R, Rey PC, Martella S, et al. When mastectomy becomes inevitable: the nipple-sparing approach. *Breast* 2005; 14(6):527-31. DOI: 10.1016/j.breast.2005.08.028
9. Petit JY, Veronesi U, Orecchia R, Luini A, Rey P, Intra M, et al. Nipple-sparing mastectomy in association with intra operative radiotherapy (ELIOT): A new type of mastectomy for breast cancer treatment. *Breast Cancer Res Treat* 2006; 96(1):47-51. DOI: 10.1007/s10549-005-9033-7
10. Zurrada S, Bassi F, Arnone P, Martella S, Del Castillo A, Ribeiro Martini R, et al. The changing face of mastectomy (from Mutilation to aid to breast reconstruction). *Int J Surg Oncol* 2011; 2011: 980158. DOI: 10.1155/2011/980158
11. Eaves FF, Bostwick J, Nahai F, Murray DR, Styblo TM, Carlson GW. Endoscopic techniques in aesthetic breast surgery: augmentation, mastectomy, biopsy, capsulotomy, capsulorrhaphy, reduction, mastopexy, and reconstructive techniques. *Clin Plast Surg* 1995; 22: 683-95.
12. Momeni A, Padron NT, Bannasch H, Borges J, Bjorn Stark G. Endoscopic transaxillary subpectoral augmentation mammoplasty: a safe and predictable procedure. *J Plast Reconstr Aesthet Surg* 2006; 59(10):1076-81. DOI: 10.1016/j.bjps.2006.01.031
13. Ulusal BG, Cheng MH, Wei FC. Simultaneous endoscope-assisted contralateral breast augmentation with implants in patients undergoing postmastectomy breast reconstruction with abdominal flaps. *Plast Reconstr Surg* 2006; 118(6):1293-302.

14. Tamaki Y, Sakita I, Miyoshi Y, Sekimoto M, Takiguchi S, Monden M, et al. Transareolar endoscopy- assisted partial mastectomy: a preliminary report of six cases. *Surg Laparosc Endosc Percutan Tech* 2001; 11(6):356–62.
15. Lee EK, Kook SH, Park YL, Bae WG. Endoscopy-assisted breast-conserving surgery for early breast cancer. *World J Surg* 2006; 30(6):957–64. DOI: 10.1007/s00268-005-0202-y
16. Sakamoto N, Fukuma E, Higa K, Ozaki S, Sakamoto M, Abe S, et al. Early results of an endoscopic nipple-sparing mastectomy for breast cancer. *Ann Surg Oncol* 2009; 16(12):3406–13. DOI: 10.1245/s10434-009-0661-8
17. Tamaki Y, Sakita I, Miyoshi Y, Sekimoto M, Takiguchi S, Monden M, et al. Transareolar endoscopy- assisted partial mastectomy: a preliminary report of six cases. *Surg Laparosc Endosc Percutan Tech* 2001; 11(6):356–62.
18. Lee EK, Kook SH, Park YL, Bae WG. Endoscopy-assisted breast-conserving surgery for early breast cancer. *World J Surg* 2006; 30(6):957–64. DOI: 10.1007/s00268-005-0202-y
19. Fan LJ, Jiang J, Yang XH, Zhang Y, Li XG, Chen XC, et al. A prospective study comparing endoscopic subcutaneous mastectomy plus immediate reconstruction with implants and breast conserving surgery for breast cancer. *Chin Med J (Engl)* 2009; 122(24):2945–50.
20. Ho WS, Ying SY, Chan AC. Endoscopic-assisted subcutaneous mastectomy and axillary dissection with immediate mammary prosthesis reconstruction for early breast cancer. *Surg Endosc* 2002; 16 (2):302–6. DOI: 10.1007/s004640000203
21. Park HS, Lee JS, Park S, Kim SI, Park BW. The feasibility of endoscopy-assisted breast conservation surgery for patients with early breast cancer. *J Breast Cancer* 2011; 14(1):52–7. DOI: 10.4048/jbc. 2011.14.1.52
22. Lee HY, Chang YH, Yu DY, Lee TY, Kim DW, et al. Comparison of single incision endoscopic nipple-sparing mastectomy and conventional nipple-sparing mastectomy for breast cancer based on initial experience. *J Breast Cancer* 2021 Apr;24(2):196-205. DOI: <https://doi.org/10.4048/jbc.2021.24.e18> pISSN 1738-6756.
23. Simmons RM, Brennan M, Christos P, King V, Osborne M. Analysis of nipple/areolar involvement with mastectomy: can the areola be preserved? *Ann Surg Oncol* 2002 Mar;9(2):165-8.
24. Billar JA, Dueck AC, Gray RJ, Wasif N, Pockaj NA. Preoperative predictors of nipple-areola complex involvement for patients undergoing mastectomy for breast cancer. *Ann Surg Oncol* 2011 Oct;18(11):3123-8.
25. Brachtel EF, Rusby JE, Michaelson JS, Chen LL, Muzikansky A, Smith BL, Koerner FC. Occult nipple involvement in breast cancer: clinicopathologic findings in 316 consecutive mastectomy specimens. *J Clin Oncol* 2009 Oct 20;27(30):4948-54.
26. Mok CW, Lai HW. Endoscopic-assisted surgery in the management of breast cancer: 20 years review of trend, techniques and outcomes. *Breast* 2019 Aug;46:144-56.
27. Wu Z, Kim H, Lee J, Chung I, Kim J, Lee S, et al. Breast cancer recurrence in the nipple-areola complex after nipple-sparing mastectomy with immediate breast reconstruction for invasive breast carcinoma. *JAMA Surg* 2019 Nov; 154(11): 1030–7. DOI: 10.1001/jamasurg.2019.2959; 10.1001/jamasurg.2019.2959.
28. Daar DA, Abdou Sa, Rosario L, Rifkin WJ, Santos PJ, Wirth Ga, et al. Is there a preferred incision for nipple-sparing mastectomy? a systematic review and meta-analysis. *Plast Reconstr Surg* 2019 May;143(5): 906e-919e.
29. Ho WS, Ying ST, Chan ACW. Endoscopic-assisted subcutaneous mastectomy and axillary dissection with immediate mammary prosthesis reconstruction for early breast cancer. *Surg Endosc* 2002;16: 302–6. DOI: 10.1007/s004640000203.
30. Hung CS, Chang SW, Liao LM, Huang CC, Tu SH, Chen TS, et al. The learning curve of endoscopic total mastectomy in Taiwan: a multi-center study. *PLoS ONE* 12(6): e0178251. DOI:10.1371/journal.pone.0178251