

Malignant Phyllodes Tumor in the Male: A Case Report

Eloise Ana T. Suan, MD; Manfred T. Tabilog, MD; Rogelio G. Kangleon, Jr., MD, FPCS, FACS;
Hamabad C. Ranile Jr., MD, FPCS, FPATACSI, FPAMITS and Alain O. Senerpida, MD, FPCS, FPAPRAS

Department of Surgery, Perpetual Succour Hospital, Lahug, Cebu City

Phyllodes tumors are breast tumors accounting for about 1% of all breast neoplasms in women and are rare in males. Reported here is a case of a 45-year-old male presenting with a rapidly enlarging right breast mass with invasion of the anterior chest wall. Core Needle Biopsy revealed Malignant Phyllodes Tumor. He underwent wide excision and chest wall resection. Reconstruction was performed using polypropylene mesh, a latissimus dorsi flap and split thickness skin grafting. Patient was discharged on the 33rd post-operative day due to delayed expansion of the right lung from splinting and subsequent near-complete loss of the split thickness skin graft over the latissimus muscle flap. On the recommendation of the plastic surgeon, the wound was allowed to heal by secondary intention. This report draws attention to the rarity of malignant phyllodes tumor in males, and the difficulty of recognizing a malignant pathology in males presenting with breast mass. It also highlights a cost-effective treatment option in the management of these tumors.

Key words: Malignant Phyllodes tumor, Male Phyllodes tumor, breast

Phyllodes tumor (PT) once commonly referred to as cystosarcoma phyllodes, is a rare, predominantly benign tumor that represents roughly 0.3%-1% of all breast tumors in women.¹

Malignant Phyllodes tumors are uncommon. If not treated correctly with wide surgical excision, the recurrence rate has been reported to be 20%-50%.² As the occurrence of malignant phyllodes tumor in male patients is extremely rare, the limited literature has not clearly established its incidence rate. A large retrospective meta-analysis study done by Spitaleri, et al. reviewed 5530 patients with a breast pathology. A total of 172 patients had a final histopathology of phyllodes tumor and only one (0.58%) was reported in a male patient with a

history of gynecomastia.³ As such, the authors present an interesting and rare case of a locally-advanced malignant Phyllodes tumor with chest wall invasion diagnosed in a 45-year-old male, its diagnostic and treatment strategy.

The Case

A 45-year-old male was admitted for a huge, fixed ulcerating mass of the right lower anterior chest (Figure 1). The patient had no known comorbidities, a non-smoker, with a history of substance abuse (Metamphetamine) but denied usage for over 2 years. He also denied any family history of cancer of any sort.

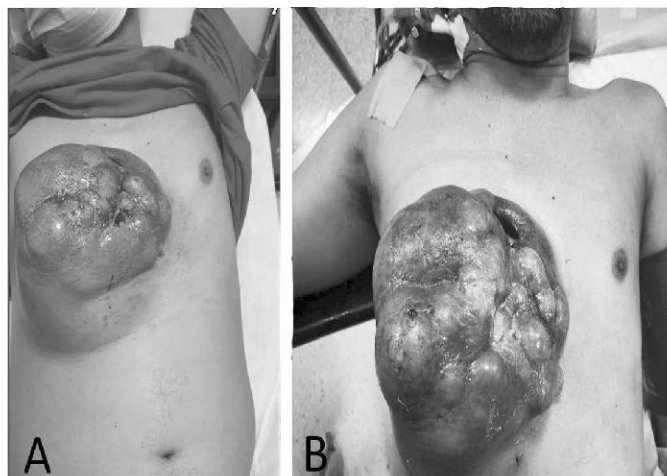


Figure 1. 45- year old male with a large, 17.5 cm x 16.4 cm x 13.5 cm, erythematous, ulcerating, right breast mass: (A) Taken preoperatively in the outpatient department for core needle biopsy; (B) Taken immediately prior to surgery, 3-weeks after core needle biopsy and 2-weeks after completion of antibiotic therapy

Twenty-three years prior to his admission, the patient noted a fixed, non-tender mass on his right lower anterior chest measuring approximately 1.5 cm. In the interim, the mass gradually increased in size to approximately 9 cm in the past 2 years, with note of ulceration and serosanguinous discharge associated with minimal pain. The patient sought consult and was advised biopsy and CT scan but was initially non-compliant due to financial constraints. Further progression in size and ulceration prompted patient to seek another consult where a core needle biopsy was done which was read as "Malignant Phyllodes Tumor". The patient was advised to undergo surgery but was again lost to follow-up. Increasing persistent pain, discharge, and discomfort, eventually led to the patient seeking surgical intervention.

A preoperative multi-specialty conference was done during which the consensus was to repeat the core biopsy for comparison with the previous biopsy done at a different hospital. Regardless of the repeat biopsy result, the plan was to do a radical surgical extirpation and chest reconstruction for local control and relief of symptoms. The repeat core biopsy was confirmed as Malignant Phyllodes Tumor (Figure 2). A CT scan with contrast was subsequently done which showed a large lobulated heterogeneously enhancing predominantly cystic ulcerating mass with calcifications measuring approximately 17.5 cm x 16.4 cm x 13.5 cm with infiltration of the underlying chest wall and lytic destruction of the right second to sixth costal cartilage (Figure 3). Meropenem was started preoperatively after a culture of *Pseudomonas aeruginosa* was isolated from the breast ulceration.

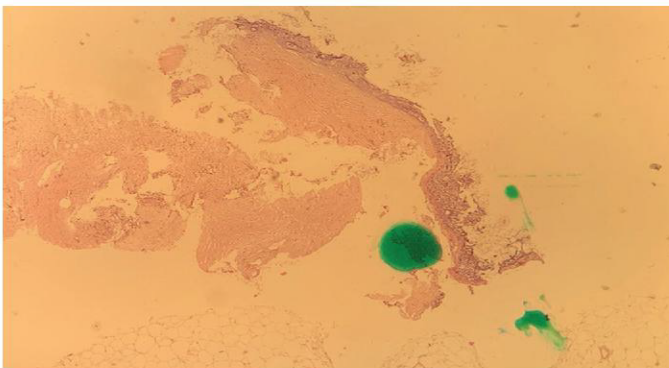


Figure 2. Core needle biopsy specimen of breast mass showing marked stromal cellularity and atypia consistent with malignant phyllodes tumor.

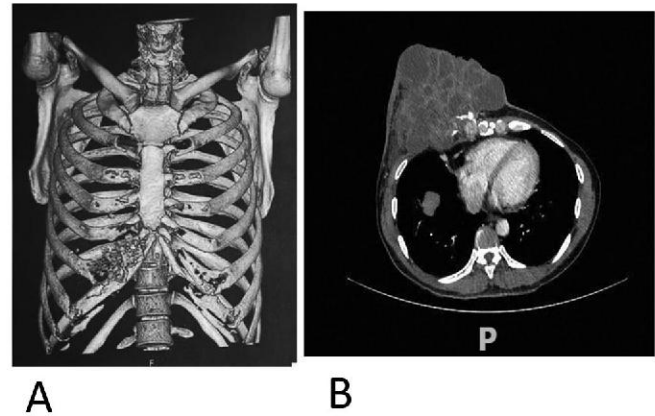


Figure 3. CT scan of the chest with IV contrast: (A) 3D reconstruction of anterior chest wall demonstrating lytic destruction of the underlying 2nd to 6th costal cartilage; (B) A large lobulated ulcerating mass with calcifications in the right breast, measuring approximately 17.5 cm x 16.3 cm x 13.5 cm, extending into the subjacent pleural space.

The patient subsequently underwent a wide full-thickness resection, en bloc removal of the right breast and underlying pectoralis. Intraoperative findings showed infiltration by the mass of the 4th to 6th ribs. This in addition to the pre-operative CT scan findings, led the team to include a partial resection of the 3rd to 7th ribs. Reconstruction followed using a sheet of polypropylene mesh (Surgipro™ Monofilament Polypropylene Mesh, Covidien) covered with a latissimus dorsi muscle flap and split thickness skin graft (Figure 4). Two chest tubes were placed inside the right thoracic cavity.

The patient was placed in the ICU on assisted ventilation. The first week was marked by delayed expansion of the right lung mainly due to splinting from pain (Clavien-Dindo Classification: Grade IVa). The patient was weaned from ventilator on Post-op Day 3 and chest tubes removed on Post-op Day 13. Unfortunately, there was a near-complete loss of the split thickness skin graft over the latissimus muscle flap. It was the recommendation of the plastic surgeon to allow granulation to proceed and to re-assess the wound later. The patient was discharged on the 33rd postoperative day with instructions of regular outpatient follow-up for wound care. Plans for adjuvant radiotherapy were put on hold pending complete wound healing.

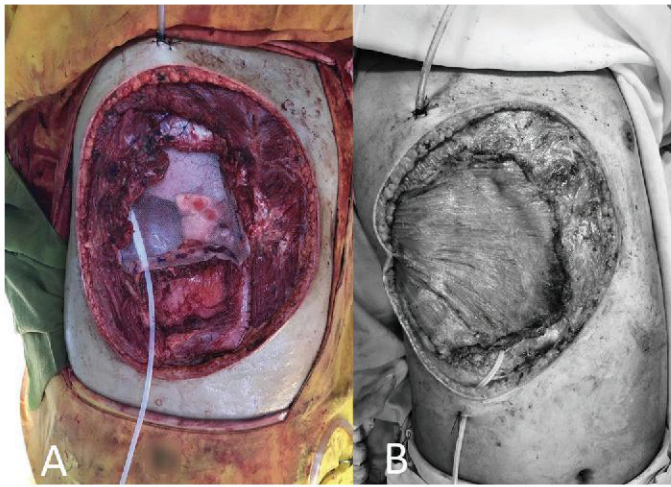


Figure 4. Intra-operative images (7cm(L) x 5cm(W) defect of the anterior chest wall and a 20cm(L) x 10cm(W) skin defect post resection): (A) Reconstruction of the anterior chest wall defect with polypropylene mesh (Surgipro™ Monofilament Polypropylene Mesh, Covidien); (B) Tissue Coverage using a Latissimus dorsi flap.

The final histopathology reported was Malignant Phyllodes Tumor with extensive skin ulceration. Five ribs (3rd to 7th rib) measuring 11.5cm x 11.5cm x 3cm included in the submitted specimen demonstrated tumor involving the 4th to 6th ribs. Posterior, superior, inferior, medial, and lateral margins were negative for tumor (Figure 5).

Discussion

Phyllodes tumors of the breast are biphasic tumors. They are composed of two different cellular elements, namely epithelial and stromal. It accounts for about 1% of breast neoplasm in women and rarely occurs in men. Few literature regarding the incidence of malignant phyllodes tumor diagnosed in male patients have been published. Of 172 patients diagnosed with phyllodes tumor in a study by Spitaleri, et al.³, only 1 patient was male. Clinically, these tumors are usually rapidly growing and painless without specific clinical manifestation. In this patient however, there was a slowly enlarging unilateral breast mass for over twenty-three years.

Due to the rarity of phyllodes tumor occurring in males, its risk factors have also been a subject of

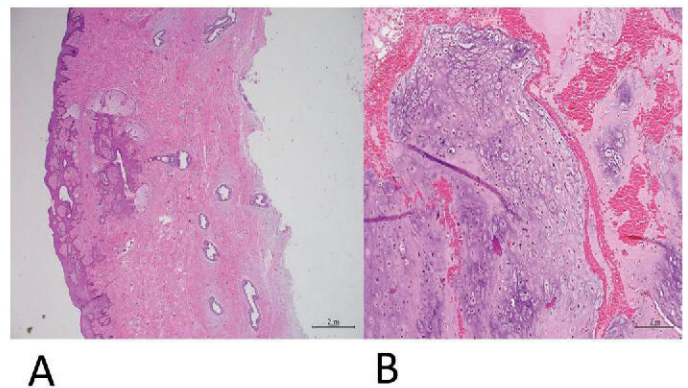


Figure 5. Final histopathology report of Right breast mass with anterior chest wall: (A) Microscopic examination showing sections of skin and underlying tissue: The overlying skin is extensively ulcerated and is undermined by neoplastic process. There is loss of lobular architecture and instead there are scattered dilated ducts lined by piled up columnar epithelium with surrounding fibromyxoid stroma; (B) Microscopic examination of right breast with adjacent muscle and rib "deep resection margin": shows neoplastic process characterized by nodular islands and nests of chondromyxoid tissue with scattered spindle-shaped cells demonstrating enlarged irregular nuclei and marked atypia consistent with Malignant Phyllodes Tumor.

study with only a few reported cases. Although the exact etiology of the development of phyllodes tumor in the male is unknown, hormonal imbalance between estrogen action relative to androgen and pre-existing gynecomastia is thought to have a significant correlation with its development.⁴ Other explored causes include hormone-secreting tumors, hormonal therapy for prostate cancer, obesity, liver, and thyroid diseases, or drug abuse. Karithala, et al. report of a male patient diagnosed with malignant phyllodes tumor at the 8th year of Bicalutamide treatment for prostate cancer.⁵ Patient in the present case had no known relevant medical history. Although he had been a previous chronic metamphetamine user, the development of the chest wall mass pre-dates his history of drug abuse.

Current WHO classification of tumors of the breast has divided PTs into benign, borderline, and malignant categories based on the combination of histological features.⁶ Malignant phyllodes tumor shows marked stromal cellularity and atypia, and has permeative margins and mitotic activity of at least 10/10 HPFs.

Treatment of phyllodes tumors is by surgical resection with tumor-free margins of 1 cm or greater. This can be done by oncoplastic lumpectomy or total mastectomy.⁷ Distant metastasis is by hematologic spread and metastasis to the lymph nodes, is rare. As such, lymph node dissection for malignant phyllodes tumor is not necessary. Chest wall invasion in malignant phyllodes tumor and its management has rarely been reported in medical literature as well.⁸ In a study by Reinfuss, et al., 2.4% in 170 women with phyllodes tumor showed invasion to the pectoralis major, all of which was managed by radical resection with chest wall reconstruction.⁹ A report by Kuo, et al. has also showed promising effects of performing preoperative transarterial chemoembolization in reducing tumor size in phyllodes tumor with chest wall invasion.¹⁰ It was the extensive ulceration and associated infection of this patient's lesion that led the multidisciplinary panel to recommend radical resection with chest wall reconstruction.

A challenge discussed during the multidisciplinary meeting was the method to be used for chest wall reconstruction, considering this patient's financial constraints. After resection, he was left with a 7 cm (L) x 5 cm (W) defect of the anterior chest wall and a 20 cm (L) x 10 cm (W) skin defect. The primary goal of chest wall reconstruction is to eliminate dead space, restoration of chest wall rigidity to protect intrathoracic organs, provide soft tissue coverage, and minimize deformity.¹¹ A number of synthetic, biologic, and metallic materials have been utilized to reconstruct the chest wall, each has its own benefits and disadvantages, although none have proven to be clearly superior.¹² Sanna, et al. had described and recommended that the use of titanium plates for rib prosthesis and coverage with titanium mesh or Polytetrafluoroethylene (PTFE) to provide a more stable and rigid chest wall.¹³ Due to the patient's financial issues, the choices for reconstructing the chest wall were limited. A retrospective study by Schroeder-Finckh, et al. reviewed 45 isolated cases of anterior chest wall reconstruction and had concluded that, although not rigid, the use of polypropylene mesh alone could safely be used for anterior chest wall reconstruction.¹⁴ The team opted to proceed with this technique of reconstruction for this patient: coverage with a polypropylene mesh

followed by a latissimus dorsi flap and split-thickness skin graft.

There is no evidence that endocrine therapy or adjuvant cytotoxic chemotherapy provide any benefit. Radiation therapy may be done for extensive margin-positive disease or local recurrence, but this recommendation is controversial.¹⁵ Postoperative radiation therapy was discussed and recommended by the multidisciplinary team and treatment will follow, pending complete wound healing.

Conclusion

This case report highlights the rarity of malignant phyllodes tumor in males, and the difficulty in its recognition and the importance of procuring an accurate tissue diagnosis for adequate management. The primary goal in chest wall reconstruction is to provide tissue coverage to protect intrathoracic contents. This case report also presents the viability of the use of polypropylene mesh followed by muscle (latissimus dorsi) flap and split-thickness skin grafting alone as a cost-effective technique of reconstructing the chest wall.

References

1. Zhang Y, Kleer CG. Phyllodes tumor of the breast: Histopathologic features, differential diagnosis, and molecular genetic updates. *Arch Pathol Lab Med* 2016 Jul;140(7):665-71.
2. Liang MI, Ramaswamy B, Patterson CC, et al. Giant breast tumors: surgical management of phyllodes tumors, potential for reconstructive surgery and a review of literature. *World J Surg Oncol* 2008;6:117.
3. Spitaleri G, Toesca A, Botteri E, et al. Breast phyllodes tumor: a review of literature and a single center retrospective series analysis. *Crit Rev Oncol Hematol* 2013; 88: 427-36.
4. Chougule A, et al. Recurrent Phyllodes tumor in the male breast in a background of gynaecomastia. *J Breast Disease* 1 Jan. 2015; 139-42.
5. Peeter K, Tarja R, Tuominen H. Male malignant phyllodes breast tumor after prophylactic breast radiotherapy and bicalutamide treatment: A case report. *Anticancer Res J* 2016; 36 (7): 3433-6.
6. Lakhani SR, Ellis IO, Schnitt SJ, Tan PH, van de Vijver MJ, editors. *World Health Organization Classification of Tumours of the Breast*. Lyon: IARC Press; 2012.

7. Chaney AW, Pollack A, McNeese MD, Zagars GK, Pisters PWT, Pollock RE, et al. Primary treatment of cystosarcoma phyllodes of the breast. *J Cancer Oncol* 2000; 89 (7):1502–11.
8. Andrade Neto JD, Terra RM, Fernandez A, et al. Full-thickness chest wall resection for recurrent breast phyllodes tumor. *Ann Thorac Surg* 2007; 83: 2196–7.
9. Reinfuss M, Mituś J, Duda K, Stelmach A, Ryś J, Smolak K. The treatment and prognosis of patients with phyllodes tumor of the breast: an analysis of 170 cases. *American Cancer Society* 1996 Mar 1;77(5):910-6.
10. Kuo CY, Lin SH, Lee KD, Cheng SJ, Chu JS, Tu SH. Transcatheter arterial chemoembolization improves the resectability of malignant breast phyllodes tumor with angiosarcoma component: a case report. *BMC Surgery* 2019 Jul 27;19(1):100.
11. Seder CW, Rocco G. Chest wall reconstruction after extended resection. *J Thorac Dis* 2016;8:S863-S871.
12. Weyant MJ, Bains MS, Venkatraman E, Downey RJ, Park BJ, Flores RM, Rizk N, Rusch VW. Results of chest wall resection and reconstruction with and without rigid prosthesis. *Ann Thorac Surg* 2006 Jan;81(1):279-85.
13. Sanna S, Brandolini J, Pardolesi A, Argnani D, Mengozzi M, Dell'Amore A, Solli P. Materials and techniques in chest wall reconstruction: a review. *J Visualized Surg* 2017 Jul 26;3:95.
14. Schroeder-Finckh A, Lopez-Pastorini A, Galetin T, Defosse J, Stoelben E, Koryllos A. Anterior chest wall reconstruction using polypropylene mesh: A retrospective study. *J Thorac Cardiovascular Surg* 2020 Jun; 68(4):341-35.
15. Warner WA, Sookdeo VD, Fortuné M, et.al. Clinicopathology and treatment of a giant malignant phyllodes tumor of the breast: A case report and literature. *Rev Int J Surg Case Rep* 2017; 41: 259-64.