Clinical Research

Modified BI-RADS model for stratifying borderline breast lesions based on BI-RADS: a cross-sectional study

Lydia Purna Kuntjoro[1,2], Ignatius Riwanto[3], Hermina Sukmaningtyas[1], Yan Wisnu Prajoko[3], Suhartono[4], Lina Choridah[5], Endang Mahati[6], Kevin Christian Tjandra[7], Clarissa Aulia Pravitha[7]

Check for updates

pISSN: 0853-1773 • eISSN: 2252-8083
https://doi.org/10.13181/mji.oa.258117
Med J Indones. 2026;35:62–9

Received: March 11, 2025
Accepted: December 29, 2025

Authors' affiliations:
[1]Department of Radiology, Faculty of Medicine, Universitas Diponegoro, Semarang, Indonesia, [2]Doctoral Study Program of Medical and Health Science, Universitas Diponegoro, Semarang, Indonesia, [3]Department of Surgery, Faculty of Medicine, Universitas Diponegoro, Semarang, Indonesia, [4]Department of Environmental Health, Faculty of Public Health, Universitas Diponegoro, Semarang, Indonesia, [5]Department of Radiology, Faculty of Medicine, Public Health and Nursing, Universitas Gadjah Mada, Yogyakarta, Indonesia, [6]Department of Pharmacology and Therapeutics, Faculty of Medicine, Universitas Diponegoro, Semarang, Indonesia, [7]Faculty of Medicine, Universitas Diponegoro, Semarang, Indonesia

Corresponding author:
Lydia Purna Kuntjoro
Department of Radiology, Faculty of Medicine, Universitas Diponegoro, Jalan Prof. Sudarto, Tembalang, Semarang 50275, Central Java, Indonesia
Tel/Fax: +62-24-76928011
E-mail: lydiakuntjoro@gmail.com

ABSTRACT

BACKGROUND Breast imaging reporting and data system (BI-RADS) is a globally recognized method for categorizing breast lesions. However, it is dependent on subjective interpretation, which can result in variability between radiologists. Currently, no scoring system exists to assist in categorizing borderline findings as either benign or malignant. This study aimed to introduce a scoring system that classifies borderline breast lesion findings without altering the standard BI-RADS interpretation and minimizes inter-reader variability.

METHODS This single-center retrospective cross-sectional study included 215 women who underwent breast ultrasound (US) and histopathology between January 2021 and December 2022, excluding those with non-neoplastic breast lesions. The index test was US BI-RADS features, and the reference standard was histopathology. Prevalence ratios (PRs) and probability scores were used to assess the risk contribution of individual US features. The diagnostic performance of the BI-RADS interpretation strategy and predictive scoring model was compared with that of the standard BI-RADS classification using SPSS software version 26.

RESULTS Margin, orientation, and age had the highest PRs of malignancy, with odds ratios and 95% confidence intervals of 39.86 (13.19–120.47), 17.47 (2.42–125.72), and 9.74 (3.51–27.04), respectively. These three characteristics increased the probability of malignancy by 99.53%. A comparison of diagnostic tests between the modified BI-RADS interpretation strategy and the standard BI-RADS classification revealed improvements in specificity (94.0% *versus* 84.7%), positive predictive value (85.0% *versus* 70.5%), accuracy (89.3% *versus* 84.7%), and area under the curve (0.931 *versus* 0.873).

CONCLUSIONS According to the interpretation strategy, margin, orientation, and age, this US scoring model appear to be promising tools for classifying borderline malignant masses.

KEYWORDS BI-RADS, breast cancer, breast ultrasonography, predictive value of tests

Breast cancer (BC) is the leading cause of cancer incidence and mortality in women worldwide, with the World Health Organization (WHO) reporting approximately 2.3 million new cases and 685,000 deaths annually. In low- and middle-income countries (LMICs), such as Indonesia, BC accounts for 16.6% of new cancer cases and 32% of deaths.[1] Ultrasound (US) is a cost-effective and widely available supplementary screening tool for BC. Considering the growing number of BC cases in LMICs and limited access to timely imaging, US offers a widely available and cost-effective resource.[2] The breast imaging reporting and data system (BI-RADS) serves as an effective primary screening and triage tool, facilitating the detection of abnormalities and providing

Copyright @ 2026 Authors. This is an open access article distributed under the terms of the Creative Commons Attribution-NonCommercial 4.0 International License (http://creativecommons.org/licenses/by-nc/4.0/), which permits unrestricted non-commercial use, distribution, and reproduction in any medium, provided the original author and source are properly cited. For commercial use of this work, please see our terms at https://mji.ui.ac.id/journal/index.php/mji/copyright.

valuable guidance for subsequent treatment decisions, particularly in low-resource settings.[3]

The BI-RADS, developed by the American College of Radiology (ACR), standardizes breast imaging interpretation through a unified lexicon, enabling consistent communication and enabling healthcare professionals across specialties to interpret and respond accurately to findings.[4] Key lesion features, such as margin, shape, and echogenicity, are important for accurate classification.[5] However, BI-RADS remains highly subjective owing to non-standardized criteria, increasing the risk of misclassifying borderline lesions between BI-RADS 3 and 4. In India, Dariya et al[6] found that >4% of patients classified as BI-RADS 2 and 3 were later diagnosed with malignancy on histopathological examination. In contrast, the ACR guidelines indicate a malignancy risk of <2% for BI-RADS 2 and 3. This discrepancy suggests that radiologists in LMICs may have a lower diagnostic accuracy than those in developed countries. While the ACR has introduced comprehensive training programs to improve breast imaging skills, the high cost of these programs limits their widespread adoption in LMICs.[7,8] Moreover, there is no standardized scoring system to aid in distinguishing borderline findings as benign or malignant. Inter-reader variability remains substantial, and existing models have not been validated for LMICs. This gap highlights the need for an accessible, objective scoring system. Therefore, this study aimed to develop a practical classification system that uses ultrasonographic imaging characteristics to categorize borderline breast lesions as benign or malignant. Rather than replacing BI-RADS, the classification approach is intended to complement it by enhancing diagnostic precision and reducing interobserver variability, particularly in resource-limited settings.

METHODS

Study design, sample, and setting

We conducted a single-center retrospective cross-sectional study at Ken Saras Hospital, Semarang, Indonesia, comparing US BI-RADS features with histopathology from January 1, 2021, to December 31, 2022. This study used total sampling, recruiting women of any age who underwent breast ultrasonography and subsequent histopathological examination. Participants included those with a history of BC or prior breast surgery/therapy, and those with single or multiple lesions; only the most suspicious lesions were analyzed. Patients were drawn from a symptomatic clinical setting, consisting of women presenting with breast lumps, and consecutively recruited from both outpatient and inpatient services. Patients with normal US findings were excluded from the study because tissue sampling was not performed, precluding histopathological correlation. Furthermore, cases with histopathological findings indicative of non-neoplastic conditions, such as infections, trauma-related alterations, or anatomical variants, were excluded to ensure that the study focused on borderline BC. No a priori sample size calculations were performed. A minimal post hoc precision check was conducted by examining the width of the 95% confidence intervals (CIs) for the key diagnostic estimates, which demonstrated acceptable precision. Cases with missing data were excluded from the analysis.

Imaging analysis

All breast US examinations were performed using the same US system, a Samsung HS60 US system (Samsung Medison, South Korea), with a linear array transducer (probe linier LA3-14AD) operating at 3.0–14.0 MHz with automatic size adjustment. Measurements were obtained from the largest dimensions. The imaging protocol remained unchanged throughout the study period, with no equipment upgrades following the institutional breast United States protocol, such as patients being positioned supine and both breasts being scanned using B-mode imaging. The lesions were assessed in two perpendicular planes for tissue composition, mass shape, mass orientation, mass edge, echo pattern, posterior features, presence or absence of calcification, duct changes, vascularity, skin changes, and mass size. All US examinations were performed by board-certified radiologists with 5–12 years of experience (operators identified as SI, LK, SH, and DW). Each examination was interpreted by the same operator who performed the scan, based on the ACR BI-RADS 2013 lexicon. No discrepancies were observed because a single radiologist evaluated each case.

Histopathological analysis

Histopathological examination was performed by a pathologist using an incisional biopsy obtained 1–2 weeks after US examination of a suspicious breast area, stained with hematoxylin and eosin, and analyzed to discern the distinctive characteristics of

neoplastic cells. Tumors were classified as benign or malignant according to the WHO Breast Pathology 2022 (5th edition). Histopathologically proven malignancies included invasive carcinomas and high-grade malignancies, such as invasive ductal carcinoma, invasive lobular carcinoma, and malignant phyllodes tumors.[9] All other histopathological outcomes were classified as benign lesions, including fibroadenomas, fibrocystic changes, and benign phyllodes tumors.[9]

Data and statistical analysis

Data were processed using SPSS software version 26 (IBM Corp., USA). All the imaging features were classified into nominal categories. Margins were categorized as circumscribed or non-circumscribed; orientation as parallel or non-parallel; shape as oval or irregular; echogenicity based on comparison with fat; posterior acoustic features and calcifications as present or absent; vascularity based on internal Doppler flow; and lesion size above or below 2 cm (based on the cutoff on tumor, nodes, dan metastasis staging for breast lesions). Age was categorized using a 40-year threshold based on the literature, demonstrating an increased risk of BC after this age. Associations between age, imaging features, and histopathological results were evaluated using the chi-square test or Fisher's exact test to identify associations using bivariate tests.

The risk of breast malignancy was estimated based on breast US characteristics and presented the results as prevalence ratios (PRs) with 95% CIs. This multivariate model was developed for predictive purposes rather than for causal inferences. Variables with $p \leq 0.25$ in the bivariate analysis were included in a multivariate logistic regression (forward conditional) model to identify which variables most significantly affected histopathological outcomes. Each significant variable was assigned a risk score (1, 2, 3, and so on) proportional to the adjusted odds ratio (aOR).

A model was built to predict the probability of malignancy by using binary logistic regression. The predicted probability of each criterion was calculated, and cumulative patient scores were obtained by summing the significant variable scores. The average predicted probability served as the cutoff: values >0.5 were classified as positive (1) and <0.5 as negative (0).

Finally, the sensitivity, specificity, positive predictive value (PPV), negative predictive value (NPV), and accuracy of the BI-RADS interpretation strategy were compared with the standard BI-RADS classification. Probability scores were plotted as receiver operating characteristic (ROC) curves, and the area under the curve (AUC) was calculated. This was conducted to assess the robustness of the main findings and to determine whether the US scoring model enhanced the standard comprehensive BI-RADS classification. Although the radiologists were blinded to the histopathological outcomes, the operator-dependent nature of US introduced the possibility of observer bias.

Ethical considerations

This study was approved by the Health Research Ethics Committee, Faculty of Medicine, Universitas Diponegoro (No. 119/EC/KEPK/FK-UNDIP/IV/2023), with additional permission from Ken Saras Hospital (No. 430/S.Ket/RSKS/V/2023). The protocol was conducted in accordance with the Declaration of Helsinki.

RESULTS

Patient characteristics

A total of 215 patients met the inclusion criteria (age 15–79 years; mean (standard deviation [SD]: 35.32 [13.90]). Malignant masses were observed in 65 patients (30.2%; mean [SD] age of 47.54 [9.62]), while benign masses were identified in 150 patients (69.8%; mean [SD] age of 30.03 [12.02]). Patients with normal breast US results, missing histopathological records, or non-neoplastic findings (e.g., tuberculosis) were excluded (Figure 1).

Prevalence ratio (PR)

Breast US components were significantly associated with malignancies ($p<0.05$, Table 1). Significant features include the mass shape, margin, orientation, calcification, architectural distortion, vascularization, and skin changes. Non-circumscribed margins, irregular masses, non-parallel masses, mass calcification, architectural distortion, skin thickening, and vascularization had the highest prevalence of malignancy. Posterior features, ductal changes, and echo patterns were not significantly associated with histopathological findings (Table 1).

Probability score

Multivariate analysis of margins had the highest aORs for malignancy (Table 2). To distinguish histopathological results, the selected characteristics were divided into risk factors (age) and imaging

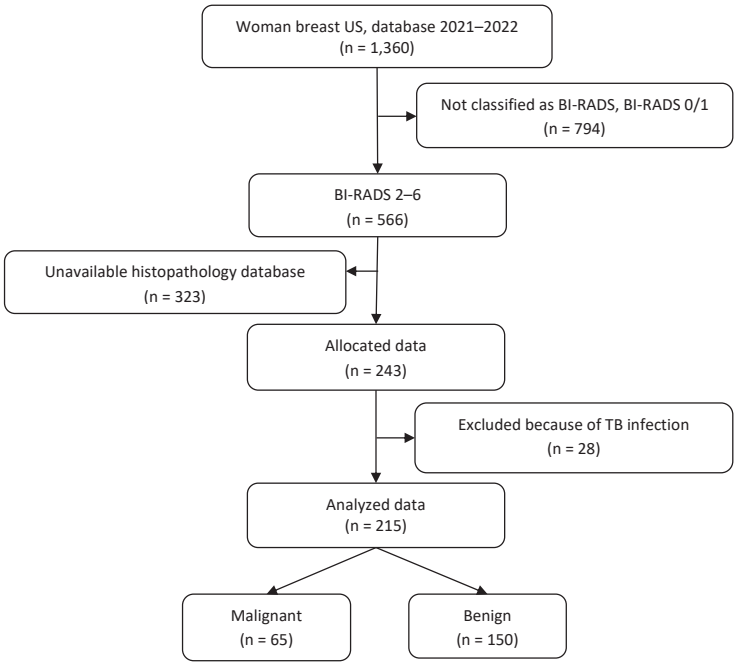

Figure 1. Study flow diagrams. BI-RADS=breast imaging reporting and data system; TB=tuberculosis; US=ultrasound

Table 1. Association and PR analysis of breast US characteristic and histopathological result

Variables	Histopathology result, n (%)		Total	*p**	PR (95% CI)
	Malignant (N = 65)	Benign (N = 150)			
Age (years)				**<0.001**	
≥40	53 (61.6)	33 (38.4)	86 (40.0)		6.62 (3.76–11.64)
<40	12 (9.3)	117 (90.7)	129 (60.0)		0.42 (0.32–0.55)
Shape				**<0.001**	
Irregular	42 (79.2)	11 (20.8)	53 (24.7)		5.58 (3.73–8.35)
Oval	23 (14.2)	139 (85.8)	162 (75.3)		0.24 (0.14–0.41)
Margin				**<0.001**	
Non-circumscribed	48 (85.7)	8 (14.3)	56 (26.0)		8.01 (5.05–12.72)
Circumscribed	17 (10.7)	142 (89.3)	159 (74.0)		0.16 (0.08–0.30)
Orientation				**<0.001**	
Non-parallel	23 (92.0)	2 (8.0)	25 (11.6)		4.16 (3.11–5.57)
Parallel	42 (22.1)	148 (77.9)	190 (88.4)		0.10 (0.02–0.38)
Calcification				**<0.001**	
In a mass	12 (100.0)	0 (0)	12 (5.6)		3.83 (3.03–4.89)
Absent	53 (26.1)	150 (73.9)	203 (94.4)		-
Architectural distortion				**0.002**	
Present	5 (100.0)	0 (0)	5 (2.3)		3.5 (2.82–4.33)
Absent	60 (28.6)	150 (71.4)	210 (97.7)		-
Vascularity				**0.037**	
In mass	40 (37.0)	68 (63.0)	108 (50.2)		1.58 (1.03–2.41)
Absent	25 (23.4)	82 (76.6)	107 (49.8)		0.82 (0.68–0.98)
Posterior features				0.152	
Shadowing	26 (36.6)	45 (63.4)	71 (33.0)		1.35 (0.90–2.03)
Absent	39 (27.1)	105 (72.9)	144 (67.0)		0.86 (0.71–1.06)

Table continued on next page

Table 1. (Continued)

Variables	Histopathology result, n (%)		Total	*p**	PR (95% CI)
	Malignant (N = 65)	Benign (N = 150)			
Skin changes				**0.028**	
Thickening	5 (71.4)	2 (28.6)	7 (3.3)		2.47 (1.48–4.14)
Normal	60 (28.8)	148 (71.2)	208 (96.7)		0.40 (0.12–1.30)
Ductus changes				0.726	
Dilated	2 (22.2)	7 (77.8)	9 (4.2)		0.72 (0.21–2.51)
Normal	63 (30.6)	143 (69.4)	206 (95.8)		1.12 (0.78–1.60)
Size (cm)				0.172	
≥2	44 (34.1)	85 (65.9)	129 (60.0)		1.39 (0.89–2.17)
<2	21 (24.4)	65 (75.6)	86 (40.0)		0.87 (0.73–1.03)
Echo patterns				0.804	
Anechoic	0 (0)	3 (100.0)	3 (1.4)		NA
Hypoechoic	58 (30.4)	133 (69.6)	191 (88.8)		NA
Hyperechoic	2 (50.0)	2 (50.0)	4 (1.9)		NA
Isoechoic	2 (50.0)	2 (50.0)	4 (1.9)		NA
Complex cyst and solid	0 (0)	6 (100.0)	6 (2.8)		NA
Heterogeneous	3 (42.9)	4 (57.1)	7 (3.3)		NA
BI-RADS classification				**<0.001**	
Malignant (4–6)	55 (70.5)	23 (29.5)	78 (36.3)		9.66 (5.22–17.84)
Benign (2–3)	10 (7.3)	127 (92.7)	137 (63.7)		0.31 (0.22–0.45)

BI-RADS=breast imaging reporting and data system; CI=confidence interval; NA=not available; PR=prevalence ratio; US=ultrasound
**p*-values were derived from the chi-square test or Fisher's exact test, as appropriate. Reference categories: oval (shape), circumscribed (margin), parallel (orientation), absent (calcification, vascularity, skin changes, and ductal changes), hypoechoic (echo pattern), size <2 cm, and age <40 years

Table 2. Logistic regression for histopathology-proven malignancy

Variables	*p*	aOR	95% CI (min–max)	Risk score
Margin	**<0.001**	39.86	13.19–120.47	3
Age	**<0.001**	9.74	3.51–27.04	1
Orientation	**0.004**	17.47	2.42–125.72	2

aOR=adjusted odds ratio; CI=confidence interval
Candidate variables from univariable screening ($p \leq 0.25$) included age, margin, orientation, size, vascularity, skin thickening, and shape. The final multivariable model (forward conditional) retained the margin, orientation, and age. Reference categories: circumscribed margin, parallel orientation, and age <40 years. No missing data were found for the variables in the final model

features (margin and orientation) based on the multivariate analysis. Each characteristic was assigned a risk score (1–3) based on the OR. A fitted probability of <50% was classified as benign, and >50% as malignant. In the benign group (score 0–2), the probabilities of malignancy were 3.07–35.54%. The malignant group (scores 3–6) showed the probabilities of malignancy were 55.82–99.53% (Table 3).

Validation test

This BI-RADS interpretation strategy showed a significantly higher specificity, PPV, and accuracy than the standard BI-RADS classification system (Table 4). The ROCs of the BI-RADS interpretation strategy and standard BI-RADS probabilities are shown in Figure 2. The AUC for the BI-RADS interpretation strategy was 0.931, indicating a high likelihood of correctly identifying malignant lesions. The standard error (SE) was 0.022, and the 95% CI was 0.888–0.973. The AUC for the standard BI-RADS classification was 0.873, the SE was 0.029, and the 95% CI was 0.816–0.930 (Table 4).

DISCUSSION

The ACR developed BI-RADS to standardize breast US interpretation and reduce diagnostic ambiguity.[10] The latest BI-RADS guidelines released in 2013 provide a detailed lexicon for assessing breast mass features.[11] The interpretation remains subjective for each radiologist, with no scoring system for borderline

Table 3. Predicted probability of histopathology-proven malignancy from multivariable logistic regression

Finding	Final score†	Probability (%)
Classification system		
Histopathology category*		
Benign (0–2)		
No suspicious imaging features and risk factor	0	3.07
Have risk factor and no imaging features	1	23.60
Non-parallel orientation and no risk factor	2	35.64
Malignant (3–6)		
Non-circumscribed margin and no risk factor	3	55.82
Non-parallel orientation and have risk factor	3	84.37
Non-circumscribed margin and have risk factor	4	95.67
Have risk factor and 2 imaging features	6	99.53

*Significance category. No missing data for variables in the final model; †final malignancy risk score was defined as the sum of individual risk factors and suspicious imaging features. Reference categories: circumscribed margin, parallel orientation, and age <40 years. Risk factor was age ≥40 years and imaging features were orientation and margin

findings. This study compared the standard BI-RADS classification with a BI-RADS interpretation strategy to address the challenges of classifying borderline masses.

This study demonstrates that the BI-RADS interpretation strategy is a viable alternative to the standard BI-RADS, with an AUC of 0.931, particularly in LMIC settings. Margin, orientation, and age were identified as the strongest predictors of malignancy and closely correlated with the histopathological results. Specifically, non-circumscribed margins, defined as irregular, indistinct, or spiculated borders, were most strongly associated with malignancy, consistent with the literature indicating that tissue retraction and fibrosis from desmoplastic reactions often cause irregular margins in malignant tumors.[12]

Non-parallel orientation, in which the vertical dimension exceeds the transverse dimension, is strongly associated with malignancy and is often observed in invasive cancers due to irregular tissue growth.[13] Additionally, previous studies have indicated that non-parallel orientation may serve as an effective prognostic marker for detecting small breast tumors with a higher likelihood of malignancy.[14] Patients ≥40 years were more likely to have malignant masses, consistent with previous studies showing age as a significant risk factor,[15] with 70.92% of neoplasms occurring in women ≥40 years.[16] Other US features, including mass shape, calcification, architectural distortion, and vascularity, were also indicative of malignancy but less predictive than margin, orientation, and age.

The BI-RADS interpretation strategy simplifies the process by focusing on easily memorable characteristics, such as margin, orientation, and age,[4] summing their scores to estimate malignancy probability, and categorizing lesions according to the BI-RADS. This approach improves the specificity, PPV, and accuracy compared to the standard BI-RADS system. In this study, the simplified BI-RADS interpretation strategy demonstrated a modest reduction in sensitivity compared with the standard BI-RADS assessment. The anticipated loss of sensitivity arises because the simplified system relies on fewer imaging features and omits the comprehensive hierarchy of descriptors used in standard BI-RADS decision-making. By focusing solely on the most significant predictors—margin, orientation, and age—the model inevitably forgoes some of the subtleties

Table 4. Diagnostic performance of two interpretation strategies *versus* histopathology

Examination method	Sensitivity	Specificity	Accuracy	PPV	NPV	AUC	95% CI (min–max)
Standard BI-RADS	84.6%	84.7%	84.7%	70.5%	92.7%	0.873	0.816–0.930
Scoring system (age, margin, and orientation)	78.5%	94.0%	89.3%	85.0%	91.0%	0.931	0.888–0.973

AUC=area under the curve; BI-RADS=breast imaging reporting and data system; CI=confidence interval; NPV=negative predictive value; PPV=positive predictive value

McNemar's test for paired proportions (sensitivity, specificity, PPV, and NPV) and DeLong's test for differences in AUC. Reference categories: circumscribed margin, parallel orientation, and age <40 years

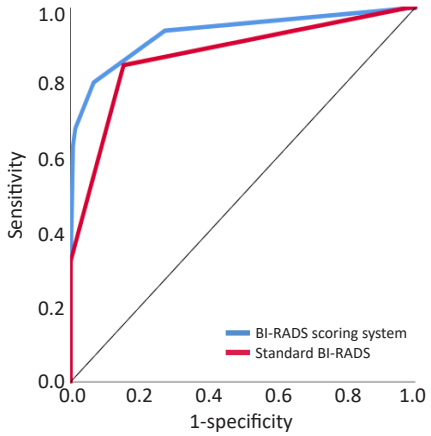

Figure 2. ROC curve. AUC of BI-RADS interpretation strategy (0.931) *versus* standard BI-RADS (0.873) for discriminating histopathology-proven malignancy. AUC=area under the curve; BI-RADS=breast imaging reporting and data system; ROC=receiver operating characteristic curve

required to identify a small subset of atypical malignancies. This tradeoff underscores the intrinsic balance between diagnostic precision and ease of operation. Although this strategy is generally effective at differentiating cases, clinicians should recognize that its simplified framework may occasionally lead to underclassification of early malignant lesions, particularly those that do not exhibit distinctly suspicious morphological features.

Sensitivity values reported in previous breast US studies have varied significantly, ranging from approximately 60% to more than 95%.[17–19] This variation reflects differences in study design, patient populations, operator expertise, imaging quality, and the specific BI-RADS criteria applied. Unlike previous studies that evaluated the standard BI-RADS lexicon, this study aimed to improve the accuracy of BI-RADS 3 and 4 classification by developing a simplified BI-RADS interpretation strategy. Moreover, many previous studies were conducted in high-resource environments with more standardized workflows or higher-resolution equipment. In contrast, this cohort included both outpatient and inpatient cases and was based on a pragmatic and real-world clinical workflow. These methodological differences may account for the discrepancies between our findings and those of the published literature.

However, the overall diagnostic efficacy remained strong, with the preservation of specificity and PPV, suggesting its potential utility in LMICs. Balancing the sensitivity and specificity is essential to avoid missing malignancies. The AUC for the interpretation strategy was 0.931, compared with 0.873 for the standard BI-RADS, indicating slightly improved diagnostic performance and supporting its use to minimize misclassification of borderline masses. The standard BI-RADS acts as a thorough clinical classification framework that combines a range of imaging findings to inform management strategies. The interpretation method was designed as a predictive model that highlights US features with the strongest discriminatory value. By focusing on the most informative predictors and diminishing the role of less significant features, the model enhances risk differentiation, thereby increasing the AUC.

One of the primary limitations of this study was its external validity. Although the BI-RADS interpretation strategy was examined in a specific environment, it is essential to specify the contexts in which the findings are applicable. This study involved symptomatic patients who presented with palpable breast lumps, representative of typical clinical procedures in a tertiary hospital located in an LMIC. US assessments were performed using standard clinical equipment widely available in routine practice, and interpretations were provided by radiologists with varying levels of expertise. These elements are crucial for understanding the generalizability of the results and should be considered when applying the scoring strategy to other LMICs. Moreover, the study did not address the current use of BI-RADS in the study setting, such as whether radiologists primarily use structured or unstructured reporting systems or incorporate local imaging guidelines. Understanding its practical implementation is essential to evaluate the feasibility and impact of adopting an interpretation strategy in a specific region.

This study had several other limitations. First, observer bias may have occurred due to the operator-dependent nature of US interpretation. Second, selection bias was inherent due to the study's retrospective design, which included only patients who underwent biopsies. Although verification and spectrum biases are less pertinent, given that all included lesions had histopathological confirmation and the population was limited to symptomatic patients with palpable breast lumps, these limitations should be considered when assessing the generalizability of our findings.

This study provides insights into the application of the BI-RADS for BC diagnosis, particularly in LMICs. The

BI-RADS interpretation strategy could be particularly beneficial for reducing inter-reader variability and supporting the standardized use of BI-RADS, especially in resource-limited settings. The simplicity and ease of use of this interpretation strategy make it an attractive tool for radiologists worldwide to classify borderline masses. For lesions with non-circumscribed margins, the probability of malignancy increased to 55%, placing them under the BI-RADS malignant classification (likelihood >2%).

This study offers important insights into the application of the BI-RADS in BC diagnosis, particularly in LMICs. The proposed BI-RADS interpretation strategy shows promise in improving borderline lesion classification through a simplified scoring system based on margin, orientation, and age, potentially enhancing diagnostic consistency in resource-limited settings. However, additional evidence is required to validate its effectiveness and support its integration into the standard BI-RADS. Future multicenter studies are required to assess the clinical utility, scalability, and practical implementation of this model. Furthermore, this study lacked detailed information on the current challenges radiologists face in these regions, including training opportunities, infrastructure, and healthcare policies. Addressing these factors is crucial for the successful adoption and integration of interpretation strategies. Future research should provide a clear, detailed rationale for modifying the BI-RADS interpretation strategy and validate its performance through comparative analyses using robust statistical methods and diverse datasets. Multicenter studies across different healthcare settings are needed to identify potential biases, and evaluations of the cost-effectiveness and scalability of implementing the BI-RADS interpretation strategy in LMICs are key to assessing its practical utility.

Conflict of Interest

The authors affirm no conflict interest in this study.

Acknowledgment

The authors would like to thank Sekar Hapsari Tunjungdewi, M.D. and Dwi Windi Juniarti, M.D for their contribution in reading the radiological results. We also express our gratitude to all the staff of Department of Radiology and Department of Anatomical Pathology, Ken Saras Hospital for their support in the creation this article.

Funding Sources

None.

REFERENCES

1. Sung H, Ferlay J, Siegel RL, Laversanne M, Soerjomataram I, Jemal A, et al. Global cancer statistics 2020: GLOBOCAN estimates of incidence and mortality worldwide for 36 cancers in 185 countries. CA Cancer J Clin. 2021;71(3):209–49.
2. Stewart KA, Navarro SM, Kambala S, Tan G, Poondla R, Lederman S, et al. Trends in ultrasound use in low and middle income countries: a systematic review. Int J MCH AIDS. 2020;9(1):103–20.
3. Sood R, Rositch AF, Shakoor D, Ambinder E, Pool KL, Pollack E, et al. Ultrasound for breast cancer detection globally: a systematic review and meta-analysis. J Glob Oncol. 2019;5:1–17.
4. Arian A, Dinas K, Pratilas GC, Alipour S. The breast imaging-reporting and data system (BI-RADS) made easy. Iran J Radiol. 2022;19(1):e121155.
5. Cui K, Liu W, Wang D. Interpretable diagnosis of breast lesions in ultrasound imaging using deep multi-stage reasoning. Phys Med Biol. 2024;69(21):215025.
6. Dariya S, Moses S, Verma S, Chaudhary P, Jain S. Evaluation of the association between breast imaging reporting and data system for ultrasonography (BIRADS) and histopathology in patients of lump nn breast: an obser-vational study. Arch Clin Exp Surg. 2022;11(5):1–7.
7. Mendelson EB. ACR BI-RADS® ultrasound. In: Mendelson EB, editor. ACR BI-RADS® Atlas— breast ultrasound. 5th ed. Reston: American College of Radiology; 2013.
8. Lam DL, Entezari P, Duggan C, Muyinda Z, Vasquez A, Huayanay J, et al. A phased approach to implementing the breast imaging reporting and data system (BI-RADS) in low-income and middle-income countries. Cancer. 2020;126 Suppl 10:2424–30.
9. Tan PH, Ellis I, Allison K, Brogi E, Fox SB, Lakhani S, et al. The 2019 World Health Organization classification of tumours of the breast. Histopathology. 2020;77(2):181–5.
10. D'Orsi CJ, Sickles EA, Mendelson EB, Morris EA. ACR BI-RADS® atlas, breast imaging reporting and data system. Reston: American College of Radiology; 2013.
11. Lee J. Practical and illustrated summary of updated BI-RADS for ultrasonography. Ultrasonography. 2017;36(1):71–81.
12. Barman G, Bujarbaruah K, Choudhury BK, Kataki AC. Ultrasound evaluation of biopsy proven malignant breast mass. Int J Res Med Sci. 2020;8(2):706–13.
13. Yang Y, Hu Y, Shen S, Jiang X, Gu R, Wang H, et al. A new nomogram for predicting the malignant diagnosis of breast imaging reporting and data system (BI-RADS) ultrasonography category 4A lesions in women with dense breast tissue in the diagnostic setting. Quant Imaging Med Surg. 2021;11(7):3005–17.
14. Shao S, Yao M, Li C, Li X, Wang J, Chen J, et al. Ultrasound features for prediction of long-term outcomes of women with primary breast cancer <20 mm. Front Oncol. 2023;13:1103397.
15. Jayadi T, Rustam BM, Kristi P, Dewi NC, Probowati W, Hariatmoko H, et al. The association between age groups with clinicopathologic and molecular subtypes of breast cancer patients. Smart Med J. 2022;5(2):93–6.
16. Alshamlan NA, AlOmar RS, Almukhadhib OY, Algarni SA, Alshaibani AK, Elmaki SA, et al. Characteristics of breast masses of female patients referred for diagnostic breast ultrasound from a Saudi primary health care setting. Int J Gen Med. 2021;14:755–63.
17. Nisar U, Anwar J, Ihsan HR, Yadain SH, Sultana SM, Khan M. Diagnostic accuracy of ultrasound BI-RADS in diagnosing breast lesions utilizing the core needle biopsy keeping histopathology as a gold standard. J Med Sci. 2022;30(04):275–9.
18. Khalid A, Mukhtar MA, Mukhtar A, Mukhtar R. High-resolution ultrasound in breast cancer diagnosis: sensitivity, specificity, and clinical implications. Cureus. 2025;17(7):e88641.
19. Aziz S, Mohamad MA, Md Zin RR. Histopathological correlation of breast carcinoma with breast imaging-reporting and data system. Malays J Med Sci. 2022;29(4):65–74.