Clinical Research

Inter- and intra-rater reliability of modified near-infrared camera to assess superficial lymphatic system in breast cancer-related lymphedema

Bayu Brahma[1,2], Prasandhya Astagiri Yusuf[3,4], Purnomo Sidi Priambodo[5], Kuntjoro Harimurti[6], Samuel Johny Haryono[2], Harlim[7], Suryadi[8], Mahesa Paskahenru[9], Rika Lesmana[10], Rumuat Semuel Wullul Manangka[11], Akmal Taher[12], Sonar Soni Panigoro[13]

Check for updates

pISSN: 0853-1773 • eISSN: 2252-8083
https://doi.org/10.13181/mji.oa.258234
Med J Indones. 2026;35:53–61

Received: June 01, 2025
Accepted: December 23, 2025
Published online: March 05, 2026

Authors' affiliations:
[1]Doctoral Program in Medical Sciences, Faculty of Medicine, Universitas Indonesia, Jakarta, Indonesia, [2]Department of Breast, Dharmais Cancer Hospital, Jakarta, Indonesia, [3]Department of Medical Physiology and Biophysics, Faculty of Medicine, Universitas Indonesia, Jakarta, Indonesia, [4]Medical Technology, Indonesian Medical Education and Research Institute (IMERI), Faculty of Medicine, Universitas Indonesia, Jakarta, Indonesia, [5]Department of Electrical Engineering, Faculty of Engineering, Universitas Indonesia, Jakarta, Indonesia, [6]Department of Internal Medicine, Faculty of Medicine, Universitas Indonesia, Cipto Mangunkusumo Hospital, Jakarta, Indonesia, [7]Harlim's Infrared and UV Photography, Jakarta, Indonesia, [8]Research Center for Photonics, National Research and Innovation Agency, South Tangerang, Indonesia, [9]Big Data Center, Indonesian Medical Education and Research Institute (IMERI), Faculty of Medicine, Universitas Indonesia, Jakarta, Indonesia, [10]Department of Surgery, Mayapada Hospital Jakarta Selatan, Jakarta, Indonesia, [11]Department of Radiology, Mayapada Hospital Jakarta Selatan, Jakarta, Indonesia, [12]Department of Urology, Faculty of Medicine, Universitas Indonesia, Cipto Mangunkusumo Hospital, Jakarta, Indonesia, [13]Department of Surgical Oncology, Faculty of Medicine, Universitas Indonesia, Cipto Mangunkusumo Hospital, Jakarta, Indonesia

Corresponding author:
Bayu Brahma
Department of Breast, Dharmais Cancer Hospital, Jalan Letjen S. Parman Kav. 84–86, Slipi, West Jakarta 11420, DK Jakarta, Indonesia
Tel/Fax: +62-21-5681570
E-mail: bbrahma@dharmais.co.id

ABSTRACT

BACKGROUND Near-infrared (NIR) fluorescence imaging is one of the most useful diagnostic methods for breast cancer-related lymphedema (BCRL). It utilizes indocyanine green (ICG) lymphography, which requires a commercial camera that is not widely available. This study aimed to qualitatively assess the reliability of the modified NIR camera in diagnosing BCRL.

METHODS This prospective cross-sectional study was conducted between December 2023 and December 2024 in breast cancer (BC) patients with BCRL. A commercial mirrorless digital camera was modified by incorporating an excitation light source and spectral filters to enable NIR imaging. To evaluate the camera reliability, intra- and inter-observer agreements were assessed using Kappa analysis. Three independent observers evaluated dermal backflow patterns of lymphatic flow: linear, splash, stardust, and diffuse patterns.

RESULTS 60 BC patients with BCRL resulting in 280 images were included. The mean (standard deviation) age was 54.7 (10.1) years and body mass index were 27.1 (4.5) kg/m^2. Most patients had stage IIA BC (40%) and stage IV ICG lymphography (38%). Intra-observer analysis showed observers 1 and 2 of had a Kappa of 1.00 (95% confidence interval [CI]: 1.00–1.00), while observer 3 had Kappa of 0.99 (95% CI: 0.97–1.00). Inter-observer analysis between observers 1 and 2 showed Kappa 1.00 (95% CI: 1.00–1.00), while observers 1–3 and 2–3 had Kappa of 0.99 (95% CI: 0.97–1.00). Observer 3 misinterpreted 3 linear as splash patterns.

CONCLUSIONS This study showed a high inter- and intra-observer agreements making it reliable for BCRL diagnosis.

KEYWORDS breast cancer-related lymphedema, fluorescence imaging, indocyanine green

Near-infrared (NIR) fluorescence imaging has emerged as one of the most promising diagnostic tools for assessing breast cancer-related lymphedema (BCRL), a significant complication affecting patients undergoing breast cancer (BC) treatment.[1,2] This technique requires both a fluorescent dye and compatible NIR camera. Among the available dyes, indocyanine green (ICG) lymphography is the most commonly used. ICG lymphography has demonstrated superior sensitivity compared to other diagnostic tools for BCRL, such as lymphoscintigraphy (LSG). ICG showed a 100% sensitivity compared to 62% for LSG. Other modalities, such as bioimpedance spectroscopy (BIS),

Copyright @ 2026 Authors. This is an open access article distributed under the terms of the Creative Commons Attribution-NonCommercial 4.0 International License (http://creativecommons.org/licenses/by-nc/4.0/), which permits unrestricted non-commercial use, distribution, and reproduction in any medium, provided the original author and source are properly cited. For commercial use of this work, please see our terms at https://mji.ui.ac.id/journal/index.php/mji/copyright.

have also shown higher false-negative rates than ICG.[3,4] Therefore, it is particularly effective in detecting early lymphatic changes.[5] However, conventional NIR imaging systems often rely on commercial-grade cameras, which are not prevalent.[6,7] Therefore, developing a more affordable, widely accessible, and reliable NIR camera system is essential for early detection of lymphedema.

NIR fluorescence imaging is crucial for dermal backflow (DB) pattern classification in lymphedema staging and for guiding clinical management decisions between conservative and surgical procedures.[8,9] Efforts directed toward modified NIR imaging set-ups using basic materials have been taken; however, these frequently suffer technical hindrances. Common issues include excessive excitation light requirements,[7] inappropriate excitation wavelengths outside the ideal NIR spectrum,[10] reliance on constant power sources,[7] and non-integrated components that compromise the portability and ease of use.[11]

We have previously developed a NIR imaging device to address these issues. This modified camera incorporates an light-emitting diode (LED)-based excitation light source and a dual-filter system, making it more energy-efficient and portable than conventional models. Quantitative evaluation using Bland–Altman analysis was also conducted, which yielded reliable fluorescence imaging results for visualizing lymphatic abnormalities.[12] However, to date, we have not conducted a qualitative assessment to determine its practicality in clinical settings, particularly in terms of intra- and inter-observer consistency. Therefore, this study aimed to analyze the NIR camera using Kappa analysis to ensure the reliability of the camera in diagnosing BCRL.

METHODS

Study design

This prospective cross-sectional study was conducted from December 2023 to December 2024 at Dharmais Cancer Hospital – National Cancer Center and the Indonesia Medical Education and Research Institute (IMERI), Faculty of Medicine, Universitas Indonesia.

Patients' recruitment

The study was approved by the Medical Research Ethics Committee of the Dharmais Cancer Hospital (No.: 226/KEPK/IX/2022). Written informed consent was obtained from all participants prior to enrollment. Eligible patients were consecutively recruited. The study considered cancer patients with BCRL who had undergone axillary lymph node dissection (ALND) and were diagnosed with stage I–III lymphedema, according to the International Society of Lymphology.[13] All inclusion and exclusion criteria were applied before enrollment, and no patients were excluded after enrollment. BC staging was determined based on the American Joint Committee on Cancer 8th edition staging system.[14] Patients with asthma, impaired renal function, iodine allergy, pregnancy, or breastfeeding status were excluded.

Component of modified NIR camera

Camera

The modified NIR camera used in this study has been officially patented under number IDS000009190. Its primarily comprised a Sony Alpha 6400 E-mount mirrorless digital camera (Sony, Japan) equipped with a Sony 35 mm F1.6 lens (Sony). The original device includes factory-installed filters, a low-pass filter and a hot mirror, along with a CMOS Exmor APS-C sensor (23.5 × 15.6 mm). The images were acquired in a dark room. The modified NIR camera was operated using ISO 5,000–65,000, shutter speed 1/50–1/200, and aperture f/0–f/3.5. This ensured a complete anatomical coverage of the upper extremities. For each patient, imaging frames were obtained to include the entire arm from the wrist crease to the antecubital fossa, the antecubital fossa to the shoulder apex, and the intermediate segments between these regions. The camera-to-patient distance was adjusted according to arm length to capture the target segment within a single frame, with shorter arms imaged at a closer distance and longer arms at a proportionally greater distance.

Excitation light

To adapt the camera to NIR imaging, an excitation light source was integrated. The excitation source consisted of seven infrared LEDs (LC-3IR3-G42; LCFOCUS, China) arranged in series, operating at 2–2.2 V with a nominal operating current of approximately 700 mA per LED and wavelength of 760–780 nm. The LEDs are affixed to the camera body. The system was powered by four rechargeable lithium-based batteries, providing a total operating voltage of 12.8–16 V with 500 mAh battery. Under continuous operation, the

power supply provided an approximate runtime of 2 hours, which was sufficient for a complete imaging session.

Spectral filtering

For the detection of NIR emissions, the pre-installed low-pass and hot mirror filters (400–650 nm range) were removed, allowing the camera sensor to detect wavelengths from 360 to 900 nm. Two 2 mm thick RG850 longpass filters (Edmund Optics, USA) were installed, one in front and one behind the lens (Figure 1).

ICG lymphography examination

Patient recruitment

Patients were recruited between October 2022 and August 2023. ICG lymphography formed a part of the clinical assessment within 1 month of the patient enrollment. Thus, the recruitment and imaging windows overlapped at individual patient level.

Patient preparation and ICG lymphography assessment

ICG lymphography was performed to detect lymphatic abnormalities, as described previously.[15] Briefly, ICG dye (Premix Indocyanine Green USP 0.5% developed by Dharmais National Cancer Hospital) at a concentration of 5 mg/ml, with 0.1 ml per injection site, was injected intradermally into the second and fourth web spaces of the hand and wrist joint around the palmaris longus. Images were captured using a modified camera at two time points: 5 min and 2 hours post-injection. Complete ICG lymphography was performed in a dedicated darkened examination room in an outpatient clinical setting. The examinations and image acquisition were done by a trained general practitioner who was not involved in image interpretation.

The resulting lymphatic drainage patterns were classified using ICG lymphography stage as follows: stage 0, linear pattern only; stage I, linear pattern and splash pattern; stage II, linear pattern and stardust/diffuse pattern in one region; stage III, linear pattern and stardust/diffuse pattern in two regions; stage IV, linear pattern and stardust/diffuse pattern in three regions; and stage V, stardust and/or diffuse pattern. Although all ICG lymphography stages were recorded, the final assessment focused solely on classifying the images into four DB patterns: linear, splash, stardust, and diffuse.[16]

Qualitative analysis

Intra- and inter-observer agreements were performed to analyze the DB pattern of lymphatic flow using the modified NIR camera. Lymphatic images were obtained by a separate team that did not participate in the observation process. This analysis was performed by three observers, comprising a surgical oncologist (BB) as observer 1, a general surgeon (RL) as observer 2, and a radiologist (RS) as observer 3, possessing comparable competence, fostered by standardized training. This used at least 100 reference image sets per DB pattern (400 images in total) prior to the study. We used the labeling features of the Big Data Center IMERI (Faculty of Medicine, Universitas Indonesia, https://bdc-imeri-idealab.ui.ac.id/) for image analysis and randomization. The labelled images were uploaded to the Big Data Center IMERI and a dataset was created for each observer. Three different sets of images consisting of the same images were provided to the observers. All observers reviewed the images using standard clinical monitors under controlled ambient lighting conditions, with identical display settings applied across reading sessions. Participants were instructed to identify each image in a multiple-choice format (Figure 2). Potential sources of bias were addressed through consecutive recruitment to minimize selection and spectrum biases. To reduce unit-of-analysis bias, an equal number of images per DB pattern were analyzed independently. Patient identity and clinical information remained anonymous to observers. An independent team performed image acquisition and labeling. Learning and recall effects were minimized through standardized observer training and a predefined washout period (3 weeks) between repeated reading sessions. The results were subsequently analyzed using pairwise and multi-rater agreements.

Outcomes

The primary outcome of this study was the inter- and intra-observer agreements in DB pattern classification using the modified NIR camera. The collected variables included patient demographics, clinical characteristics, ICG lymphography stage, DB pattern classification, and repeated readings for the reliability analysis.

Statistical analysis

Categorical variables are presented as n (%). Numerical variables were tested for normality using the

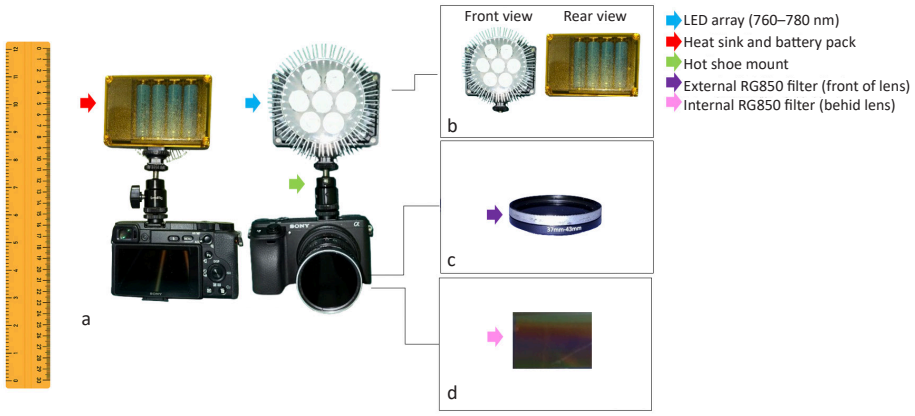

Figure 1. Components and assembly of a modified NIR camera for ICG lymphography. (a) Camera body (Sony α6400) with 35-mm f/1.8 lens; left, rear view with the LED array mounted on the hot shoe; right, front view with the screw-on external longpass filter; (b) seven-LED excitation array (λ ≈ 760–780 nm) with battery pack; front (left) and rear (right) views; (c) external longpass filter (RG850, 2 mm thick; 43 mm) used to block visible light and pass >850 nm emission; (d) internal longpass filter (RG850, 2 mm) installed behind the lens after removal of the factory lowpass hot mirror filter. ICG=indocyanine green; LED=light-emitting diode; NIR=near-infrared

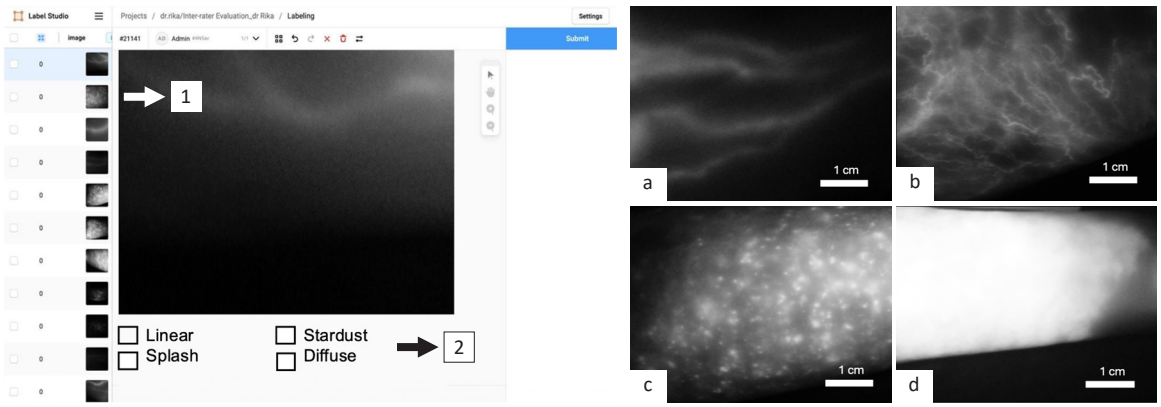

Figure 2. Examples of DB patterns on ICG NIR lymphography and the labeling interface used for the reader study. (a) Linear; (b) splash; (c) stardust; (d) diffuse, each images taken 2 hours after injection. Screenshots illustrate the annotation platform: arrows denote 1) the image dataset navigator and 2) the single-choice response options. Scale bars = 1 cm. Images are de-identified; brightness/contrast were uniformly adjusted. DB=dermal backflow; ICG=indocyanine green; NIR=near-infrared

Kolmogorov–Smirnov or Shapiro–Wilk tests. If normally distributed, data were presented as mean (standard deviation [SD]), otherwise median (interquartile range) was used.

Cohen's and Fleiss's Kappa analyses were conducted on the following lymphatic pattern images: linear, splash, stardust, and diffuse. Intra-rater reliability was assessed using Cohen's κ between the first and second readings for each observer. Inter-rater agreement was determined via pairwise Cohen's κ for all observer combinations, with Fleiss's κ used to calculate the overall agreement among the three observers. DB patterns were treated as nominal variables; therefore, unweighted κ statistics were applied to assess agreement. Percent agreement was reported alongside κ values, and there were no missing data. Images were randomized and analyzed independently at the image level; however, clustering by patient was not explicitly modeled. Given the primary aim of assessing overall reliability, no formal sensitivity analyses were pre-specified or performed.[17–19]

Kappa values were interpreted according to the standard agreement thresholds: values less than 0.00 indicate poor agreement; 0.00–0.20 slight agreement; 0.21–0.40 fair agreement; 0.41–0.60 moderate agreement; 0.61–0.80 substantial agreement; and 0.81–1.00 almost perfect agreement.[17–19] Statistical analyses were performed using SPSS software version

27.0 (IBM Corp., USA), with results reported alongside 95% confidence intervals (CI).

The minimum sample size for each DB pattern was determined based on a Kappa reliability analysis, assuming a minimum Kappa value of 0.8, a discordant proportion of 0.2, a precision of 0.2 at a 5% significance level.[20] Based on these parameters, a minimum of 30 images per DB pattern (120 total images) was required provide sufficient statistical power to assess inter- and intra-observer agreements.

RESULTS

Patient characteristics

Of 63 patients screened and assessed for eligibility, three were excluded prior to enrollment due to asthma (n = 1) or pregnancy (n = 2). The remaining 60 patients provided informed consent and underwent ICG NIR lymphography. This yielded 280 images (70 per DB pattern), exceeding the minimum sample size requirement. All images met the predefined quality criteria; therefore, none were excluded based on image quality. All enrolled patients and their respective images were included in the final qualitative analysis. All enrolled patients and images were included in the final qualitative analysis (Figure 3).

Table 1 showed the mean (SD) age was 54.7 (10.1) years and body mass index were 27.1 (4.5) kg/m^2. The majority of patients presented with stage IIA (40%) or IIIB (27%) BC. Regarding surgical intervention, mastectomy was performed in 50 (83%) patients,

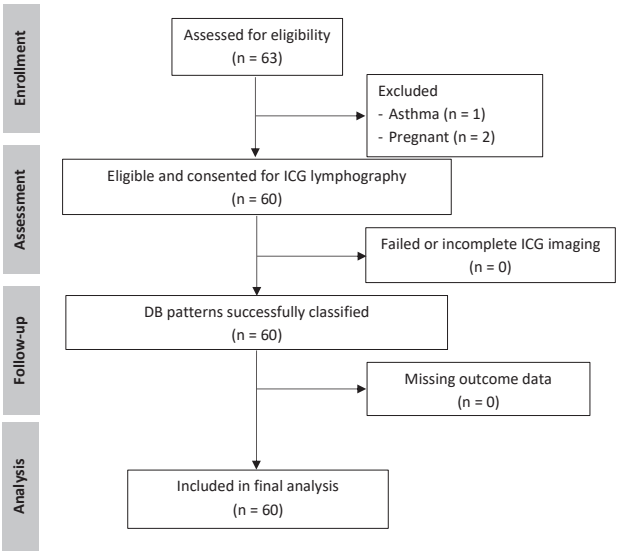

Figure 3. Flow diagram of patient enrollment. DB=dermal backflow; ICG=indocyanine green

Table 1. Patients characteristics

Variables	N = 60
Age (years), mean (SD)	54.7 (10.1)
BMI (kg/m^2), mean (SD)	27.1 (4.5)
BC stage, n (%)	
IA	1 (2)
IB	0 (0)
IIA	24 (40)
IIB	9 (15)
IIIA	8 (13)
IIIB	16 (27)
IIIC	0 (0)
IV	2 (3)
Types of surgery, n (%)	
Mastectomy	50 (83)
BCS	10 (17)
Radiotherapy, n (%)	41 (68)
Chemotherapy, n (%)	43 (72)
Hormonal, n (%)	34 (57)
ICG lymphography stage in all patients, n (%)	
I	1 (2)
II	10 (17)
III	19 (32)
IV	23 (38)
V	7 (12)
ICG lymphography stage in BCS (n = 10), n (%)	
I	0 (0)
II	3 (30)
III	2 (20)
IV	3 (30)
V	2 (20)
ICG lymphography stage in mastectomy (n = 50), n (%)	
I	1 (2)
II	7 (14)
III	17 (34)
IV	20 (40)
V	5 (10)

BMI=body mass index; BC=breast cancer; BCS=breast-conserving surgery; ICG=indocyanine green; SD=standard deviation

while 10 (17%) underwent breast-conserving surgery. Radiotherapy, chemotherapy, and hormonal therapy were received by 41 (68%), 43 (72%), and 34 (57%) patients, respectively. According to ICG lymphography, the most prevalent BCRL classification was stage IV (n = 23 [38%]), a trend that remained consistent regardless

Table 2. Reader agreement for DB pattern classification on ICG NIR lymphography: intra- and inter-rater, overall Fleiss's κ shown

Reader agreement	κ	95% CI	Percent agreement (%)
Intra-observer agreement			
Observer			
Observer 1	1.00*	1.00–1.00	100
Observer 2	1.00*	1.00–1.00	100
Observer 3	0.99*	0.97–1.00	98.9
Inter-observer agreement			
Observer			
1 vs. 2	1.00*	1.00–1.00	100
1 vs. 3	0.99*	0.97–1.00	98.9
2 vs. 3	0.99*	0.97–1.00	98.9
Overall inter-observer agreement (3 raters)			
Reading			
Read 1	1.00†	1.00–1.00	-
Read 2	0.99†	0.97–1.00	-

CI=confidence interval; DB=dermal backflow; ICG=indocyanine green; NIR=near-infrared
*κ (Cohen's); †κ (Fleiss's)

of the type of breast surgery performed. All variables included in the analysis were complete, with no missing data.

Kappa analysis

Kappa coefficients were calculated to evaluate the intra- and inter-observer agreements for the classification of DB patterns. As shown in Table 2, observers 1 and 2 showed perfect intra-observer agreement (Cohen's κ = 1.00; 95% CI: 1.00–1.00; 100% agreement), whereas observer 3 showed near-perfect agreement (κ = 0.99; 95% CI: 0.97–1.00; 98.9% agreement), with three linear patterns misclassified as splash patters during the second assessment (Figure 4).

Inter-observer analysis demonstrated perfect agreement between observers 1 and 2 (κ = 1.00; 95% CI: 1.00–1.00; 100% agreement), whereas comparisons involving observer 3 (1 *versus* 3 and 2 *versus* 3) showed near-perfect agreement (κ = 0.99; 95% CI: 0.97–1.00; 98.9% agreement). Overall the three-rater agreement, assessed using Fleiss's κ, was 1.00 for the first reading and 0.99 for the second reading.

DISCUSSION

This study demonstrates that the modified NIR camera is a reliable tool for diagnosing DB patterns in patients with BCRL, as evidenced by the high intra- and inter-observer agreements (Kappa 0.98 to 1.00). To date, limited research has evaluated the reliability of NIR cameras in this context. Schmidt et al[21] used NIR fluorescence imaging to examine the head and neck cancer epithelium *in vivo*; however, that study employed a commercially available NIR camera, which demonstrated high inter-observer reliability (Kappa value of 0.94). In the context of BCRL assessment, a relevant study by Jørgensen et al[20] utilizing another commercially available system also reported almost perfect intra- and inter-observer agreements among three observers. While these previous studies utilized commercial NIR camera systems, our study establishes that our modified NIR camera achieved reliability comparable to established systems, supporting its utility in the early detection of BCRL.

The inter- and intra-rater κ values observed in this study are comparable to, though marginally higher

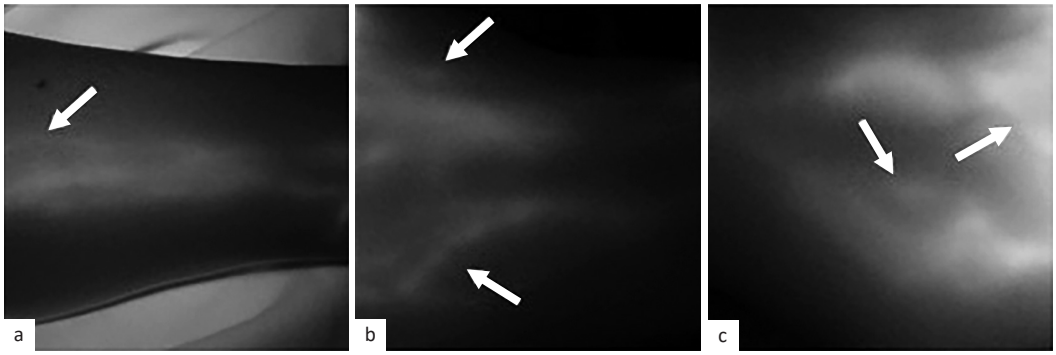

Figure 4. Examples of observer disagreement. (a–c) Three images that the reference/consensus label classified as linear dermal-backflow (DB) pattern, but observer 3 classified as splash on the second read. Arrows indicate regions supporting the consensus linear interpretation. Scale bars = 1 cm. Images are de-identified; brightness/contrast were uniformly adjusted

than, those reported in prior NIR fluorescence imaging studies, such as Schmidt et al[21] and Jørgensen et al[20]. Several methodological factors likely account for this discrepancy. First, our reliability dataset utilized a balanced distribution across DB patterns; this approach is known to yield more robust κ estimates compared to real-world settings, where certain patterns predominate. Second, all readings were performed by trained clinicians using standardized pattern definitions. Variability in reader expertise and calibration across different studies may account for lower agreement.[20]

Third, image acquisition timing varied between studies. Prior reports have primarily assessed early post-injection fluorescence dynamics, whereas our protocol utilized standardized delayed lymphographic imaging. This delay may enhance the delineation of DB patterns and reduce interpretative ambiguity. Finally, technical specifications, including excitation wavelength, filtering, sensor characteristics, exposure settings, and standardized monitor viewing conditions, can influence pattern conspicuity and subsequent agreement. Collectively, these factors provide a plausible explanation for the modestly higher κ values observed in this study, which remains clinically consistent with the existing literature.

These findings revealed instances of differences specially involving the third observer, who identified three linear patterns as splash patterns. This may have been attributed to the presence of image noise. Specifically, noise within a linear pattern may be interpreted as a splash, which represents the dilation of the pre-collector lymphatic vessels and capillaries.[22] In addition, the sample size of images used for training and analysis in this study may have been limited. To minimize errors and reduce variability, it is generally recommended that observers receive standardized training in image interpretation, a protocol that we implemented.[23] Notably, a previous inter-rater study on ICG[23] included a significantly larger number of images.

This study incorporated several measures to strengthen internal validity. First, all images were assessed in a blinded manner; readers remained anonymized to patient identity, clinical information, and the evaluation of other observers. The order of images was randomized for each reading session, and repeat readings were conducted with a predefined washout interval to mitigate recall bias. Furthermore, standardized image acquisition and uniform viewing conditions were maintained to reduce information bias and ensure consistency across assessments.

Regarding external validity, this study was conducted at a single tertiary center, and image interpretation was restricted to specialist clinicians experienced in lymphatic imaging. Consequently, these findings may not be fully generalizable to broader clinical settings. In addition, image acquisition and interpretation were performed under controlled environmental variables, such as standardized ambient lighting and calibrated monitor conditions, which may differ from routine clinical practice. These factors should be considered when extrapolating the findings; therefore, future multicenter studies, encompassing readers with varied levels of expertise and real-world acquisition conditions, are warranted to further validate these results.

In this study, approximately 20% of BCRL cases were classified as early-stage lymphedema based on ICG lymphography staging.[16] This finding underscores the capacity of the camera to detect BCRL in its early stages, which is critical for enabling early diagnosis and timely intervention. The ability to identify early BCRL is particularly important, as proactive intervention at this stage can prevent further disease progression.[5] Currently, several methods are available for BCRL diagnosis, including limb circumference measurements, BIS, LSG, and perometry.[24] However, ICG lymphography has emerged as one of the most sensitive techniques[3,4] for detecting lymphedema prior to clinical manifestation.[25] In ICG lymphography, the use of a handheld NIR camera allows direct and real-time visualization of the anatomy and function of superficial lymphatic vessels from all directions, especially during lymphatic surgery. In contrast, images from LSG can only be viewed in the anteroposterior direction.[7,26] Therefore, ICG lymphography represents a highly effective diagnostic tool, particularly for screening purposes.

Numerous studies have established the utility of ICG lymphography in assessing BCRL, reinforcing its clinical relevance.[15,16] Hence, in resource-constrained settings such as Indonesia, the development of an accessible NIR camera is crucial. Moreover, in regions with a high prevalence of locally advanced BC, as seen in our population,[27] the frequent necessity of ALND significantly increases the risk of BCRL.[28] Therefore, effective screening and early detection tools are urgently needed. This camera provides a

robust and practical solution that is locally developed, cost-effective, and sufficiently reliable for clinical applications. We envision that this technology could be widely adopted across hospitals facing similar issues in clinical settings, thereby promoting equitable access to high-quality lymphedema care and improving patient outcomes nationwide.

A primary limitation of this study was the absence of a comparison with a gold standard diagnostic tool, which precluded an assessment of the device's diagnostic accuracy. However, this study was designed specifically to evaluate inter- and intra-observer reliability rather than diagnostic performance. Second, the acquisition of multiple images from individual patients introduced potential clustering effects. This could inflate agreement estimates, despite applying standardized sampling. Moreover, this study focused on the classification of specific lymphatic patterns rather than utilizing the ICG lymphography staging system, which is more suitable for full BCRL diagnosis.[16] Finally, the single-center study design and interpretation by specialist readers may restrict its generalizability to non-expert users or diverse clinical settings.

Despite these limitations, the near-perfect inter- and intra-rater agreements indicates that the modified NIR camera provides consistent data to support BCRL assessments, particularly in settings where commercial NIR systems are inaccessible. High reader reliability suggests that the platform is well-suited for training, early detection, and referral decision-making, where consistent pattern recognition is essential. This is especially relevant in resource-constrained environments, where access to standardized NIR imaging remains limited. Future studies should prioritize multicenter diagnostic studies comparing the modified camera against commercial NIR devices. Additionally, the incorporation of hierarchical or mixed-effects models to account for within-patient clustering, and the expansion from pattern-based assessment to full ICG lymphography staging, are warranted. Performance of non-specialist readers after structured training must also be evaluated for scalability and real-world applicability. These steps will clarify diagnostic performance and strengthen its external validity.

Based on these findings, we posit that the modified NIR camera holds a significant potential for clinical applications beyond lymphedema imaging extending into other fields, such as cancer, digestive, plastic, urology, thoracic, gynecology, reconstructive, and cardiovascular surgeries. Furthermore, it can be integrated into laparoscopic cholecystectomy, assess bowel perfusion in colectomy, guide segmental resection lines in thoracic surgery, and delineate fibroid margins during robotic myomectomy.[29,30] Sentinel lymph node biopsy (SLNB) plays an important role in axillary staging during cancer surgery. Currently, SLNB uses methylene blue dye owing to the unavailability of radioisotopes.[31] We hope to improve the accuracy of SLNB using NIR fluorescence imaging. Furthermore, we are currently developing protocols for immediate lymphatic reconstruction[15,32] that require precise lymphatic mapping of the arm. The modified NIR camera may enable the visualization of disrupted lymphatic vessels during ALND, facilitating immediate lymphatic reconstruction.

Beyond lymphatic imaging, this technology may also be applicable in other medical fields such as blood perfusion of tissues,[6] measurement of liver function,[33,34] patency of vascular anastomosis, retinal angiography, renal blood flow, and cardiac output.[29,33,35] Therefore, we anticipate that the modified NIR camera will be further developed for use in other clinical settings, particularly in regions or specialties in which access to commercial NIR fluorescence imaging systems is limited. In conclusion, utilizing basic NIR fluorescence imaging technology, the modified NIR camera demonstrated high reliability for detecting lymphatic abnormalities. Therefore, its use is recommended for diagnosing BCRL. Further diagnostic studies and noise-reduction refinements are required to broaden its clinical applications.

Conflict of Interest

The authors affirm no conflict of interest in this study.

Acknowledgment

The author would like to thank Muhamad Faza Soelaeman MD and Adhitya Bayu Perdana for their encouragement and support on this project, especially for manuscript preparation.

Funding Sources

Financial support for this work was provided by the Islamic Development Bank, grant number IDN 1031.

REFERENCES

1. Brahma B, Putri RI, Reuwpassa JO, Tuti Y, Alifian MF, Sofyan RF, et al. Lymphaticovenular anastomosis in breast cancer treatment-related lymphedema: a short-term clinicopathological analysis from Indonesia. J Reconstr Microsurg. 2021;37(8):643–54.
2. Jørgensen MG, Toyserkani NM, Hansen FG, Bygum A, Sørensen JA. The impact of lymphedema on health-related quality of life up to 10 years after breast cancer treatment. NPJ Breast Cancer. 2021;7(1):70.

3. Qin ES, Bowen MJ, Chen WF. Diagnostic accuracy of bioimpedance spectroscopy in patients with lymphedema: a retrospective cohort analysis. J Plast Reconstr Aesthet Surg. 2018;71(7):1041–50.
4. Figueroa BA, Lammers JD, Al-Malak M, Pandey S, Chen WF. Lymphoscintigraphy versus indocyanine green lymphography—which should be the gold standard for lymphedema imaging? Lymphatics. 2023;1:25–33.
5. Akita S, Nakamura R, Yamamoto N, Tokumoto H, Ishigaki T, Yamaji Y, et al. Early detection of lymphatic disorder and treatment for lymphedema following breast cancer. Plast Reconstr Surg. 2016;138(2):192e–202e.
6. Yang H, Kim J, Nam W, Kim HJ, Cha IH, Kim D. Handheld near-infrared fluorescence imaging device using modified action cameras for peri-operative guidance of microvascular flap surgery. J Clin Med. 2021;10(3):410.
7. Kwizera A, Obaid A, Tran D, Rubarth C, Preskitt JT. Use of indocyanine green for sentinel lymph node biopsy in melanoma. Proc (Bayl Univ Med Cent). 2022;36(2):201–4.
8. Pollmann L, Juratli M, Roushansarai N, Pascher A, Hölzen JP. Quantification of indocyanine green fluorescence imaging in general, visceral and transplant surgery. J Clin Med. 2023;12(10):3550.
9. Muraleedharan S, Tripathy K. Indocyanine green (ICG) angiography [Internet]. In: StatPearls. Treasure Island: StatPearls Publishing; 2025 [Updated 2023 Aug 25]. Available from: https://www.ncbi.nlm.nih.gov/books/NBK580479/.
10. Aleksandrovich SA, Nikolaevich MD. Device for studying the level of blood flow and lymph flow. Russia; RU221600U1, 2023. p. 1–6.
11. Bertani C, Cassinotti E, Della Porta M, Pagani M, Boni L, Baldari L. Indocyanine green—a potential to explore: narrative review. Ann Laparosc Endosc Surg. 2022;7:9.
12. Brahma B, Priambodo P, Harlim H, Suryadi S, Panigoro SS, Yamamoto T, et al. 104P quantification analysis of low-cost near infrared camera for breast cancer treatment-related lymphedema fluorescence imaging. ESMO Open. 2024;9:103175.
13. Executive Committee of the International Society of Lymphology. The diagnosis and treatment of peripheral lymphedema: 2020 Consensus Document of the International Society of Lymphology. Lymphology. 2020;53(1):3–19.
14. Amin MB, Greene FL, Edge SB, Compton CC, Gershenwald JE, Brookland RK, et al. The eighth edition AJCC cancer staging manual: continuing to build a bridge from a population-based to a more "personalized" approach to cancer staging. CA Cancer J Clin. 2017;67(2):93–9.
15. Brahma B, Yamamoto T, Panigoro SS, Haryono SJ, Yusuf PA, Priambodo PS, et al. Supermicrosurgery lymphaticovenous and lymphaticolymphatic anastomosis: technical detail and short-term follow-up for immediate lymphatic reconstruction in breast cancer treatment-related lymphedema prevention. J Vasc Surg Venous Lymphat Disord. 2024;12(4):101863.
16. Yamamoto T, Yamamoto N, Kageyama T, Sakai H, Fuse Y, Tsuihiji K, et al. Technical pearls in lymphatic supermicrosurgery. Glob Health Med. 2020;2(1):29–32.
17. Wang F, Wan H, Ma Z, Zhong Y, Sun Q, Tian Y, et al. Light-sheet microscopy in the near-infrared II window. Nat Methods. 2019;16(6):545–52.
18. Li C, Chen G, Zhang Y, Wu F, Wang Q. Advanced fluorescence imaging technology in the near-infrared-ii window for biomedical applications. J Am Chem Soc. 2020;142(35):14789–804.
19. Gisev N, Bell JS, Chen TF. Interrater agreement and interrater reliability: key concepts, approaches, and applications. Res Social Adm Pharm. 2013;9(3):330–8.
20. Jørgensen MG, Toyserkani NM, Hansen FC, Thomsen JB, Sørensen JA. Prospective validation of indocyanine green lymphangiography staging of breast cancer-related lymphedema. Cancers (Basel). 2021;13(7):1540.
21. Schmidt F, Dittberner A, Koscielny S, Petersen I, Guntinas-Lichius O. Feasibility of real-time near-infrared indocyanine green fluorescence endoscopy for the evaluation of mucosal head and neck lesions. Head Neck. 2017;39(2):234–40.
22. Gençay Can A, Ekşioğlu E, Çakçı FA. Early detection and treatment of subclinical lymphedema in patients with breast cancer. Lymphat Res Biol. 2019;17(3):368–73.
23. Li M, Gao Q, Yu T. Kappa statistic considerations in evaluating inter-rater reliability between two raters: which, when and context matters. BMC Cancer. 2023;23:799.
24. Ciudad P, Escandón JM, Bustos VP, Manrique OJ, Kaciulyte J. Primary prevention of cancer-related lymphedema using preventive lymphatic surgery: systematic review and meta-analysis. Indian J Plast Surg. 2022;55(1):18–25.
25. Liu M, Liu S, Zhao Q, Cui Y, Chen J, Wang S. Using the indocyanine green (ICG) lymphography to screen breast cancer patients at high risk for lymphedema. Diagnostics (Basel). 2022;12(4):983.
26. Brezgyte G, Mills M, van Zanten M, Gordon K, Mortimer PS, Ostergaard P. A systematic review of indocyanine green lymphography imaging for the diagnosis of primary lymphoedema. Br J Radiol. 2025;98(1168):517–26.
27. Setyawan IB, Kurnia D, Setiaji K, Anwar SL, Purwanto DJ, Azhar Y, et al. Sociodemographic disparities associated with advanced stages and distant metastatic breast cancers at diagnosis in Indonesia: a cross-sectional study. Ann Med Surg (Lond). 2023;85(9):4211–7.
28. McDuff SG, Mina AI, Brunelle CL, Salama L, Warren LE, Abouegylah M, et al. Timing of lymphedema after treatment for breast cancer: when are patients most at risk? Int J Radiat Oncol Biol Phys. 2019;103(1):62–70.
29. Lu CH, Hsiao JK. Indocyanine green. Tzu Chi Med J. 2021;33:317–22.
30. Rius M, Moawad G. New role of indocyanine green (ICG) in benign gynecology surgery. J Minim Invasive Gynecol. 2023;30(11):S58–9.
31. Brahma B, Putri RI, Sari L, Karsono R, Purwanto DJ, Gautama W, et al. The application of 1% methylene blue dye as a single technique in breast cancer sentinel node biopsy. J Vis Exp. 2019;(148).
32. Brahma B, Yamamoto T, Agdelina C, Adella D, Putri RI, Hanifah W, et al. Immediate-delayed lymphatic reconstruction after axillary lymph nodes dissection for locally advanced breast cancer-related lymphedema prevention: report of two cases. Microsurgery. 2024;44(2):e31033.
33. Fransvea P, Miccini M, Rondelli F, Brisinda G, Costa A, Garbarino GM, et al. A green lantern for the surgeon: a review on the use of indocyanine green (ICG) in minimally invasive surgery. J Clin Med. 2024;13(16):4895.
34. Chen Y, Liu G, Wu Y, Cai H. Assessment of liver injury using indocyanine green fluorescence imaging. Ann Transl Med. 2021;9(14):1167.
35. Liu YF, Liu JE, Zhu Y, Mak YW, Qiu H, Liu LH, et al. Development and validation of a nomogram to predict the risk of breast cancer-related lymphedema among Chinese breast cancer survivors. Support Care Cancer. 2021;29(9):5435–45.