

Fusion of teeth – A rare developmental anomaly

James SUNNY ¹, Vishwanath KEDILAYA ¹, Ravindra PAI ¹, Dharma Sindhu RAI ¹, Murali RAO ²

¹ Dental Department, Jerudong Medical Park Centre, Brunei Darussalam and

² Dental Division, Panaga Health Centre, Brunei Darussalam

ABSTRACT

Fusion is a rare developmental problem involving the union of two adjacent teeth. This occurs with a prevalence of 0.05% (bilateral) and could cause aesthetic, spacing and periodontal problems. The aetiology related to such an anomaly is still uncertain. The present article reports two rare cases with fusion of the mandibular permanent lateral incisors with the canine. The possible treatment options are also discussed.

Keywords: Dental anomalies, fusion, gemination

INTRODUCTION

Fusion is a developmental anomaly which occurs due to the union of one or more adjacent teeth during the developmental process. ^{1, 2} They are joined by the dentine; pulp chambers and canals may be fused or separated depending on the developmental stage when union occurs. If the fused tooth is counted as one unit, there will be one less tooth in the arch than normal.

The aetiology related to this anomaly is still uncertain, but the influence of pressure or physical forces producing close contact between two developing teeth has been suggested as one possible cause. ³ Other factors listed include genetic predisposition, racial

differences, disease or trauma. ⁴ The prevalence of fusion in permanent dentition is approximately 0.2%. ⁵ Cases of bilateral fusion are less frequent than unilateral fusion and are reported to be only 0.05%. ⁶ Most fused teeth are seen in the anterior region compared to the premolar-molar areas. ⁷ When fusion occurs in the anterior region, this anomaly causes an aesthetically displeasing tooth shape due to the irregular morphology. ^{8, 9} Another anomaly very often confused with fusion is 'gemination'. Gemination is recognised as an attempt by a single tooth germ to divide, with a resultant large single tooth with bifid crown. Also, the normal number of teeth is found, if the affected tooth is counted as one. ¹⁰

Correspondence author: James SUNNY
Dental Department,
Jerudong Park Medical Centre (JPMC), Jerudong,
Brunei Darussalam.
Tel: +673 2611433 Ext 2229
E mail: jimorth@gmail.com

This article reports two unusual cases of fusion of the permanent mandibular lateral incisors with the canine. The clinical implica-

tion and treatment methods are also discussed.

CASE REPORT

Case 1: A healthy 14-year-old Malay female was seen at the dental department in our hospital for an orthodontic consultation. On clinical examination, permanent dentition was present on skeletal 1 dental base. Further evaluation revealed that the number of teeth present in the mandibular arch were less than normal and two teeth – the left and right lateral incisors (32 & 42)-were found to be larger and fused with the canine (33 & 43) (Figures 1a and b).

Intra-oral periapical radiograph (IOPA) revealed the complete fusion of the lateral incisor and canine bilaterally with single root and one pulp canal (Figures 1c and d).

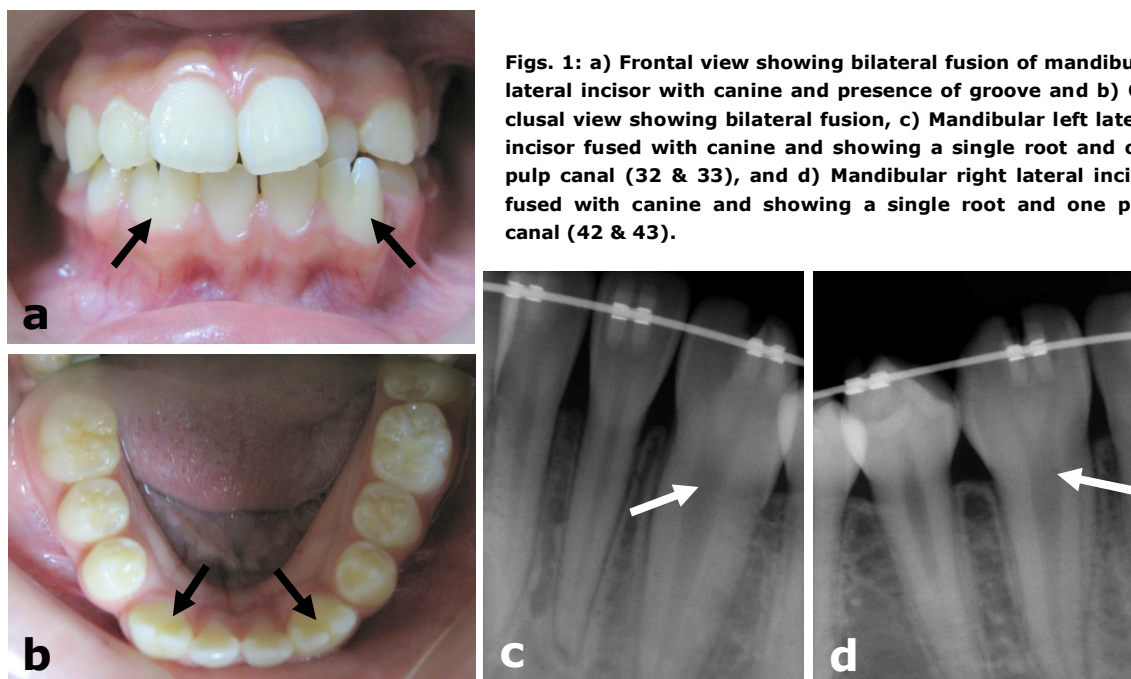
An orthodontic treatment involving braces was suggested. Following orthodontics

a composite restorative procedure to the fused teeth was recommended.

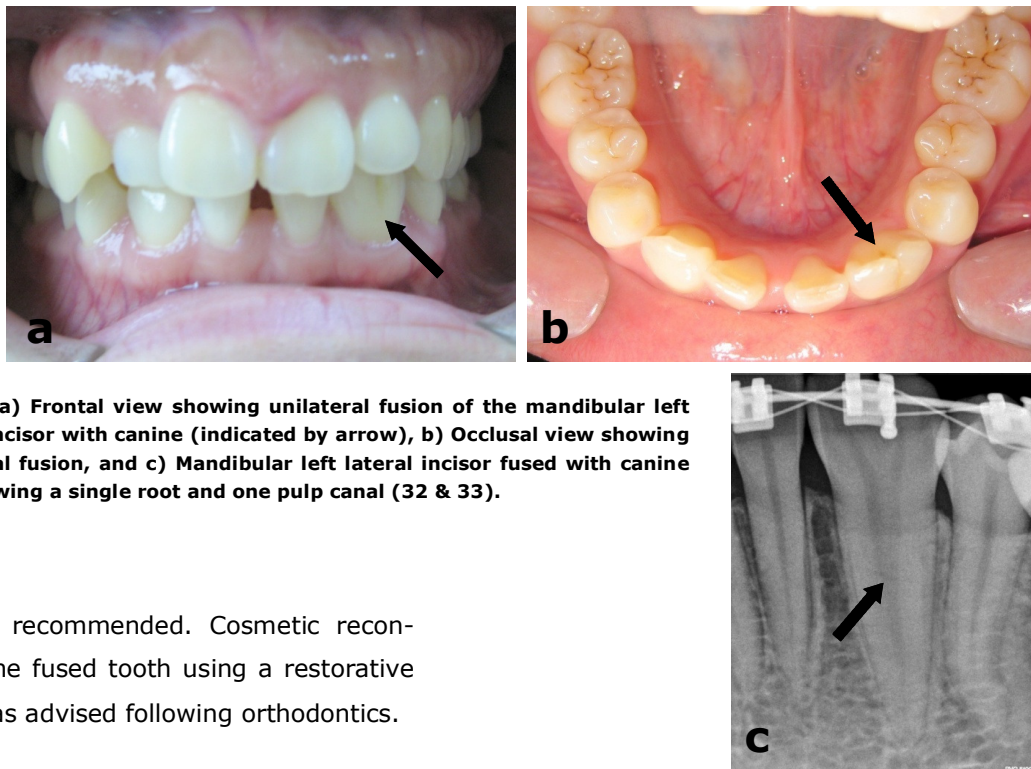
Case 2: A 29-year-old Malay lady reported to the dental department with the chief complaint of malaligned lower front teeth. Oral examination revealed the presence of lower midline spacing with unilateral fusion of the lower left lateral incisor and canine (fused 32 & 33). The fused tooth appeared to look larger and abnormal in shape (Figures 2a and b). It was also noticed that the lower right lateral incisor was congenitally missing contributing to a larger space in the arch.

IOPA revealed unilateral fusion of the lower left lateral incisor and canine with a single root and one pulp canal. The total number of teeth in the radiograph was less than the normal which confirmed the anomaly (Figure 2c).

A treatment plan involving fixed orthodontics to align the teeth and close the



Figs. 1: a) Frontal view showing bilateral fusion of mandibular lateral incisor with canine and presence of groove and b) Occlusal view showing bilateral fusion, c) Mandibular left lateral incisor fused with canine and showing a single root and one pulp canal (32 & 33), and d) Mandibular right lateral incisor fused with canine and showing a single root and one pulp canal (42 & 43).



Figs. 2: a) Frontal view showing unilateral fusion of the mandibular left lateral incisor with canine (indicated by arrow), b) Occlusal view showing unilateral fusion, and c) Mandibular left lateral incisor fused with canine and showing a single root and one pulp canal (32 & 33).

spaces was recommended. Cosmetic recontouring of the fused tooth using a restorative approach was advised following orthodontics.

DISCUSSION

A literature review reveals great difficulty in correctly differentiating two different morphological dental anomalies, 'fusion' and 'gemination'.¹⁰ A detailed clinical and radiographic examination can provide the information required for the diagnosis of such anomalies. Gemination is the incomplete division of a tooth germ with an attempt to form two separate entities. In cases of gemination, if the anomalous tooth is counted as one unit, the number of teeth in the arch will be normal. On the other hand fusion is the union of two or more teeth. Fusion can be classified as either complete or incomplete, depending on the stage when fusion occurs.¹¹ A single large tooth may be the result of an early fusion, whereas late fusion may give rise to separate teeth with continuity of roots only. If the fused tooth is counted as one unit, there will be one less tooth in the arch than normal.

After a detailed study of all information, our two cases represent 'early' fusion of the mandibular lateral incisors with the canine.

Fused teeth in the anterior region may appear aesthetically displeasing due to their irregular morphology. The deep groove present on the crown surface may predispose the teeth to development of dental caries as the bacterial plaque accumulation in these areas are high. In more severe cases the grooves may continue down the length of the root surface and may lead to periodontal complications.

There are different treatment approaches to this anomaly in the permanent dentition. Apart from orthodontic treatment for space consolidation, a restorative approach through selective anatomical recon-

crown provision) may provide an aesthetically pleasing result. Crown division has also been previously attempted but this often results in involvement of the pulp and subsequent endodontic treatment.¹⁰ A final option is surgical extraction and the use of a removable partial denture until the extracted tooth/teeth can be replaced with a bridge or an implant.

In conclusion, these two case reports describe a rare pattern of fusion of mandibular lateral incisor with the canine. The rarity, with which this entity appears, along with its complex characteristics, often makes it difficult to treat. Proper history-taking, clinical and radiographic examinations can complete the information required for the diagnosis of such abnormalities. Clinical management of dental anomalies such as fusion can be potentially complex and often requires a collaborative orthodontic-restorative approach to create functional and aesthetic success.

REFERENCES

- 1:** Kenezenic A, Travan S, Tarle Z, et al. Double tooth. *Coll Antropol* 2002; 26: 667-72.
 - 2:** Schuurs AHB, Van Loveren C. Double teeth: Review of the literature. *J Dent Child* 2000; 67:313-25.
 - 3:** Shafer WG, Hin MK, Levy BM. A text book of pathology 4th edition, Philadelphia: WB Saunders Company, 1983.
 - 4:** Hitchin AD, Morris I. Geminated odontome: Connation of the incisors in the dog, its etiology and ontogeny. *J Dent Res* 1966; 45:575-83.
 - 5:** Grover PS, Carpenter WM, Allen GW. Panographic survey of US army recruits. *Military Med* 1982; 147:1059-61.
 - 6:** Neves AA, Neves ML, Farinhas JA. Bilateral connation of permanent mandibular incisors: A case report. *Intl J Paediatr Dentist* 2002; 12:61-5.
 - 7:** Hulsmann M, Bahr R, Grohmann U. Hemisection and vital treatment of a fused tooth: Literature review and case report. *Quintessence Int* 1997; 13: 253-58.
 - 8:** Saxena A, Pandey RK, Kamboj M. Bilateral fusion of permanent mandibular incisors: A case report. *J Indian Soc Pedod Prevent Dent-Supplement* 2008; S32-33.
 - 9:** Nunes E, Moraes IG, Novaes PM, Sousa S. Bilateral fusion of mandibular second molars with supernumerary teeth: Case report. *Braz Dent J* 2002; 13:137-41.
 - 10:** Uyes H, Morris D. Double teeth-A diagnostic conundrum. *Dental update* 2005; 32:237-9.
 - 11:** Neville BN, Damm DD, Allen CM, Bouquot JE. *Oral and maxillofacial Pathology* 2nd ed, Philadelphia: WB Saunders 2002;pg 74-7.
-