

Adrenal cell carcinoma: Experience of an institution

Norasyikin AW ¹, Suehazlyn Z ¹, Rohaizak M ², Nor Azmi K ¹

¹ Endocrine Unit, Department of Medicine, Universiti Kebangsaan Malaysia Medical Centre, and ² Endocrine and Breast Surgery, Department of Surgery, Universiti Kebangsaan Malaysia Medical Centre, Malaysia

ABSTRACT

Introduction: Adrenal cell carcinoma (ACC) is a rare malignancy and often presents in the advanced stages. Clinical presentation varies depending on the type of ACC and whether the tumour is functional or non-functional. We report our experience with ACC encountered over seven years (2005 to 2011).

Material and Methods: All patients diagnosed and treated for ACC in our institutions were identified and data collected were collected and retrospectively analysed. Diagnoses of ACC were made based on: histology, combination of imaging and laboratory investigations.

Results: There were seven patients (Chinese, n=5 and female, n=4) with a median age of 39 years old (range 17 to 52) treated at our institution during this period. Four patients had functional cortisol producing tumours. In most, radical surgery was carried out with mitotane used as adjuvant therapy. Hypercortisolism was controlled using mitotane in most, and etomidate in one case. In the other three patients with non-functional tumours, the tumours were generally large at presentation and diagnosis. **Conclusion:** Although the overall prognosis of ACC is limited, the prognosis of the functional tumours is influenced by the success in reducing hormonal excess, whereas, in the non-functioning type, radical surgery seems to prolong survival.

Keywords: Adrenal gland neoplasms, adrenal cancers, adrenocortical carcinoma

INTRODUCTION

Adrenal cell carcinoma (ACC) is a rare and aggressive tumour with an incidence rate of between one and two cases per million populations per year. There are two recognised age peaks, an early peak occurring in those aged less than 5 years old and the second in the 4th decade of life. ¹ ACC is reported to occur more frequently among women and

children. ² The clinical presentations vary ranging from vague abdominal and loin pain to symptoms due to overt hormonal excess such as Cushing's syndrome. Due to the non-specific and vague presenting symptoms, diagnoses at the early stages are rare. Up to 63% of patients present with either local invasion or metastatic disease. Among ACC, 60% are functioning tumours and the most common hormone produced is cortisol. Overall prognosis is extremely poor with a five year survival rate between 35% and 47%. ³⁻⁵ Com-

Correspondence author: Norasyikin A. Wahab
Level 8, Department of Medicine, PPUKM,
Jalan Yaacob Latiff, Cheras, 56000
Kuala Lumpur, Malaysia.
Tel: +60129810882, Fax : +6091456934
E mail: Naw8282kt@gmail.com

plete resection of ACC is the only hope for cure. Cortisol secretion, old age and advanced stage of disease at diagnosis are parameters which are strongly correlated with poor survival rate. We report our experience with seven cases of ACC managed in our centre in the past seven years.

MATERIALS AND METHODS

Throughout 2005 until 2011, seven patients were either diagnosed at or referred to our institution for the management of ACC. Diagnosis of tumour was based on imaging, laboratory finding of hormone excess and histology. We collected data from the records of these patients with regard to their presentations and management. Families were contacted for patients who had defaulted follow-up. Data was then tabulated and analysed.

RESULTS

There were three men and four women in our series, with ages ranging from 17 to 52 years. All except two patients were of Chinese ethnic background.

Of these seven patients, four had cortisol-producing ACC. Cortisol-producing tu-

mours were diagnosed based on low dose dexamethasone suppression (LDDST) test. All had hypertension as well as diabetes mellitus. Two patients were previously treated with surgery in other institutions. One patient (Case 1) who had surgery three months previously presented with tumour recurrence. He was initially diagnosed on histology to have a left adrenal adenoma despite the large size (5cm x 4cm). The diagnosis was revised to ACC after resection of recurrence confirmed by histology. The other patient (Case 6) presented with resistant hypertension, cushingoid features and abnormal behaviour that was attributed to steroid psychosis. She had been treated for depression four years previously at her initial presentations. She defaulted follow-up after surgery. The remaining two patients who did not have prior surgery presented with recalcitrant hypertension and symptomatic hypokalaemia (Case 2) and depression, insomnia, and recurrent hypertensive crisis which led to pulmonary oedema (Case 3).

Among the three patients with non-functional ACC, two (Cases 4 and 7) presented with only abdominal pain while the other

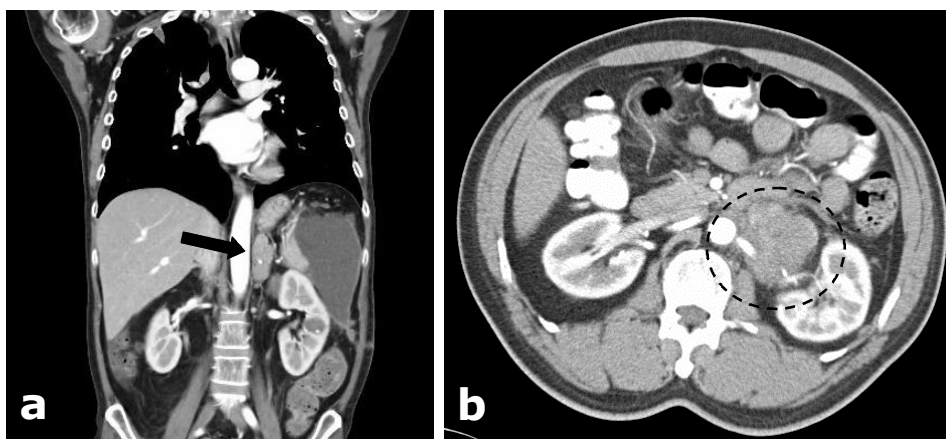


Fig. 1: a) Coronal post-contrast CT showing a left heterogenous enhancing adrenal mass (6 x 7cm, arrow) (Case 1), b) a contrast image showing an enhancing heterogeneous mass (5.5 x 5.9 x 6.6cm, broken circle) seen arising from the left adrenal gland, encasing the left renal artery and vein (Case 4).

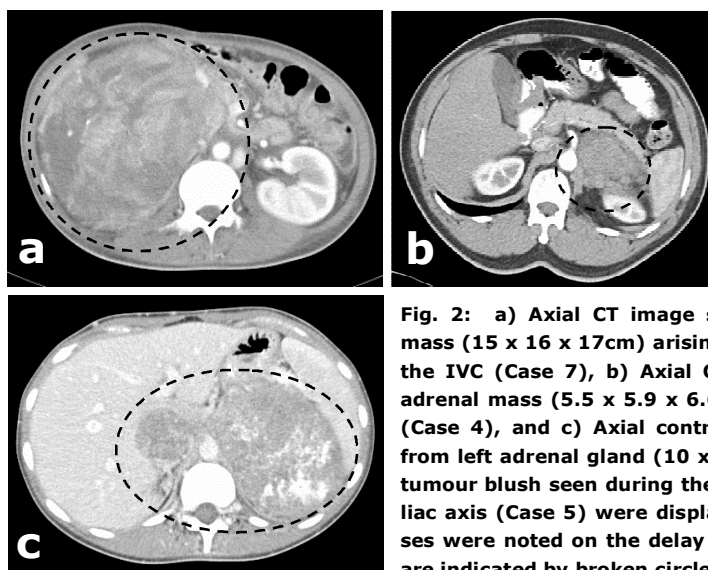


Fig. 2: a) Axial CT image showing a large enhancing heterogeneous mass (15 x 16 x 17cm) arising from the right adrenal gland compressing the IVC (Case 7), b) Axial CT showing a left heterogeneous enhancing adrenal mass (5.5 x 5.9 x 6.6cm) encasing the left renal artery (arrow) (Case 4), and c) Axial contrast CT showing a hypodense mass arising from left adrenal gland (10 x 12 x 15cm) with an IVC tumour thrombus-tumour blush seen during the arterial phase. The splenic artery and coeliac axis (Case 5) were displaced by the tumour. Multiple liver metastases were noted on the delay phase without contrast wash out. Tumours are indicated by broken circles

(Case 5) presented with pulmonary embolism and inferior vena cava (IVC) thrombus due to metastases to adjacent structures. All patients had advanced disease at diagnosis with metastases to either spleen, liver, adjacent vasculature or lymph nodes.

Medical therapies were offered as bridge to surgery. Two patients (Cases 4 and

6) declined treatment for fear of side effects of treatment. Altogether, four patients underwent radical surgery.

Three patients were still alive at the time of reporting. Two patients (Cases 1 and 4) who had surgery remained disease free for 8 to 9 months. One patient (Case 5), who had extensive surgery including cardio-

Table 1: Demographic, clinical presentation and investigations.

Case no.	Age (y)/gender	Race	Presentation	Relevant history	Biochemistry	Imaging
1	39/M	Chinese	Weight gain and Cushingoid face	Adrenal adenoma resected 3 months previously	Serum cortisol of 3,093 nmol/L and LDDST not suppressed	Left adrenal mass (6x7cm), hypodense lesion in the spleen (Fig. 1)
2	50/M	Chinese	Recalcitrant HT and hypokalaemia		Serum cortisol of 1,262 nmol/L and LDDST not suppressed	Right adrenal mass (3.7x3.4 x6.5cm), para-aortic and paratracheal lymph nodes
3	52/M	Chinese	Insomnia, depression, hypokalaemia, HT and acute pulmonary oedema		Serum cortisol of 1,576 nmol/L and midnight serum cortisol of 1,586 nmol/L	Left adrenal mass (5.1x5.1x5.0cm) and segment 6/7 liver hypo densities
4	50/M	Chinese	Left loin pain		Serum cortisol of 519 nmol/L and LDDST was suppressed	Right adrenal mass (5.5x5.9x6.6cm) encasing the left adrenal artery (Fig. 2)
5	17/F	Malay	Shortness of breath		Serum cortisol of 170 nmol/L	Left heterogeneous adrenal mass (10x12x15cm) with IVC thrombus
6	39/F	Chinese	Recurrent Cushing syndrome	Functional ACC diagnosed & operated 4 years previously	Serum cortisol of 869 nmol/L and urine cortisol of 3,031 nmol/L	Right supra-adrenal mass and hypodense lesions in the liver
7	29/M	Malay	Severe abdominal pain	Peuts Jegers syndrome	Serum cortisol of 410 nmol/L and LDDST was suppressed	Right heterogeneous adrenal mass (15x16x17cm) with metastasis to both lungs

HT: Hypertension and LDDST: Low dose dexamethasone suppression test

Table 2: Summary of the types of tumours, management and outcomes.

Case no.	Type of ACC	Medical therapy	Surgical therapy	Outcomes	Comments
1	Functional	Ketoconazole and mitotane	Adrenalectomy and splenectomy	Died (Sepsis)	Disease free duration of 9 months and 3 years survival
2	Functional	Ketoconazole	Not done	Dies (Sepsis)	
3	Functional	Ketoconazole, mitotane and etomidate infusion	Not done	Died (Sepsis)	
4	Non-functional	Refused	Adrenalectomy and nephrectomy	Alive *	8 months and no recurrence
5	Non-functional	Mitotane	Laparotomy and cardiopulmonary bypass	Alive (3 ½ years)	2 nd debulking surgery for tumour recurrence at 12 months after initial surgery
6	Functional	Defaulted	Refused surgery	Died *	Survived for 4 years
7	Non-functional	Mitotane	Adrenalectomy	Alive (2 years)	Tumour recurrence at 6 months

* as informed by family members

pulmonary bypass surgery for her IVC thrombus, had residual tumour in the ipsilateral (left) adrenal bed and IVC on PET scan on follow-up. This was followed by a debulking surgery approximately 12 months later from the primary tumour bed. She was commenced on mitotane following the initial surgery. She remains on follow up 3½ years after the initial presentation. A repeat CT scan showed residual tumour in the IVC with a new lesion in the liver and as well as in the right adrenal.

One patient with functional ACC died before the scheduled surgery from overwhelming sepsis while another patient who had refused surgery died shortly after diagnosis. This patient had the longest survival time of four years from the time of the initial diagnosis and surgery. Tables 1 and 2 summarise the presentations, management and outcome of patients with ACC.

DICUSSION

ACC that is functional often presents with symptoms of excess hormones. Amongst the-

se, the most common type is the cortisol producing ACC, resulting in Cushing’s Syndrome.³ In our series, patients with functional ACC all presented with signs and symptoms due to cortisol excess. Of the four patients with CS, two had extremely high cortisol levels, rendering them susceptible to severe infections. In managing patients with hypercortisolism, it is prudent to bring down their cortisol levels as a matter of urgency with whatever medical therapies available. Failure to do so effectively may result in morbidity as illustrated by three of our cases. Previous reports have also suggested that cortisol secretion is a strong independent factor associated with poor prognosis.⁴

On the other hand, ACC of the non-functioning tumours often present late.⁶ They are usually silent and are only diagnosed after attaining sizes large enough to cause local or pressure symptoms or after they have metastasised. ACC tends to metastasise to the lung, liver, kidneys and lymph nodes. Although rare, metastasis to adjacent vasculature such as the renal vein and IVC, have been reported. In the

case of the young girl (Case 5) with direct invasion of the IVC, we had persevered with repeated laparotomies on the principle that repeated debulking may help to ensure better response to mitotane.

The definitive treatment for ACC is surgery. In the case of a functional tumour, the excess hormone often contributes to disease burden. Adrenolytic agents have been widely used as adjuvant therapy to surgery to reduce the hormone level and mitotane was used in the majority of our patients. All of our patients with functional ACC received an adrenostatic agent in addition to ketocanazole to control the cortisol level. Although metyrapone may be used to reduce steroidogenesis it is not readily available in our institution. Meanwhile, in one patient where pulmonary oedema with hypertensive emergency seemed to be a recurrent problem, etomidate infusion was used to achieve rapid reduction of serum cortisol levels. This drug has been well-demonstrated to cause a significant reduction in serum cortisol.⁷ However, this effect is temporary and therefore often used while awaiting imminent surgery.⁸ In our patient, the effect was not sustained beyond 48 hours upon termination of infusion. The use of long term etomidate infusion was described in a previous report which allowed the hypercortisolism to be reduced for a much longer period even after the treatment was stopped.⁹

The overall prognosis of ACC is limited. Even in patients who seemed to have complete surgical resection, the risk of recurrence remains high up to 70 to 80%.¹⁰ This dismal prognosis has been attributed to micrometastases. Suspicion and early diagnosis,

coupled with radical surgery appeared to be the best method and the only hope for long term survival. In ACC with metastases, mitotane treatment along with de-bulking surgery is the management of choice.⁵ Despite radical resection in all our patients who had surgery, they are still at high risk for recurrence.

In conclusion, ACC present in the advanced stages with large bulky tumours especially the non-functional tumours. In patients with functional tumours, the importance of lowering the serum cortisol level pre-operatively must be emphasised, so as to reduce the likelihood of fatal infection. Achieving optimisation of mitotane doses needs to be attempted as quickly as possible. Surgery remains the main treatment option once hormonal symptoms have been controlled. Recurrence can occur and patients need to be followed up closely.

REFERENCES

- 1: Guerrero MA, Kebebew E. Adrenocortical carcinoma and synchronous malignancies. *J Cancer.* 2010;1:108-11.
- 2: Lacroix A. Approach to the patient with adrenocortical carcinoma. *J Clin Endocrinol Metab.* 2010;95:4812-22.
- 3: Icard P, Goudet P, Charpenay C, et al. Adrenocortical carcinomas: Surgical trends and results of a 253-patient series from the french association of endocrine surgeons study group. *World J Surg.* 2001;25:891-7.
- 4: Abiven G, Coste J, Groussin L, et al. Clinical and biological features in the prognosis of adrenocortical cancer: Poor outcome of cortisol-secreting tumors in a series of 202 consecutive patients. *J Clin Endocrinol Metab.* 2006; 91:2650-5.
- 5: Fassnacht M, Allolio B. Clinical management of adrenocortical carcinoma. *Best Pract Res Clin Endocrinol Metab.* 2009; 23:273-89.
- 6: Libe R, Fratticci A, Bertherat J. Adrenocortical

cancer: Pathophysiology and clinical management. *Endocr Relat Cancer.* 2007; 14:13-28.

7: Vinclair M, Broux C, Faure P, et al. Duration of adrenal inhibition following a single dose of etomidate in critically ill patients. *Intensive Care Med.* 2008; 34:714-9.


8: Lutgers HL, Vergragt J, Dong PV, et al. Severe hypercortisolism: A medical emergency requiring urgent intervention. *Crit Care Med.* 2010; 38:1598-

601.

9: Krakoff J, Koch CA, Calis KA, Alexander RH, Nieman LK. Use of a parenteral propylene glycol-containing etomidate preparation for the long-term management of ectopic cushing's syndrome. *J Clin Endocrinol Metab.* 2001; 86:4104-8.

10: Maluf DF, de Oliveira BH, Lalli E. Therapy of adrenocortical cancer: Present and future. *American journal of cancer research.* 2011; 1:222-32.

Brunei Darussalam – Healthcare in Pictures



Patients waiting in the Antenatal and Paediatric clinic in the Temporary Hospital (1946-1947) after the Second World War (*Refer to Healthcare in Brunei Darussalam: Temporary Hospitals after the Second World War. Brunei International Med J.* 2012; 8(3); 115).
