

# Marked hemiatrophy caused by a nonsense mutation of the dystrophin gene in a female patient of Duchenne muscular dystrophy

<sup>1</sup>Zhi-Jie Zhou MD PhD, <sup>2</sup>Yu-Quan Shao MD, <sup>2</sup>Fei Xie MD, <sup>2</sup>Ping Xia MD

<sup>1</sup>Department of Orthopaedic Surgery & <sup>2</sup>Department of Neurology, Sir Run Run Shaw Hospital, School of Medicine, Zhejiang University, Hangzhou, China

## Abstract

Our objective is to report a female carrier of Duchenne muscular dystrophy (DMD) presented with remarkable asymmetric limb weakness and atrophy caused by a heterozygous point mutation in *DMD* gene. The patient was born in a non-consanguineous marriage. She experienced slowly progressive weakness and atrophy of her right limbs for approximately 20 years. The thigh muscle magnetic resonance imaging (MRI) showed obvious atrophy with fatty replacement on the right thigh compared with the left, and the ‘trefoil with single fruit sign’ was observed. Muscle pathology revealed decreased dystrophin protein expression in scattered fibers. The multiplex ligation-dependent probe analysis (MLPA) analysis did not detect any large rearrangements. Subsequent whole exome sequencing (WES) identified a heterozygous nonsense mutation, c.1471C>T (p. Q491\*) of dystrophin (*DMD*) gene in the patient. This report highlights that marked hemiatrophy can occur in a female manifesting carriers of DMD and WES should be considered in MLPA-negative patients. Muscle MRI can serve as an adjunct to diagnose dystrophinopathies.

**Keywords:** Duchenne muscular dystrophy; female carrier; hemiatrophy

## INTRODUCTION

Duchenne muscular dystrophy (DMD) and Becker muscular dystrophy (BMD) are X-linked genetic disorders caused by mutations in the dystrophin (*DMD*) gene. DMD/BMD patients are most frequently caused by deletions (60%-75.5%) or duplications (10%) of one or more exons in the *DMD* gene.<sup>1-3</sup> While a minority variations are small mutations, such as substitutions, insertions, deletions, or duplications of one or several nucleotides in the *DMD* gene.<sup>1-3</sup> In general, most female carriers of DMD/BMD are asymptomatic. However, it is reported that 2.5% to 22% of DMD/BMD carriers present with a broad phenotypic spectrum, encompassing myalgia, muscle weakness and dilated cardiomyopathy and rarely, asymmetric atrophy.<sup>4</sup> In this study, we presented a Chinese female carrier exhibiting marked hemiatrophy caused by a nonsense mutation of the *DMD* gene. Written informed consent was obtained from the patient. This study was approved by the Research Ethics Committees of Sir Run Run Shaw Hospital, Zhejiang University.

## CASE REPORT

A 47-year-old female patient was admitted to our department because of a 20-year history of progressive weakness and wasting in her right limbs. The musculature in her left arm and leg was unaffected as were her facial muscles. She reported no disturbance of sensation, sphincter function of urination and defecation. The patient denied family history of any muscle diseases. Neurological examination showed marked atrophy of her right arm and leg. The power of the right proximal upper and lower limbs was 4/5, and the left limbs were entirely normal on examination. Muscle tone, tendon reflexes and sensation examination were normal. Babinski sign was negative. The laboratory test showed that the level of creatine kinase (1,877 U/L) and lactic dehydrogenase (420 U/L) was mildly elevated. Electromyography revealed myogenic damage with spontaneous potential in the right gastrocnemius muscle. Electrocardiography showed mild T wave changes in the lateral and inferior wall leads. Echocardiogram revealed left

Address correspondence to: Ping Xia MD, Department of Neurology, Sir Run Run Shaw Hospital, School of Medicine, Zhejiang University, 3 East Qingchun Road, Hangzhou 310016, China. Tel: +86006906, E-mail: xiaping01062@163.com

Date of Submission: 1 July 2020; Date of Acceptance: 21 September 2020

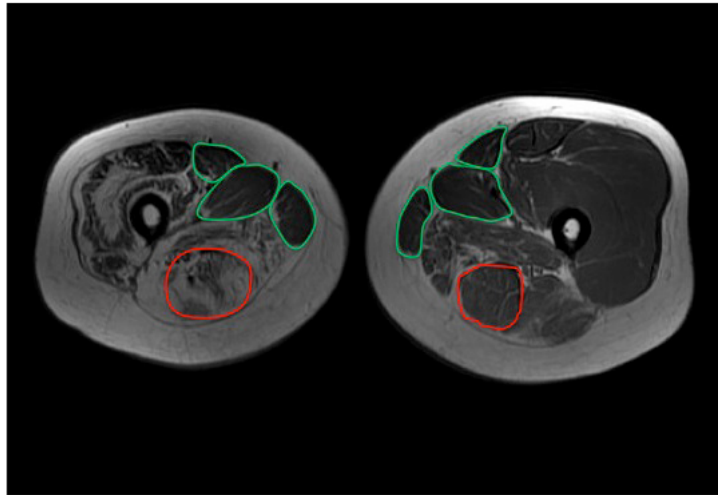


Figure 1. MR of the thighs (T1-weighted sequence). Marked atrophy and fatty infiltration of the right thigh are noted, and sartorius, gracilis, adductor longus and the semitendinosus are relatively spared on both sides.

ventricle regional wall motion abnormality with a mild decreased systolic function. Magnetic resonance imaging (MRI) of her legs indicated right-sided muscle atrophy with fatty replacement compared with the left (Figure 1). In addition, the relative sparing of the sartorius, gracilis, adductor longus and the semitendinosus could be seen in the muscle MRI, which was best described as the 'trefoil with single fruit sign'.<sup>5</sup> In view of the severe fatty replacement, the patient underwent

left quadriceps muscle biopsy and histological examination showed increased variation in muscle fiber size and inward migration of the nuclei. Further immunochemistry of the muscle demonstrated decreased expression for dystrophin protein in scattered muscle fibers (Figure 2).

Blood sample of the patient was collected and genomic DNA was extracted from peripheral leukocytes using the standard method. As dystrophinopathy was taken into the clinical

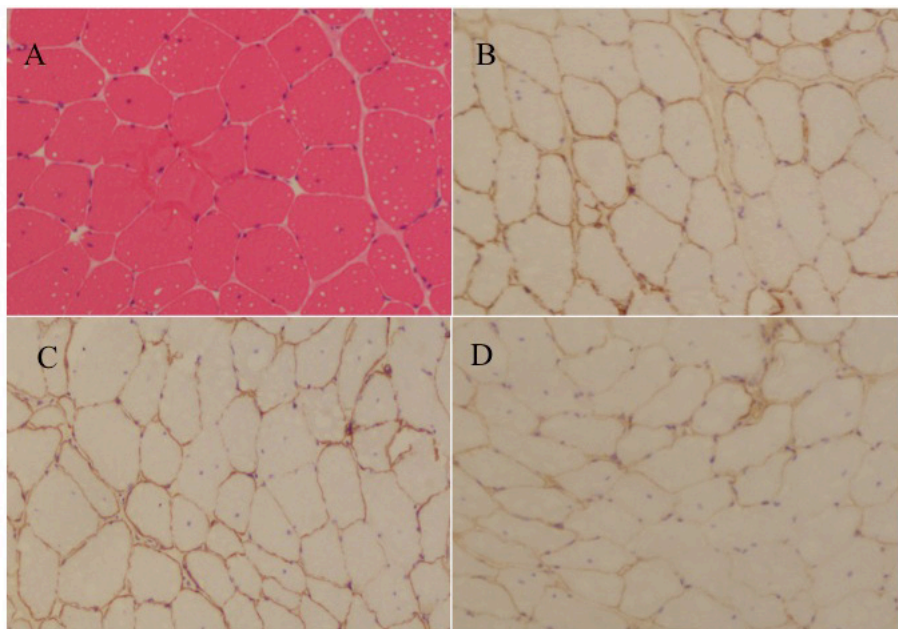


Figure 2. Representative light microscopy of muscle biopsy ( $\times 100$ ). (A) Hematoxylin and eosin staining demonstrates variation in muscle fiber size and inward migration of the nuclei in several fibers. (B-D) Immunohistochemistry method shows decreased expression of N-, R-, C-terminal domain of dystrophin protein in scattered fibers.

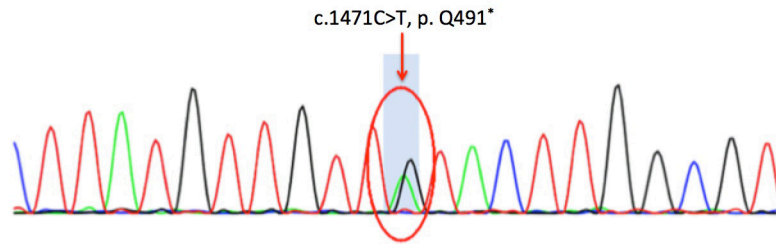


Figure 3. Sequence chromatogram of heterozygous mutation, c.1471C>T, (p. Q491\*)

consideration, the MLPA was performed for the further diagnosis. However, the MLPA did not detect any large duplication or deletion in the *DMD* gene. Further DNA sequencing of the 79 coding exons of the *DMD* gene demonstrated a nonsense variant of exon 12 of *DMD* gene, (NM\_004006.2) (c.1471C>T, p. Q491\*), resulting in the substitution of an abnormal stop codon termination of the glutamine (Fig. 3). This variant was previously reported as a pathogenic variant causing DMD (<http://www.hgmd.cf.ac.uk/ac/index.php>). Accordingly, the female patient was regarded as a manifesting DMD carrier. The mutation was not found in her only daughter. It was a pity that the genomic DNA of the other direct relatives of the proband was not available.

## DISCUSSION

Asymmetric weakness and atrophy has been detected as a distinctive feature in a few DMD carriers. Most of them are mild asymmetric and genetic analysis demonstrated exonic duplication or deletion in these patients.<sup>4,6,7</sup> We here reported a female carrier presented with remarkable asymmetric limb weakness and atrophy caused by a heterozygous point mutation in *DMD* gene, c.1471C>T.

Till now, the mechanisms of manifestation female carrier of *DMD* mutation in X-linked recessive disorders are not fully understood.<sup>8</sup> The clinical manifestation of these disorders are generally considered to be caused by skewed X-inactivation in the early embryonic stage, a process that is normally random and ensures dosage equalization of X-linked genes between XX female and XY male subjects.<sup>9,10</sup> However, skewed X-inactivation alone is not sufficient to generate the asymmetric manifestation.<sup>4</sup> It is deduced that a disproportionately high expression of the X-chromosome carrying the mutant *DMD* gene on the more affected side, with preferential inactivation of the X chromosome harboring wild-type *DMD* might account for the remarkable

asymmetrical presentation.<sup>4</sup>

It was reported that cardiac involvement is presented in approximately 3% to 40% of the female carriers, including left ventricle dilation and dilated cardiomyopathy.<sup>11,12</sup> Although the cardiac symptom was absent in our patient, segmental left wall motion abnormality was detected by echocardiogram. The prognoses of *DMD* female carriers depend on the severity of cardiomyopathy.<sup>13</sup> Therefore, regular cardiac evaluation is strongly recommended in female carriers and early treatment can delay serious complications.<sup>13</sup> Myocardial intervention includes beta-blocker, angiotension-converting enzyme inhibitor (ACEI) and corticosteroids.<sup>14</sup>

Interestingly, the ‘trefoil with single fruit sign’ was found in the muscle MRI of our patient, which is a distinct pattern of fatty infiltration of dystrophinopathies with a high specificity of 99.2%.<sup>5</sup> The relative sparing of sartorius, gracilis and adductor longus form the triple leaflet and the relative sparing of the semitendinosus forms the single fruit. The mechanism is still not clearly elucidated. Different roles of different thigh muscles throughout the physical development of standing and then walking might be related to this phenomenon. However, the semitendinosus muscle with less involvement does not accord with this theoretical model.<sup>5</sup> Muscle MRI is considered an important auxiliary method to diagnose dystrophinopathies. To patients like ours, dystrophinopathy was suspected based on the clinical manifestation or immunohistochemistry of muscle biopsy but the MLPA analysis failed to detect large duplication or deletions, MRI pattern of muscle involvement could help to strengthen the diagnosis and suggest a necessity for a complete sequencing of the *DMD* gene.

In conclusion, this report highlights that the sequencing of *DMD* gene should be recommended in female patients with marked hemiatrophy, especially when the MLPA is negative. Further, muscle MRI can serve as an adjunct to diagnose dystrophinopathies.

## DISCLOSURE

Financial support: The study was sponsored by Zhejiang medical and health science and technology project (2017KY091).

Conflict of interest: None

## REFERENCES

1. Koenig M, Hoffman EP, Bertelson CJ, *et al.* Complete cloning of the Duchenne muscular dystrophy (DMD) cDNA and preliminary genomic organization of the DMD gene in normal and affected individuals. *Cell* 1987; 50:509-17.
2. Prior TW, Bartolo C, Pearl DK, *et al.* Spectrum of small mutations in the dystrophin coding region. *Am J Hum Genet* 1995; 57:22-33.
3. Zimowski JG, Pawelec M, Purzycka JK, *et al.* Deletions, not duplications or small mutations, are the predominant new mutations in the dystrophin gene. *J Hum Genet* 2017; 62: 885-8.
4. Rajakulendran S, Kuntzer T, Dunand M, *et al.* Marked hemiatrophy in carriers of Duchenne muscular dystrophy. *Arch Neurol* 2010; 67:497-500.
5. Zheng Y, Li W, Du J, *et al.* The trefoil with single fruit sign in muscle magnetic resonance imaging is highly specific for dystrophinopathies. *Eur J Radiol* 2015; 84:1992-8.
6. Lee SH, Lee JH, Lee KA, *et al.* Clinical and genetic characterization of female dystrophinopathy. *J Clin Neurol* 2015;11:248-51.
7. Tasca G, Monforte M, Iannaccone E, *et al.* Muscle MRI in female carriers of dystrophinopathy. *Eur J Neurol* 2012;19:1256-60.
8. Bing Q, Hu J, Zhao Z, *et al.* Clinical and genetic analyses of two female Duchenne muscular dystrophy manifesting carriers and their families. *Chin J Neuromed* 2015; 14:484-9.
9. Carrel L, Willard HF. X-inactivation profile reveals extensive variability in X-linked gene expression in females. *Nature* 2005; 434:400-4.
10. Ishizaki M, Kobayashi M, Adachi K, *et al.* Female dystrophin myopathy: Review of current literature. *Neuromuscul Disord* 2018; 28:572-81.
11. Hoogerwaard EM, Bakker E, Ippel PF, *et al.* Signs and symptoms of Duchenne muscular dystrophy and Becker muscular dystrophy among carriers in the Netherlands: a cohort study. *Lancet* 1999; 353:2116-9.
12. Mccaffrey T, Guglieri M, Murphy AP, *et al.* Cardiac involvement in female carriers of Duchenne or Becker muscular dystrophy. *Muscle Nerve* 2017; 55:810-8.
13. Yu H, Chen YC, Liu GL, *et al.* A De novo mutation in dystrophin causing muscular dystrophy in a female patient. *Chin Med J* 2017; 130:2273-8.
14. Raman SV, Hor KN, Mazur W, *et al.* Eplerenone for early cardiomyopathy in Duchenne muscular dystrophy: A randomized, double-blind, placebo-controlled trial. *Lancet Neurol* 2015; 14:153-61.