

## CASE REPORT

# Moyamoya Angiopathy in Southeast Asians: Systematic review of literature with an illustrative case

Alfeo Julius R. Sy\*, Lindt Camille O. Alba, and Marc Conrad C. Molina

Section of Adult Neurology, Department of Internal Medicine, Cardinal Santos Medical Center, San Juan, Philippines

## ABSTRACT

**Background:** Moyamoya angiopathy (MMA) is a rare cause of stroke, yet its incidence and outcomes are understudied in Southeast Asia, despite being the third most populous geographical region in the world. Our aim was to enhance understanding of MMA in this population and present a case from our experience.

**Methodology:** A systematic literature search on MMA in the Southeast Asian population was performed via PubMed, Scopus, and Wiley Online Library, including local journals and databases up until May 2024. Descriptive statistics were used to synthesize data. We also present a case of a 36-year-old Filipino female diagnosed with MMA followed by superficial temporal artery-middle cerebral artery (STA-MCA) bypass and resolution of symptoms.

**Results:** Out of the 275 articles retrieved, 23 articles detailing 37 patients of Southeast Asian nationality were included in this review. Stroke predominated (76.3%, n=29) as initial presentation, followed by seizures (36.8%, n=14), movement disorders (n=4, 10.5%) and headaches (n=4, 10.5%). Treatment included antiplatelet therapy for 57.9% (n=22), and anti-seizure medications for 26.3% (n=10) of cases. Only 21% (n=8) underwent surgical intervention, primarily via direct bypass. Outcomes based on the Modified Rankin Scale (MRS) showed 94.7% (n=36) had retained a functional score of MRS ≤2.

**Conclusion:** Our review underscores the scarcity of data on MMA in Southeast Asians, and highlights the varied clinical presentation. Effective management requires a tailored approach, with surgical management showing favorable outcomes. Future research should focus on longitudinal studies to assess long-term outcomes, explore the genetic and environmental factors, and develop standardized treatment protocols to improve patient care in this ethnically diverse population.

## Introduction

Moyamoya angiopathy (MMA) represents a rare etiology of stroke, characterized by the progressive narrowing at the terminal portion of the intracranial carotid artery (ICA), and proximal portion of the anterior cerebral artery (ACA) and/or middle cerebral artery (MCA), accompanied by formation of abnormal vascular networks [1]. MMA has a diverse clinical profile, most commonly presenting as cerebrovascular events (ischemic and hemorrhagic), but can also present with cognitive deficits, migraine-like episodes, psychiatric and movement disorders [2,6]. An unusual and rare manifestation of MMA includes limb shaking transient ischemic attacks (LS-TIA), presenting as brief, involuntary, arrhythmic, coarse flailing or jerking movements [3,7]. MMA is more common in East Asia, with an annual incidence of 0.5–1.5 per 100,000 individuals, compared to 0.1 per 100,000 in the western population [2–7]. Despite Southeast Asia (SEA) being the third most populous geographical region, based on the United Nations estimates as of May 2024, data on the clinical presentation, treatment choices, and outcomes of MMA is sparse and limited to case reports and case series. Our aim is to enhance understanding of MMA in the Southeast Asian population by summarizing the current literature, and provide an illustrative case of our own experience.

## Systematic Review

An extensive literature search was performed on Medline via PubMed, Scopus, and Wiley Online Library up until May 2024. We included local journals and databases such as Acta Medica Philippina, Philippine Journal of Neurology, and Health Research and Development Information Network (HERDIN) of the Philippines. The following Medical subject headings (MeSH) and free texts with combinations of “Moyamoya” or “Moya” with one of the following search terms: “Thai”, “Thailand”, “Vietnam”, “Vietnamese”, “Indonesia”, “Indonesian”, “Cambodia”, “Cambodian”, “Brunei”, “Bruneian”, “Laos”, “Laotian”, “Malaysia”, “Malaysian”, “Myanmar”, “Burma”, “East Timor”, “Singapore”, “Singaporean”, “Philippines”, “Philippine”, “Filipino”, “Southeast Asia”, and “Southeast Asian” were used. We included case reports and case series involving

Southeast Asian patients, with no age restrictions, diagnosed with Moyamoya angiopathy based on diagnostic criteria applicable at the time of publication. Inclusion criteria for publications in this review were: (a) diagnosis meeting the criteria of Moyamoya angiopathy, (b) included the Southeast Asian population, and (c) with data presented on clinical presentation, diagnostics, treatment modalities, and outcomes. We screened all titles and abstracts of the records retrieved from the systematic search. All articles which satisfied the screening criteria were obtained in full-text. Articles presented in languages with no available English version or if the full text was not available were excluded. The articles which fulfilled the eligibility criteria were included in this review (Figure 1). Data on patient profile, diagnostics, treatment, and outcomes were extracted. Outcome was based on the Modified Rankin Score (MRS). In instances where the MRS was unavailable, two independent reviewers decided on the appropriate MRS based on the clinical data presented. A third reviewer was consulted to arbitrate any discrepancies in scoring. MRS scores of 2 or less were categorized as good outcomes, and scores of 3 and above were categorized as poor. Descriptive statistics were used to synthesize data.

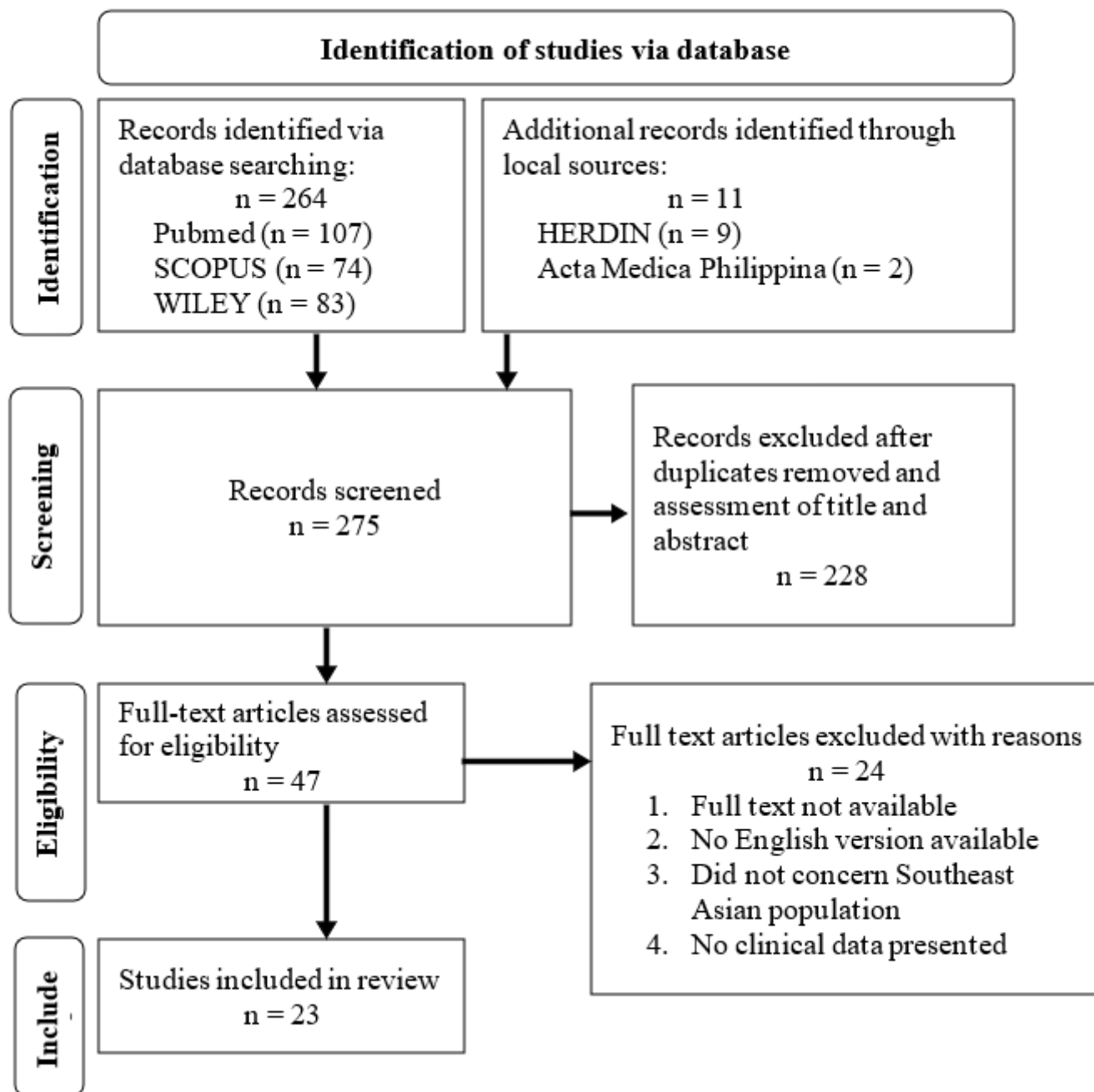
## Case Presentation

A 36 year-old Filipino female presented recurrent limb-shaking transient ischemic attacks on the left arm and face since the age of 31. The episodes lasted for less than 5 minutes and occurred two to three times per week, precipitated by fatigue. She had a past medical history of hypertension and is currently maintained on sacubitril + valsartan. Family medical history was

**Corresponding author's email address:**  
sy.alfeo@gmail.com

**Keywords:** limb-shaking TIA, moyamoya angiopathy, vascular neurology, case report, literature review





**Figure 1.** Preferred Reporting Items for Systematic Reviews and Meta-Analyses flow diagram for this review.

unremarkable. She sought multiple consults and was started on anti-seizure medications, including a trial of levodopa, but with no relief of symptoms. Upon workup by Neurology service, cranial magnetic resonance imaging (MRI) with contrast and MR angiography showed prominent vascular structures within the right basal ganglia, compatible with moyamoya vasculature. MR perfusion study demonstrated a large area of prolonged mean transit time (MTT) and prolonged time to peak (TTP) involving the right frontal, right parietal, and right temporal lobes. Cerebral angiography showed severe stenosis from the right terminal internal carotid artery up to the entire length of the right middle cerebral artery M1 segment with flow to the right anterior cerebral artery no longer visualized. Other diagnostics included a prolonged electroencephalogram (EEG) monitoring, and an extensive autoimmune and metabolic panel, all of which were unremarkable. Based on these findings, the patient was diagnosed with Suzuki stage III Moyamoya angiopathy and was subsequently admitted for surgical treatment.

The patient underwent a superficial temporal artery – middle cerebral artery (STA-MCA) bypass surgery on the right. Postoperatively, transcranial duplex

study showed patent bypass, and computed tomography (CT) perfusion scan shows preferential increased blood volume in the right MCA territory. She was discharged with aspirin 80mg once daily, and with plans to slowly titrate and discontinue her antiseizure medications. On outpatient follow up after 2 weeks, 1 month, and 3 months, the patient remains symptom free.

## Results

Out of the 275 articles retrieved from the systematic search, 23 articles detailing 37 patients of Southeast Asian nationality were included in this review. Including the present case, information from a total of 38 patients was retrieved and analyzed (Appendix A).

Records from thirty-eight Southeast Asian patients with MMA were included (Table 1); twenty-five (55.3%) of whom were female. Majority of the documented cases were of Thai descent (n=16, 42.1%), followed by Filipino (n=7, 18.4%), and Malaysian (n=6, 15.8%). Stroke was the most prevalent manifestation, occurring in 76.3% of cases (n=29), with patients presenting with hemiparesis and/or aphasia. This was followed by seizures,

which were documented in 36.8% (n=14) of the patients. Movement disorders (n=4, 10.5%) and headaches (n=4, 10.5%) were an infrequent presentation. Asymptomatic and incidental findings of MMA were reported in a small subset of the cohort (n=2). At the time of diagnosis, 55% (n=21) presented with a single neurologic symptom, while 39% (n=15) will have a combination of different neurological syndromes, and 06% (n=2) were asymptomatic with incidental findings of MMA (Figure 2).

In terms of management, 57.9% (n = 22) of patients presenting with stroke were started on antiplatelet therapy, with Aspirin most commonly used. 26.3% of cases (n=10) with seizure manifestations were treated with anti-seizure medications, and notably 17% (n=5) of symptomatic cases were given multidrug therapy. Only 21% (n=8) of cases underwent surgical intervention, with direct bypass being the preferred option in 5 out of 8 cases.

The disease is known to have variable outcomes, and our study reveals the modified Rankin Scale (MRS) scores among the cohort to be varied. Specifically, 55% (n=22) of patients achieved an MRS score of 0, indicating full functional independence. Eight patients had an MRS score of 1, and seven patients had an MRS score of 2. One patient, a 2-year-old male with protein S deficiency presenting with hemiparesis and seizures, did not survive. Overall, 94.7% (n=36) of the cohort had good outcomes and did not vary between those who underwent surgical intervention and those treated with supportive medications.

## Discussion

This systematic review presented an extensive search for the clinical profile of Moyamoya angiopathy in the Southeast Asian population, with information synthesized from a total of 38 patients, including a unique case of limb shaking transient ischemic attack (TIA). This uncommon manifestation of Moyamoya angiopathy poses diagnostic challenges due to its rarity and variable clinical presentation. The pathophysiology involves a complex interplay of hemodynamic disturbances and cerebral ischemia. The progressive stenosis or occlusion of the vessels leads to chronic cerebral hypoperfusion and impaired neurovascular regulation [8]. While the compensatory collateral vessels formed in response to arterial occlusion may be insufficient to maintain adequate cerebral perfusion during periods of increased demand, predisposing the brain to transient ischemic episodes. The resulting hypoperfusion results in dysfunction of the circuitry between the frontal cortical and subcortical motor pathways[3-7,9,10].

The management of Moyamoya disease remains multifaceted and warrants further exploration through prospective trials. Our case underscores the significance of a tailored approach encompassing both medical and surgical

modalities with the goal of alleviating symptoms and enhancing quality of life. The successful outcome post-STA-MCA bypass surgery also highlights the critical role of surgical intervention in restoring cerebral perfusion and mitigating ischemic events in Moyamoya patients presenting with limb shaking TIA. Currently, there is a lack of prospective randomized controlled trials regarding revascularization surgery for ischemic prevention in moyamoya [11]. But case reports of LS-TIA secondary to MMA have reported good outcomes after direct bypass surgery [3-7,9,12,13] with the main goal of improving cerebral blood flow [14], as was seen in our case. Limited data on incidence and presentation in the Southeast Asian population underscores challenges in diagnosis, access to care, and socioeconomic factors affecting disease awareness and management.

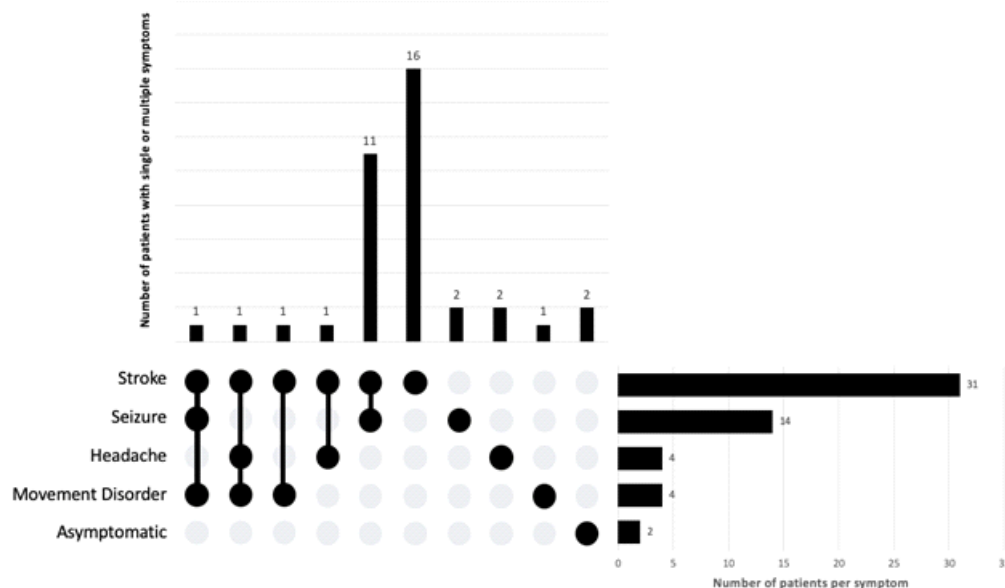
There are several limitations to this study encountered. Firstly, several articles had restricted access to the full text of articles limiting the amount of data presented. Secondly, incomplete reporting within some included studies resulted in gaps in the available data, potentially influencing the overall synthesis and interpretation of findings. Moreover, it is recognized that the presence of underreported cases within the literature reviewed may have skewed the representation of outcomes, thus impacting the generalizability of the results. These limitations underscore the importance of exercising caution when interpreting the findings of this review and emphasize the necessity for future research to address these gaps in knowledge.

## Conclusion

Our review underscores the scarcity of data on MMA in Southeast Asians and highlights the varied clinical presentations that often confuse clinicians. Effective management requires a tailored approach integrating medical and surgical interventions, with surgical management showing particularly favorable outcomes. Despite study limitations such as restricted access to full-text articles and incomplete data reporting in some studies, our findings emphasize the need for future research to optimize treatment strategies, increase awareness, and address challenges to accessibility of treatment options, particularly in ethnically diverse populations like Southeast Asians. Future research should focus on longitudinal studies to assess long-term outcomes of surgical interventions, explore the genetic and environmental factors, and develop standardized treatment protocols to improve patient care in this ethnically diverse population.

### Consent for publication

Voluntary signed consent was obtained from the patient before submission, and CaRE guidelines were followed in the writing of this manuscript.



**Figure 2.** Overlap of the presentations of Moyamoya Angiopathy.

The matrix at the bottom shows the visualized intersection of the neurological syndromes (stroke, seizure, headache, movement disorder) in which the rows represent the different symptoms, and the columns represent their intersections. For each symptom that is part of a given intersection, a black-colored dot is placed in the corresponding matrix cell. If a symptom is not part of the intersection, a light, gray-colored dot is shown. A vertical black line connects the topmost black dot with the bottom-most black dot in each column to emphasize the overlapping relationships. The bar chart above of the matrix displays the number of patients for each clinical profile, and the bar graph on the right displays the number of patients for each symptom.

**Table 1.** Characteristics of Southeast Asian patients with Moyamoya Angiopathy in literature

Characteristics	Results (n = 38)
<b>Age, years</b>	Mean = 21, Median = 12, St dev = 19.6
<b>Nationality</b>	
Thai	16 (42.1)
Filipino	7 (18.4)
Malaysian	6 (15.8)
Singaporean	4 (10.5)
Indonesian	2 (5.3)
Vietnamese	1 (2.6)
Southeast Asian	1 (2.6)
Cambodian	1 (2.6)
<b>Sex</b>	
Female	21 (55.3)
Male	17 (44.7)
<b>Symptoms / Presentations</b>	
Stroke syndrome	29 (76.3)
Seizure	14 (36.8)
Movement disorder	4 (10.5)
Headache	4 (10.5)
Asymptomatic	2 (05.2)
<b>Medical management</b>	
Antithrombotic	22 (57.9)
Antiseizure	10 (26.3)
Levodopa-benserazide	1 (2.6)
<b>Surgical management</b>	
Direct bypass	5 (13.2)
Indirect bypass	3 (7.9)
<b>Outcome</b>	
Good (MRS 0-2)	36 (94.7)
Poor (MRS 3-6)	2 (05.3)

### Patient perspective

The patient shared how anxious and worried she was prior to undergoing the procedure, but the thorough and detailed explanation of the doctors helped her overcome her fears. She felt she still had a lot to accomplish at her age, and that gave her motivation to proceed with the bypass. During post-operation, she was very happy that she decided to proceed with the treatment and looks forward to enjoying her life without the worry of her symptoms recurring.

### Author contribution statement

All authors listed have significantly contributed to the investigation, development and writing of this article.

### Funding

Not applicable.

### Declaration of competing interest

The authors declare that they have no known competing financial interests or personal relationships that could have appeared to influence the work reported in this paper.

## References

- Kuroda S, Fujimura M, Takahashi J, Kataoka H, Ogasawara K, *et al.* (2022) Research Committee on Moyamoya Disease (Spontaneous Occlusion of Circle of Willis) of the Ministry of Health, Labor, and Welfare, Japan. Diagnostic Criteria for Moyamoya Disease - 2021 Revised Version. *Neurol Med Chir (Tokyo)*. 62(7):307-312.
- Han DH, Nam DH, Oh CW. (1997) Moyamoya disease in adults: characteristics of clinical presentation and outcome after encephaloduro-arterio-synangiosis. *Clin Neurol Neurosurg*. 99(2):S151-5.
- Das S, Ghosh R, Dubey S, Pandit A, Ray BK, *et al.* (2021) Limb-shaking TIA in Moyamoya angiopathy. *Clin Neurol Neurosurg*. 207:106783.
- Mertens R, Graupera M, Gerhardt H, *et al.* (2022) The genetic basis of moyamoya disease. *Transl Stroke Res* 13:25–45. <https://doi.org/10.1007/s12975-021-00940-2>.
- Baba T, Houkin K, Kuroda S. (2008) Novel epidemiological features of moyamoya disease. *J Neurol Neurosurg Psychiatry* 79:900–904. <https://doi.org/10.1136/jnnp.2007.130666>.
- Ahn IM, Park D-H, Hann HJ, *et al.* (2014) Incidence, prevalence, and survival of moyamoya disease in Korea: a nationwide, population-based study. *Stroke* 45:1090–1095. <https://doi.org/10.1161/STROKEAHA.113.004273>.
- Mohan Mehndiratta M, Goyal I, Aggarwal V, Singh Gulati N. (2021) Moyamoya Disease Worldwide-Global Burden East and West. *IntechOpen*. doi: 10.5772/intechopen.96137.
- Scott RM, Smith ER. (2009) Moyamoya disease and moyamoya syndrome. *N Engl J Med*. 360(12):1226-1237.
- Fujimura M, Tominaga T. (2015) Diagnosis of moyamoya disease: international standard and regional differences. *Neurol Med Chir (Tokyo)*. 55(3):189-193.
- Im SH, Oh CW, Kwon OK, Cho BK, Chung YS, *et al.* (2004) Involuntary movement induced by cerebral ischemia: pathogenesis and surgical outcome. *J Neurosurg*. 100(5):877-82.
- Gonzalez NR, Amin-Hanjani S, Bang OY, Coffey C, Du R, *et al.* (2023) American Heart Association Stroke Council; Council on Cardiovascular and Stroke Nursing; and Council on Clinical Cardiology. Adult Moyamoya Disease and Syndrome: Current Perspectives and Future Directions: A Scientific Statement From the American Heart Association/American Stroke Association. *Stroke*. 54(10):e465-e479.
- Pandey P, Bell-Stephens T, Steinberg GK. (2010) Patients with moyamoya disease presenting with movement disorder: report of 4 cases. *J. Neurosurg. Pediatr.* 6 (6):559–566.
- Kraemer M, Diehl RR, Diesner F, Berlitz P, Khan N. (2012) Differential diagnosis between cerebral ischemia, focal seizures and limb shaking TIAs in moyamoya disease. *Br. J. Neurosurg*. 26 (6):896–898.
- Shang S, Zhou D, Ya J, *et al.* (2020) Progress in moyamoya disease. *Neurosurg Rev*. 43:371–2.