

Diagnostic performance of isolated-check visual evoked potential versus perimetry with blue-yellow in patients with open angle glaucoma

Li-Na Huang^{1,2*}, Chen Lin^{1,3,4*}, Peng Huang⁵, Qiu-Xia Xie², Cai-Xia Wang¹

引用:黄丽娜,林晨,黄鹏,等. 分离格栅视觉诱发电位与蓝黄视野检查诊断开角型青光眼的性能比较. 国际眼科杂志 2021; 21(5):745-749

Foundation items: Clinical Medical Technology Innovation Guidance Plan of Hunan Province (No.2017SK50903); Aier Eye Hospital Group Scientific Research Fund (No. AF1906D1); Shenzhen Knowledge Innovation Plan, Basic Research Project (No.JCYJ201703071550303786)

¹Shenzhen Aier Eye Hospital, Shenzhen 518000, Guangdong Province, China

²Affiliated Shenzhen Eye Hospital of Jinan University, Shenzhen 518000, Guangdong Province, China

³Aier School of Ophthalmology, Central South University, Changsha 518000, Hunan Province, China

⁴Department of Ophthalmology, Shenzhen People's Hospital, Shenzhen 518000, Guangdong Province, China

⁵Shenzhen University, Shenzhen 518000, Guangdong Province, China

Co-first authors: Li-Na Huang and Chen Lin

Correspondence to: Li - Na Huang. Shenzhen Aier Eye Hospital, Shenzhen 518000, Guangdong Province, China; Affiliated Shenzhen Eye Hospital of Jinan University, Shenzhen 518000, Guangdong Province, China. lina_h@126.com

Received: 2020-02-23 Accepted: 2021-01-14

分离格栅视觉诱发电位与蓝黄视野检查诊断开角型青光眼的性能比较

黄丽娜^{1,2*}, 林晨^{1,3,4*}, 黄鹏⁵, 谢秋霞², 王彩霞¹

基金项目: 湖南省临床医疗技术创新引导计划 (No. 2017SK50903); 爱尔眼科医院集团科研基金 (No. AF1906D1); 深圳市知识创新计划基础研究项目 (No. JCYJ201703071550303786) (作者单位: ¹518000 中国广东省深圳市, 深圳爱尔眼科医院; ²518000 中国广东省深圳市, 暨南大学附属深圳眼科医院; ³518000 中国湖南省长沙市, 中南大学爱尔眼科学院; ⁴518000 中国广东省深圳市人民医院眼科; ⁵518000 中国广东省深圳市, 深圳大学)

*: 黄丽娜与林晨对本文贡献一致。

作者简介: 黄丽娜, 毕业于中山医科大学, 博士研究生, 主任医师, 教授, 博士研究生导师, 研究方向: 青光眼; 林晨, 毕业于香港中文大学, 博士研究生, 副主任医师, 硕士研究生导师, 研究方向: 青光眼、眼底病。

通讯作者: 黄丽娜. lina_h@126.com

摘要

目的: 评估分离格栅视觉诱发电位 (IC-VEP) 在诊断开角型青光眼中的表现, 并将其与蓝黄色视野检查法 (B/YP) 和光学相干断层扫描 (OCT) 进行比较。

方法: 通过回顾性分析, 对来自中国的 101 例受试者 (正常组 35 例; 早期青光眼 30 例, 中晚期青光眼患者 36 例) 分别进行 IC-VEP、蓝黄色视野检查和 OCT 等检查。计算 IC-VEP、视野检查法和 OCT 对检测青光眼的敏感度以及这三种方法之间的一致性, 以评估其临床表现。

结果: 早期 POAG 组的 IC-VEP、蓝黄色视野检查和 OCT 的敏感度分别为 70.00%、70.00%、63.33%。在中晚期 POAG 组中, IC-VEP、OCT 和蓝黄色视野检查的敏感度分别为 86.11%、88.89%、91.67%。其中 IC-VEP 的特异性为 91.43%。IC-VEP 的结果与 OCT 和蓝黄色视野测试高度一致 (κ : 0.721~1.000, $P < 0.05$)。

结论: 作为视觉功能的客观检查手段, IC-VEP 可用于青光眼的早期诊断, 也可用于监测可疑青光眼患者的 RGC 功能。

关键词: 分离格栅视觉诱发电位; 视野检查; 青光眼; 光学相干断层扫描

Abstract

• **AIM:** To evaluate the diagnostic performance of the isolated-checked visual evoked potential (IC-VEP) in the detection of open angle glaucoma and compared it to the blue - yellow perimetry (B/YP) and optical coherent tomography (OCT).

• **METHODS:** In a retrospective analysis, IC - VEP, perimetry and OCT were performed on 101 subjects ($n = 35$, normal; $n = 30$, early glaucoma; $n = 36$, moderate and advanced glaucoma) from China. The sensitivity of IC - VEP, perimetry and OCT for detection of glaucoma, as well as the agreement within these 3 methods, were calculated to evaluate their clinic performance.

• **RESULTS:** In the early primary open angle glaucoma (POAG) group the sensitivity of IC - VEP, blue - yellow perimetry and OCT were 70.00%, 70.00% and 63.33%, respectively. In the moderate advanced POAG group, the sensitivity of IC - VEP, OCT and blue - yellow perimetry were 86.11%, 88.89% and 91.67%, respectively. The specificity of IC - VEP was 91.43%. The results of IC - VEP were highly consistent with OCT and blue - yellow visual field tests (κ : 0.721-1.000, $P < 0.05$).

• **CONCLUSION:** As an objective examination of visual

function, IC - VEP can be used for early diagnosis of glaucoma. It may be a useful tool for monitoring the function of RGCs in suspected glaucoma patients.

• **KEYWORDS:** isolated - checked visual evoked potential; perimetry; glaucoma; optical coherent tomography

DOI:10.3980/j.issn.1672-5123.2021.5.01

Citation: Huang LN, Lin C, Huang P, *et al.* Diagnostic performance of isolated - check visual evoked potential versus perimetry with blue - yellow in patients with open angle glaucoma. *Guoji Yanke Zazhi (Int Eye Sci)* 2021;21(5):745-749

INTRODUCTION

Glaucoma is an optic neuropathy characterized by progressive loss of retinal ganglion cells (RGCs) and their axons, changes in optic disc topography^[1-2], and associated defect of visual function^[2-3]. Early detection is important to initiate treatment in the early stages of glaucoma and to avoid its natural progression to blindness^[2]. Detection of the functional disorder of blue - yellow color vision would be a way for early detection of glaucoma^[4-7]. Besides of the blue - yellow perimetry, a kind of subjective visual field examination, isolated - checked visual evoked potential (IC - VEP) is a recently developed objective test to detect the damage of RGCs by evaluating the function of the blue - yellow color vision signal transduction pathway^[8-13]. The purpose of this study was to evaluate the clinical performance of the isolated - checked visual evoked potential (IC - VEP) in the detection of glaucoma and compared it to the blue - yellow perimetry (B/YP) and optical coherent tomography (OCT).

SUBJECTS AND METHODS

Participants Sixty - six primary open angle glaucoma (POAG) eyes from 66 patients (including early, moderate and advanced glaucoma) were recruited from Shenzhen Aier Eye Hospital from January 2018 to January 2019. POAG was defined by the presence of characteristic glaucomatous optic disc changes and corresponding visual field defects in 24 - II blue - on - yellow perimetry, together with increased intraocular pressure (>21 mmHg) and an open anterior chamber angle in gonioscopy. Secondary glaucoma (*e.g.* uveitic glaucoma) was excluded. Early glaucoma, moderate glaucoma and advanced glaucoma were graded according to the criteria of Hodapp - Anderson - Parrish (HAP)^[2]. Thirty - five eyes of 35 healthy individuals were recruited from the same hospital from January 2018 to January 2019. All individuals showed no optic disc or RNFL abnormalities on clinical examination, and no history of retinal disease, eye surgery, laser procedures, diabetes mellitus or neurologic disease. The best - corrected visual acuity (BCVA) of these individuals were not worse than 20/40 and their spherical refractive error was within the range of -6.00 DS to +3.00 DS. This study was carried out in accordance with the tenets of the Declaration of Helsinki, and after the approval the Ethics Committee.

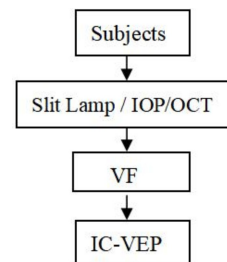


Figure 1 Flow chart of the order of tests The tests of Slit lamp, OCT, visual field and IC - VEP were performed in sequence. At least 15min rest was arranged before VF and IC - VEP test to avoid the fatigue effects and to ensure the accuracy and reliability of these tests.

Isolated - checked Visual Evoked Potential IC - VEP examination was performed using the isolated grid pattern of Neucodia electrophysiologic instrument (Medconova Corp., Huzhou, China). The pupil of the examined eye was parallel to the center of the stimulus pattern and had a distance of 70 cm. The whole stimulus process was 96s, divided into 8 cycles. If significant noise or artifacts from the eye movement occurred during a cycle, the system rejected the extreme signals, and the measurements were automatically repeated and rerecorded. Each subject was examined twice, with an interval of more than 10min. The reliable results were included in the final analysis. The signal - to - noise ratio (SNR), defined as a circle of confidence in the radius of the fundamental component of the average amplitude ratio, was used for the judgment of glaucoma. If the SNR was less than 1, which meant the electrophysiologic response from the RGCs was not higher than the background noise, the abnormality of IC - VEP results was recorded for this test. IC - VEP test will be repeated after 10min if the abnormality results were found. The eye with two consecutive results of $SNR \leq 1$ was recorded as glaucomatous eye (Figure 1).

Blue - on - yellow Perimetry Blue - on - yellow perimetry was performed by 24 - II blue - yellow total threshold procedure and SITA - standard program of Humphry 750 perimetry (Carl Zeiss Meditec, Inc. USA). Criteria for blue - yellow visual field abnormalities: 1) three or more adjacent points decreased in light sensitivity by 7 dB or more; 2) two or more adjacent points decreased in light sensitivity by 7 dB or more in one point and 10 dB or more in the other; 3) the difference in light sensitivity between two or more adjacent points above or above the horizontal line on the nasal side was 10 dB or more; 4) three or more adjacent points proofread less than 5%. The classification of glaucoma visual field was based on HAP standard.

Spectral Domain Optical Coherence Tomography The parapapillary retinal nerve fiber layer (RNFL) thickness and GC - IPL thickness in macular zone were measured by the Cirrus SD - OCT (software version 5.0, Carl Zeiss Meditec, Dublin, CA, USA) using the optic disc and macular scan mode (200×200 A - scans covering an area of 6×6 mm² centered

Table 1 Demographic information of the normal and POAG groups

Parameters	Early POAG(<i>n</i> = 30)	Moderate/Advanced POAG(<i>n</i> = 36)	Normal subjects (<i>n</i> = 35)
Age, y	34.87±3.76 ^a (20–80)	44.10±5.23 ^a (20–70)	28.43±4.02 ^a (20–50)
Gender (M/F)	17/13	24/12	16/19
Spherical equivalent, D	-2.26±0.98	-1.86±0.54	-1.26±0.51
BCVA (LogMAR)	0.87±0.18 ^a	0.85±0.21 ^a	0.92±0.13
Intraocular pressure, mmHg	16.20±3.80	17.40±4.30 ^a	15.70±2.60
Cup/Disc ration (C/D)	0.53±0.15 ^a	0.82±0.14 ^a	0.31±0.14
Average RNFL thickness (μm)	74.70±11.50	46.50±9.60	102.70±10.60
Average GC-IPL thickness (μm)	62.30±10.80	46.80±9.80	-

POAG; Primary open angle glaucoma; BCVA; Best-corrected visual acuity; RNFL; Retinal nerve fiber layer; ^a*P*<0.05 vs Normal subjects.

Table 2 Performance of IC-VEP, blue-yellow perimetry and OCT in detection of POAG and normal subjects

Items	IC-VEP		Blue-yellow perimetry		OCT	
	+	-	+	-	+	-
Early POAG	21	9	21	9	19	11
Moderate/Advanced POAG	31	5	33	3	32	4
Normal subjects	3	32	/	/	/	/

“+” : Abnormal; “-” : Normal; POAG; Primary open angle glaucoma.

on the optic disc and macular zone). The requirement for image quality was signal strength >6. The average RNFL and GC-IPL thickness was recorded for analyzing.

Statistical Analysis Statistical analyses were performed using SPSS 24.0 (IBM Corp., New York, USA) and STATA 14.0 (Stata Corp., Texas, USA). The significance of the differences in age, refraction, gender, BCVA, intraocular pressure, and C/D ratio was determined by the independent-sample *t*-test and Chi-squared test. The sensitivity of IC-VEP, perimetry and OCT for detection of glaucoma was calculated; the agreement between IC-VEP, perimetry and OCT was calculated with kappa statistics^[14]. *P* < 0.05 was considered statistically significant.

RESULTS

Totally 66 glaucomatous eyes from 66 POAG patients and 35 normal eyes from 35 healthy subjects were enrolled in this study: 30 eyes were assigned to the early glaucoma group, 36 eyes were assigned to the moderate/advanced glaucoma group, and 35 eyes were assigned to the control group. The demographic characteristics of the study participants are summarized in Table 1. The spherical equivalent and gender distribution were not significantly different between the normal and POAG groups (*P*>0.05). Compared to the normal group, the C/D ratio was significantly higher in the POAG groups, the average-RNFL thickness was significantly lower in the POAG groups (*P*<0.05).

Performance of IC-VEP, Blue-yellow Perimetry and OCT in Detection of POAG In the early POAG group, 21 eyes (70.00%) on IC-VEP, 21 eyes (70.00%) on blue-yellow perimetry and 19 eyes (63.33%) on OCT were detected as abnormal. In the moderate/advanced POAG group, 31 eyes (86.11%) on IC-VEP, 33 eyes (91.67%) on blue-yellow perimetry and 32 eyes (88.89%) on OCT

were detected as abnormal. In the normal subjects, 32 eyes (91.43%) on IC-VEP were detected as normal (Table 2). For both early and advanced glaucoma groups, the sensitivity of IC-VEP was 74.24%, and the specificity was 91.43%; the sensitivity of GC-IPL detection of OCT and blue-yellow perimetry were 77.27% and 81.82%, respectively.

Agreement Between IC-VEP, Blue-yellow Perimetry and OCT

Within the 30 eyes in early POAG group, 19 eyes were detected as abnormal by both OCT and IC-VEP (Kappa = 0.851, 95% CI = 0.530–0.958, *P* < 0.001), 21 eyes were detected as abnormal by both blue-yellow perimetry and IC-VEP (Kappa = 1.000, 95% CI = 0.736–1.000, *P* < 0.001), 19 eyes were detected as abnormal by both blue-yellow perimetry and OCT (Kappa = 0.851, 95% CI = 0.530–0.958, *P* < 0.001), 19 eyes were detected as abnormal by IC-VEP, blue-yellow perimetry and OCT (Kappa = 0.898, 95% CI = 0.672–0.972, *P* < 0.001) (Figure 2A). Within the 36 eyes in moderate/advanced POAG group, 31 eyes were detected as abnormal by both OCT and IC-VEP (Kappa = 0.873, 95% CI = 0.450–0.977, *P* < 0.001), 31 eyes were detected as abnormal by both blue-yellow perimetry and IC-VEP (Kappa = 0.721, 95% CI = 0.271–0.921, *P* < 0.001), 32 eyes were detected as abnormal by both blue-yellow perimetry and OCT (Kappa = 0.842, 95% CI = 0.366–0.972, *P* < 0.001), 31 eyes were detected as abnormal by IC-VEP, blue-yellow perimetry and OCT (Kappa = 0.813, 95% CI = 0.410–0.949, *P* < 0.001) (Figure 2B). Thus, in both groups, the results of IC-VEP was highly consistent with OCT and blue-yellow visual field test.

DISCUSSION

At present, there are more than 22 million glaucoma patients aged 40 years and above in China; by 2050, the glaucoma cases in China will increase to 25 million^[15–16]. Patients in the

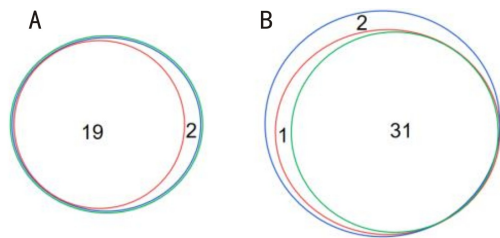


Figure 2 Venn diagrams showed the agreement of IC-VEP, perimetry and OCT in the early POAG group (A) and the moderate/advanced POAG group (B) Red circle; GC-IPL detection of OCT; Green; IC-VEP, Blue; blue-yellow perimetry.

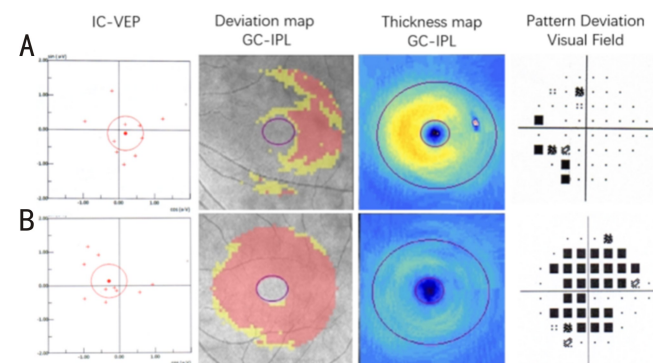


Figure 3 Two individuals with the abnormal results of IC-VEP A: a 51 years old male with early glaucoma (SNR: 0.44; average GC-IPL thickness: 72 μm ; mean deviation of visual field test: -3.95 dB); B: a 48 years old female with advanced glaucoma (SNR: 0.61; average GC-IPL thickness: 51 μm ; mean deviation of visual field test: -21.21 dB).

early stage of glaucoma are often asymptomatic; when obvious symptoms are detected, a significant deficiency of visual function are already irreversible^[2,17]. Thus, early diagnosis of glaucoma is an important step to preserve the visual function. OCT, as well as blue-yellow perimetry and IC-VEP have been developed for early detection of glaucoma by evaluating structure loss or functional disorder of RGCs, which is the characteristic pathological change of glaucomatous eyes^[8,18]. Visual signals are transmitted by a special type of cell in the retina called the retinal ganglion cell (RGC). The RGCs can be categorized into M cells with larger cell bodies and P cells with smaller cell bodies^[19]. The early manifestation of glaucoma is the function loss of the M-type RGCs^[20]. The IC-VEP, which selectively stimulate M cell by separating grating pattern stimulation and evaluate the function of signal transduction pathway of M cells, would be a useful tool for the early detection of glaucoma^[8-10]. In our study, we found that the sensitivity and specificity of IC-VEP for detecting early glaucoma were 70% and 91% respectively.

Studies showed that glaucoma patients have color vision disorders before the visual field changes, especially blue-yellow color vision disorders^[7]. In our study, we also found that IC-VEP could objectively detect early glaucoma with the same sensitivity (70.00%) of blue-yellow perimetry. Compared to GC-IPL detection of OCT, IC-VEP would be more sensitive for the detection of early glaucoma (70.00% vs

63.33%). For the moderate and advanced glaucoma, the performance of these 3 methods was similar. For early to advanced stages of glaucoma, the agreement between IC-VEP, blue-yellow perimetry and OCT is high.

There are limitations to our study. 1) It was a single-center clinical study with limited the sample size (around 30 cases in each group); 2) Since the examinations of blue-yellow perimetry and OCT were not performed in normal subjects, the specificity between IC-VEP, perimetry, and OCT cannot be compared. Multi-center study and longitudinal observation are still needed to further verify the clinical diagnostic efficacy of IC-VEP; 3) The age and BCVA of 3 groups (early glaucoma, moderate and advanced glaucoma and control group) did not match with each other, these factors may have slight influence on the results of IC-VEP, perimetry and OCT. Thus, the performance of the specificity of IC-VEP may be slightly different in the age-matched normal subjects.

To sum up, IC-VEP is an objective examination of visual function. By indirectly detecting the function loss of M-cell of RGCs, it can be used for early diagnosis of glaucoma. Regular monitoring of RGCs with IC-VEP may be likely to be pivotal to inform diagnosis decisions for suspected glaucoma patients.

REFERENCES

- 1 Kwon YH, JH Fingert JH, Kuehn MH, Alward WLM. Primary open-angle glaucoma. *The New England Journal of Medicine* 2009;360:1113-1124
- 2 Weinreb RN, Khaw PT. Primary open-angle glaucoma. *Lancet* 2004;363(9422):1711-1720
- 3 Sasaoka M, Nakamura K, Shimazawa M, Ito Y, Araie M, Hara H. Changes in visual fields and lateral geniculate nucleus in monkey laser-induced high intraocular pressure model. *Exp Eye Res* 2008;86(5):770-782
- 4 Ly T, Gupta N, Weinreb RN, Kaufman PL, Yücel YH. Dendrite plasticity in the lateral geniculate nucleus in primate glaucoma. *Vision Res* 2011;51(2):243-250
- 5 Castelo-Branco M, Faria P, Forjaz V, Kozak LR, Azevedo H. Simultaneous comparison of relative damage to chromatic pathways in ocular hypertension and glaucoma: correlation with clinical measures. *Invest Ophthalmol Vis Sci* 2004;45(2):499-505
- 6 Papaconstantinou D, Georgalas I, Kalantzis G, Karmiris E, Koutsandrea C, Diagourtas A, Ladas I, Georgopoulos G. Acquired color vision and visual field defects in patients with ocular hypertension and early glaucoma. *Clin Ophthalmol* 2009;3:251-257
- 7 Zhong YS, Chen LP, Cheng Y, Huang P. Correlation between blue-on-yellow perimetry and scanning laser polarimetry with variable corneal compensation measurements in primary open-angle glaucoma. *Jpn J Ophthalmol* 2009;53(6):574-579
- 8 Chen XW, Zhao YX. Diagnostic performance of isolated-check visual evoked potential versus retinal ganglion cell-inner plexiform layer analysis in early primary open-angle glaucoma. *BMC Ophthalmol* 2017;17(1):77
- 9 Chen XW, Zhao YX. Comparison of isolated-check visual evoked potential and standard automated perimetry in early glaucoma and high-risk ocular hypertension. *Int J Ophthalmol* 2017;10(4):599-604

- 10 Xu LJ, Zhang L, Li SL, Zemon V, Virgili G, Liang YB. Accuracy of isolated-check visual evoked potential technique for diagnosing primary open-angle glaucoma. *Documenta ophthalmologica. Advances in ophthalmology* 2017;135(2): 107-119
- 11 Fan X, Wu LL, Ding AH. Assessing early stage open-angle glaucoma in patients by isolated-check visual evoked potential. *J Vis Exp* 2020;159
- 12 Qi X, Tong BD, Hu WK, Luo B. Comparing isolated-check visual evoked potential, pattern visual evoked potential, and standard automated perimetry in dysthyroid optic neuropathy eyes. *Eye* 2020;1-8
- 13 Tian YJ, Wang YH, Liu ZY, Li XM. Isolated-check visual evoked potential: a more sensitive tool to detect traumatic optic neuropathy after orbital fracture. *Graefes Archive for Clinical and Experimental Ophthalmology* 2021;259:547-555
- 14 Landis JR, Koch GG. The measurement of observer agreement for categorical data. *Biometrics* 1977;33(1):159-174
- 15 Jonas JB, George R, Asokan R, Flaxman SR, Keeffe J, Leasher J, Naidoo K, Pesudovs K, Price H, Vijaya L, White RA, Wong TY, Resnikoff S, Taylor HR, Bourne RR, Vision Loss Expert Group of the Global Burden of Disease Study. Prevalence and causes of vision loss in Central and South Asia: 1990-2010. *Br J Ophthalmol* 2014;98(5): 592-598
- 16 Song PG, Wang JW, Bucan K, Theodoratou E, Rudan I, Chan KY. National and subnational prevalence and burden of glaucoma in China: a systematic analysis. *J Glob Health* 2017;7(2):020705
- 17 Tham YC, Li X, Wong TY, Quigley HA, Aung T, Cheng CY. Global prevalence of glaucoma and projections of glaucoma burden through 2040: a systematic review and Meta-analysis. *Ophthalmology* 2014;121(11):2081-2090
- 18 Hou HW, Lin C, Leung CK. Integrating macular ganglion cell inner plexiform layer and parapapillary retinal nerve fiber layer measurements to detect glaucoma progression. *Ophthalmology* 2018;125(6):822-831
- 19 Gupta N, Ang LC, Noël de Tilly L, Bidaisee L, Yücel YH. Human glaucoma and neural degeneration in intracranial optic nerve, lateral geniculate nucleus, and visual cortex. *Br J Ophthalmol* 2006;90(6): 674-678
- 20 Harwerth RS, Carter-Dawson L, Shen F, Smith EL 3rd, Crawford ML. Ganglion cell losses underlying visual field defects from experimental glaucoma. *Invest Ophthalmol Vis Sci* 1999;40(10):2242-2250