

## ORIGINAL ARTICLE

### CD56 expression in benign and malignant thyroid lesions

Santhia MUTHUSAMY<sup>1</sup>, Shamsul AZHAR SHAH<sup>2</sup>, Shahrin Niza ABDULLAH SUHAIMI<sup>3</sup>, Norina KASSIM<sup>4</sup>, Mazne MAHASIN<sup>1</sup>, Muhammad Fakhri MOHD SALEH<sup>1</sup> and Nurismah MD ISA<sup>1</sup>

<sup>1</sup>Department of Pathology, Universiti Kebangsaan Malaysia (UKM) Medical Centre, Kuala Lumpur, Malaysia, <sup>2</sup>Department of Community Health, Universiti Kebangsaan Malaysia (UKM) Medical Centre, Kuala Lumpur, Malaysia, <sup>3</sup>Department of Surgery, Universiti Kebangsaan Malaysia (UKM) Medical Centre, Kuala Lumpur, Malaysia, <sup>4</sup>Department of Pathology, Hospital Tengku Ampuan Rahimah (HTAR), Klang, Selangor, Malaysia.

#### Abstract

**Introduction:** Thyroid cancer is the most common endocrine malignancy with more than 95% originating from follicular epithelial cells. Diagnostic dilemma may arise in occasional cases such as when an encapsulated nodule with a follicular growth pattern exhibits clear nuclei with grooves making it difficult to distinguish a follicular adenoma from encapsulated follicular variant papillary thyroid carcinoma. This study aimed to evaluate the diagnostic utility of an immunohistochemical marker, CD56, to distinguish between benign and malignant thyroid lesions. **Materials and Methods:** We retrospectively studied CD56 expression in 54 benign and 54 malignant thyroid lesions using archival formalin fixed paraffin-embedded tissue blocks for the study period from January 2010 to December 2015, diagnosed in a tertiary hospital. **Results:** CD56 was expressed in 52/54 (96.3%) of benign specimens and only 24/54 (44.4%) of malignant ones. The malignant specimens comprised 31 (57.4%) papillary thyroid carcinomas (PTC), 11 (20.3%) follicular carcinomas (FC), seven (13%) medullary thyroid carcinomas (MC), one (1.9%) poorly differentiated carcinoma (PC) and four (7.4%) anaplastic carcinomas (AC). CD56 was not expressed in 28/31 (90.3%) of the PTCs, 1/11 (9.1%) FCs, 1/4 (25%) of ACs while all MCs and the PD were positive. The benign group comprised nodular hyperplasias (29/54), lymphocytic thyroiditis (10/54), follicular adenomas (FA) (14/54) and one hyalinising trabecular tumour. CD56 was expressed in all the benign cases except one FA and one nodular hyperplasia. Thirteen of the 14 FAs were CD56 positive. The difference in expression between benign and malignant tumours was statistically significant as the p value was <0.01. **Conclusion:** CD56 is a potentially good immunohistochemical marker for differentiating papillary thyroid carcinoma from other benign follicular lesions of the thyroid especially in differentiating follicular variant PTC from FA in equivocal cases.

**Keywords:** CD56, papillary thyroid carcinoma, follicular adenoma, benign thyroid lesions

#### INTRODUCTION

Thyroid nodules are extremely common in the general population and are usually discovered during routine medical check-up. It is estimated that up to 7% of the general population develops clinically palpable thyroid nodules.<sup>1</sup> Most thyroid nodules are benign with thyroid cancer representing 5-24% of these nodules.<sup>1</sup> Thyroid tumours are the most common endocrine tumours in the United States, and about 40% of the population between 30 and 60 years old have thyroid nodules, most of which are benign.<sup>2</sup>

However, increase in thyroid cancer incidence has been reported in the last thirty years by different studies.<sup>1</sup>

More than 95% of thyroid carcinomas originate from follicular epithelial cells. The incidence of thyroid carcinomas derived from follicular cells varies worldwide depending on dietary iodine intake, but in most countries it has increased during the past few decades and in North America it is one of the most rapidly increasing cancers, representing a major cause of morbidity in premenopausal women.<sup>3</sup> Between

1996 and 2008, an increasing incidence of papillary thyroid carcinoma was reported in Denmark, with age-standardised incidence rates increasing from 1.43 per 100 000 per year in 1996 to 2.16 per 100 000 per year in 2008.<sup>4</sup>

According to the Malaysian Cancer Statistics 2006, thyroid cancer was more common among females compared to males in Peninsular Malaysia.<sup>5</sup> The peak age of diagnosis among males was 60-69 and among females was 50-59. The incidence of thyroid cancer was highest among the Malay population followed by the Chinese and the Indians.<sup>5</sup>

Papillary thyroid carcinoma (PTC) is the most common of the well differentiated thyroid carcinomas (85%) and is characterised by distinctive nuclear features such as enlarged ovoid nucleus, irregular nuclear membrane, powdery chromatin, longitudinal grooves and intranuclear cytoplasmic inclusion. Variants of papillary carcinoma include the classical subtypes with papillary architecture; the follicular variant PTC that lacks papillae but retains classical nuclear atypia; oncocytic tumours that can have either papillary or follicular architecture associated with the nuclear features of PTC and oncocytic cytoplasm; and tall-cell, solid, and cribriform types. Metastasis to regional lymph nodes may occur in up to 50% of cases of papillary thyroid neoplasms.<sup>3</sup>

The 'gold standard' in diagnosis of thyroid nodules is pathologic evaluation using routine haematoxylin and eosin (H&E) staining. However, overlapping morphological features among follicular lesions especially the follicular variant of papillary carcinoma (FVPC) is common, the latter of which is characterised by an almost exclusive follicular growth pattern and a set of nuclear features identical to those of the classic type of papillary thyroid carcinoma. Diagnostic dilemma may arise when an encapsulated nodule with a follicular pattern of growth exhibits clear nuclei with grooves therefore distinguishing follicular adenoma (FA) from encapsulated follicular variant papillary thyroid carcinoma becomes difficult.<sup>6-9</sup> Consequently, some tumours are required to be included in the category of thyroid tumours of uncertain malignant potential (TTs-UMP). TT-UMP is a newly described, controversial entity, referring to a borderline lesion that shows questionable, incomplete papillary thyroid carcinoma nuclear features and/or capsular and vascular invasion. Large intra and interobserver variability among expert pathologists in the

diagnosis of these lesions is well-documented in the literature.<sup>1</sup>

The diagnosis of thyroid tumours in typical cases is relatively straightforward, however, there are cases of malignant tumours in which differential diagnosis from benign lesions is not easy. In such cases, diagnosis by a histopathologic study may be impossible even for expert pathologists and reproducibility of the diagnosis may not be acceptable among various pathologists. Thus, it is critical to find appropriate markers to differentiate among thyroid neoplasms, especially malignant tumours and benign lesions, since incorrect diagnosis can lead to total thyroidectomy and lifelong dependency for medical treatment.<sup>10</sup>

CD56 is a cell surface glycoprotein in which this marker is constitutionally expressed in normal thyroid follicular cells and is preserved in almost all benign thyroid tumour cells. Decreased expression of CD56 has frequently been found in malignant thyroid tumours, especially in papillary thyroid carcinoma, and this has resulted in exploring its diagnostic utility and pathogenic connections among thyroid carcinomas.<sup>11</sup> Scarpino reported the potential involvement of CD56 in thyroid tumour lymphangiogenesis by modulation of the expression of vascular endothelial growth factor (VEGF).<sup>12</sup> They also found that CD56-silenced thyroid cancer cells had downregulation of VEGF and were more adhesive to extracellular matrix and less efficient in migration and invasion.<sup>12</sup>

The aim of this study was to evaluate the diagnostic utility of the immunohistochemical marker, CD56, to distinguish between benign and malignant thyroid lesions and to correlate it with clinicopathological parameters.

## MATERIALS AND METHODS

### *Patients and tissue samples*

This is a retrospective study on 108 specimens of surgically removed, formalin-fixed and paraffin embedded thyroid lesions that were received at the Department of Pathology, University Kebangsaan Malaysia Medical Centre (UKMMC), from January 2010 to December 2015. The 54 selected malignant cases include 31 papillary thyroid carcinomas, 11 follicular carcinomas, seven medullary thyroid carcinomas, one case of poorly differentiated carcinoma and four anaplastic carcinomas. The 54 benign thyroid lesions included 29 nodular hyperplasia/hyperplastic nodules, 10 lymphocytic thyroiditis, 14 follicular adenoma and one hyalinising

trabecular adenoma. The histopathological diagnosis was made according to the World Health Organization classification of tumours of endocrine organs 2004. Each case was reviewed by a trainee and a pathologist. The most representative slide and its corresponding paraffin block for each case was selected for immunohistochemical staining with CD56.

#### *Immunohistochemistry staining method*

All 108 samples (54 malignant and 54 benign thyroid lesions) were subjected to immunohistochemical staining with CD56 antibody.

Immunohistochemistry staining was performed on tissue sections using the protocol from EnVision™ FLEX<sup>+</sup>, Mouse, High pH (Code No. K8012, Dako Denmark) and EnVision™ FLEX<sup>+</sup> Mouse Linker (Code No. DM824, Dako Denmark). The primary antibody used was monoclonal mouse anti-human CD56 antigen clone 123C3 (Code No. M7304, Dako Denmark). Primary antibodies were diluted to optimal concentration (1:50) using Antibody Diluent, Dako REAL™ (Code No. S0809, Dako Denmark). Washing steps between each reagent were performed using EnVision™ FLEX Wash Buffer 20X (Code No. DM831, Dako Denmark) diluted to a 1X working solution with deionized water. The 1X DAB-containing Substrate Working Solution was prepared by diluting the 50X concentrated EnVision™ FLEX DAB+ Chromogen (Code No. DM827, Dako Denmark) with Envision™ FLEX™ Substrate Buffer (Code No. DM823, Dako Denmark).

Tissue blocks were sectioned approximately 3 µm thickness and mounted on adhesive glass slide, Platinum Pro White (Product No: PRO-01, Matsunami Japan). The slides were left to be air-dried in room temperature overnight. The tissue slides were then incubated on hot plate at 60°C for 1 hour. An initial deparaffinization and pre-treatment step was performed in the Dako PTLINK (Product No. PT10126, DakoCytomation, USA) using the EnVision™ FLEX Target Retrieval Solution, High pH (Code No. DM828, Dako Denmark) at 95°C for 20 minutes followed by cooling at room temperature for another 20 minutes and rinsed with running tap water for 3 minutes. The slides were subsequently incubated with EnVision™ FLEX Peroxidase-Blocking Reagent (Code No. DM821, Dako Denmark) for 5 minutes followed by washing step.

Slides were then incubated with primary antibody at room temperature for 30 minutes

followed by incubation with EnVision™ FLEX<sup>+</sup> Mouse (Linker) for 20 minutes followed by incubation with second antibody EnVision™ FLEX/HRP (Code No. DM822, Dako Denmark) for 20 minutes. Sections were then incubated with 1X DAB-containing Substrate Working Solution for 10 minutes. The slides were then counterstained with haematoxylin 2 (REF 7231, ThermoScientific USA) for 5 seconds after the procedures have been completed followed by dehydration step with increasing alcohol solutions (80%, 90%, 100% and 100%) and 2-times Xylene. Finally, the slides were mounted and coverslipped using DPX mounting medium (Cat. No.: 100579, Merck Milipore Germany).

#### *Interpretation of immunohistochemical staining of CD56*

The results of immunohistochemical staining were assessed by two researchers (SM and NMI) independently. In cases with discrepancy, a final score was determined by consensus after reexamination.

According to previous studies, strong and complete membranous expression with or without cytoplasmic staining of the tumour cells qualified the case as positive for CD56.<sup>1,13-14</sup> Occasional cytoplasmic staining of tumour cells were disregarded, and only staining of the tumour cell membranes were considered to be specific. CD56 often showed strong and complete membranous expression in benign thyroid follicular cells, especially the benign cells adjacent to tumour regions.

Results were expressed in a semiquantitative manner with respect to the percentage of positive tumour cells: 0, staining in < 10% of the lesional cells; 1+, staining in 10-25% of the lesional cells; 2+, staining in 26-50% of the lesional cells; 3+, staining in > 50% of the lesional cells (Fig. 1). The percentage of positive cells for each section was counted under 5 high power field, and the mean value of each case was scored.<sup>13</sup>

A score of 0 was considered as negative, and scores of 1- 3 were considered as positive for CD56.<sup>13</sup> Since CD56 is a marker whose expression is reduced or absent in thyroid carcinoma, a 'malignant' profile was considered when the tumour was entirely or almost entirely negative for this antibody (less than 10 % of tumour cells stained positively), while a "benign" result was considered when more than 10% of the tumour cells stained positively.

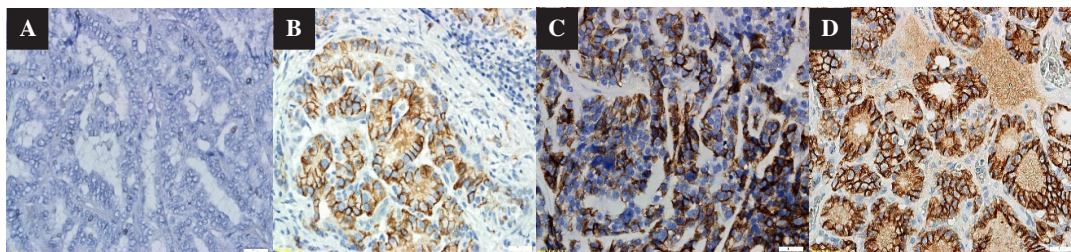


FIG. 1: The degree of intensity of CD56 immunohistochemical staining (A) 0 (negative) (B) 1+ (positive) (C) 2+ (positive) and (D) 3+ (positive).

#### Data processing and analysis

All data and results were processed and analysed statistically using Statistical Package for Society Study (SPSS) version 21.0 statistic software.

Qualitative data were presented using the frequency and related percentage. Comparison of qualitative variables between groups and statistical analyses of the results were done using the Chi-square or the Fisher Exact test. A "P" value of <0.05 was considered statistically significant with confidence interval of 95%.

## RESULTS

#### Epidemiological and clinicopathological data

A total of 108 patients from year 2010 until 2015 in UKMCMC underwent thyroid surgical resection and had histologically confirmed malignant and benign thyroid lesions. The majority of patients were Malay (66/108, 61%) followed by Chinese (24/108, 22%), Indians (11/108, 10%) and others (7/108, 7%). There were 76 females compared to 32 males, with female to male ratio of 2.3:1. We found that the various benign and malignant thyroid lesions did not show significant correlation with age, gender and lymph node status (Tables 1 and 2).

#### CD56 protein expression

Of the 54 malignant thyroid lesions, 14 (25.9%) were scored as 3+, two (3.7%) 2+ and eight (14.8%) had a score of 1+. The remaining 30 (55.6%) cases were scored 0 (Fig. 2). From 54 benign thyroid lesions, 34 (63%) were scored as 3+, 10 (18.5%) 2+ and eight (14.8%) had a score of 1+. The remaining two (3.7%) cases were scored 0.

#### CD56 in thyroid lesions

CD56 expression was studied in 54 benign and 54 malignant thyroid lesions. CD56 was expressed in 52/54 (96.3%) of benign specimens and only 24/54 (44.4%) of malignant ones. Of the 54 malignant cases, 31 (57.4%) were papillary thyroid carcinomas (PTC), 11

(20.3%) follicular carcinomas (FC), 7 (13.0%) medullary thyroid carcinomas (MC), one (1.9%) poorly differentiated carcinoma (PD) and four (7.4%) anaplastic carcinomas (AC). CD56 was not expressed in 28/31 (90.3%) of the PTCs, 1/11 (9.1%) follicular carcinomas, 1/4 (25%) of anaplastic thyroid carcinomas while all medullary carcinomas and the poorly differentiated carcinomas were positive (Table 3). CD56 was expressed in all the benign cases except one follicular adenoma and one nodular hyperplasia. Thirteen of the 14 follicular adenomas were CD56 positive (Table 4, Fig. 2). The difference in expression between benign and malignant tumours was statistically significant as the p score was <0.01.

## DISCUSSION

The diagnosis of thyroid tumours in most cases is relatively easy, but there are cases of malignant tumours in which differential diagnosis from benign lesions is not easy. In such cases, diagnosis by a histopathological evaluation may be impossible even for expert pathologists. The present study revealed that CD56 is expressed in normal thyroid follicular cells with frequent low expression in malignant thyroid tumours, with papillary thyroid carcinoma being especially negative for CD56. CD56 is a neural cell adhesion molecule and its expression may affect the migratory capability of tumour cells. Hence it is not surprising that loss of CD56 correlates with metastatic potentials and poor prognostic outcome in some malignancies. Park (2009)<sup>14</sup> and Shin MK (2011)<sup>17</sup> showed that CD56 has an important role as a negative diagnostic marker for papillary thyroid carcinoma and differentiation from other malignant and benign thyroid lesions. CD56 showed strong and complete membrane expression in benign follicular cells, whereas it was absent in papillary thyroid carcinoma.<sup>13</sup> According to Park (2009)<sup>14</sup>, strong and complete membranous expression with or without cytoplasmic staining of the cells, in more

TABLE 1: Clinicopathological data distribution of malignant thyroid lesions

Clinico-pathological Data	Parameters	Diagnosis												p Value
		Papillary thyroid carcinoma		Follicular carcinoma		Medullary thyroid carcinoma		Poorly differentiated carcinoma		Anaplastic thyroid carcinoma		n	%	
		n	%	n	%	n	%	n	%	n	%			
Age	<55 years	16	51.6	5	45.0	4	57.1	0	0.0	2	50.0	1.000		
	≥55 years	15	48.4	6	54.5	3	42.9	1	100	2	50.0			
Gender	Female	18	58.1	10	90.9	4	57.1	1	100	2	50.0	0.234		
	Male	13	41.9	1	9.10	3	42.9	0	0.0	2	50.0			
Ethnicity	Malay	20	64.5	8	72.7	2	28.6	0	0.0	4	100	0.282		
	Chinese	6	19.4	1	9.1	3	42.9	1	100	0	0.0			
	Indian	2	6.5	2	18.2	1	14.3	0	0.0	0	0.0			
	Others	3	9.7	0	0	1	14.3	0	0.0	0	0.0			
Tumour stage	1	6	19.4	4	36.4	2	28.6	0	0.0	0	0.0	0.126		
	2	8	25.8	7	63.6	3	42.9	0	0.0	0	0.0			
	3	16	51.6	0	0	2	28.6	1	100	0	0.0			
	4	1	3.2	0	0	0	0.0	0	0.0	4	100			
Lymph node status	Positive	11	35.5	1	9.1	4	57.1	0	0.0	1	25.0	0.076		
	Negative	6	19.3	2	18.2	1	14.3	0	0.0	0	0.0			
	Not available	14	45.2	8	72.7	2	28.6	1	100	3	75.0			
Total		31	100	11	100	7	100	1	100	4	100	54		

**TABLE 2: Clinicopathological correlation of benign thyroid lesions and CD56 expression in tissue specimens**

Clinico-pathological data	Parameters	Diagnosis								p Value of CD56
		Follicular adenoma		Lymphocytic thyroiditis		Hyalinising trabecular tumour		Nodular hyperplasia		
		n	%	n	%	n	%	n	%	
Age	<55 years	11	78.6	3	30.0	1	100	16	55.2	0.080
	≥55 years	3	21.4	7	70.0	0	0.0	13	44.8	
Gender	Female	10	71.4	9	90.0	1	100	21	72.4	0.718
	Male	4	28.6	1	10.0	0	0.0	8	27.6	
Ethnicity	Malay	11	78.6	3	30.0	0	0.0	18	62.1	0.038
	Chinese	2	14.3	4	40.0	1	100	6	20.7	
	Indian	0	0.0	1	10.0	0	0.0	5	17.2	
	Others	1	7.1	2	20.0	0	0.0	0	0.0	
<b>Total</b>		14	100	10	100	1	100	29	100	

than 10% of the tumour cells qualified the case as positive for CD56.

Among the benign thyroid lesions, positive CD56 expression was observed in 52/54 cases (96.3%). Most of the positive cases displayed moderate to strong CD56 expression (score 2+ to 3+). There was no statistical significant difference found among this group (benign thyroid lesions) as regards to CD56 expression (P=0.189). These findings are in accordance to previous study by Shahebrahimi (2013)<sup>10</sup> which reported a high positive CD56 expression in 92.3% of benign

thyroid lesions. Alshenawy (2013)<sup>6-7</sup> and Atti (2012)<sup>18</sup> also reported that among the benign group, all of the positive cases displayed strong CD56 expression (score 3+) with no statistical significant difference found among this group as regards to CD56 expression (P=0.9).

Among the malignant thyroid lesions, positive CD56 expression was observed in only 24/54 cases (44.4%). There is statistically significant difference found among this group with regards to CD56 expression (P = <0.01), contrary to study by Alshenawy (2013)<sup>6-7</sup> which showed

**TABLE 3: CD56 expression in malignant thyroid lesions**

Types of malignant thyroid lesions	CD56 negative	CD56 positive			Total (%)
		1+	2+	3+	
Papillary thyroid carcinoma n (%)	28/31 (90.3%)	2/31 (6.5%)	1/31 (3.2%)	0/31 (0%)	3/3/31 (9.6%)
Follicular carcinoma n (%)	1/11 (9.1%)	5/11 (45.45%)	0/11 (0%)	5/11 (45.45%)	10/11 (90.0%)
Medullary carcinoma n (%)	0/7 (0%)	0/7 (0%)	0/7 (0%)	7/7 (0%)	7/7 (100%)
Anaplastic thyroid carcinoma n (%)	1/4 (25%)	1/4 (25%)	1/4 (25%)	1/4 (25%)	3/4 (75%)
Poorly differentiated carcinoma n (%)	0/1 (0%)	0/1 (0%)	0/1 (0%)	1/1 (100%)	1/1 (100%)
<b>Total</b> (%)	30/54 (55.6%)	8/54 (14.8%)	2/54 (3.7%)	14/54 (25.9%)	24/54 (44.4%)

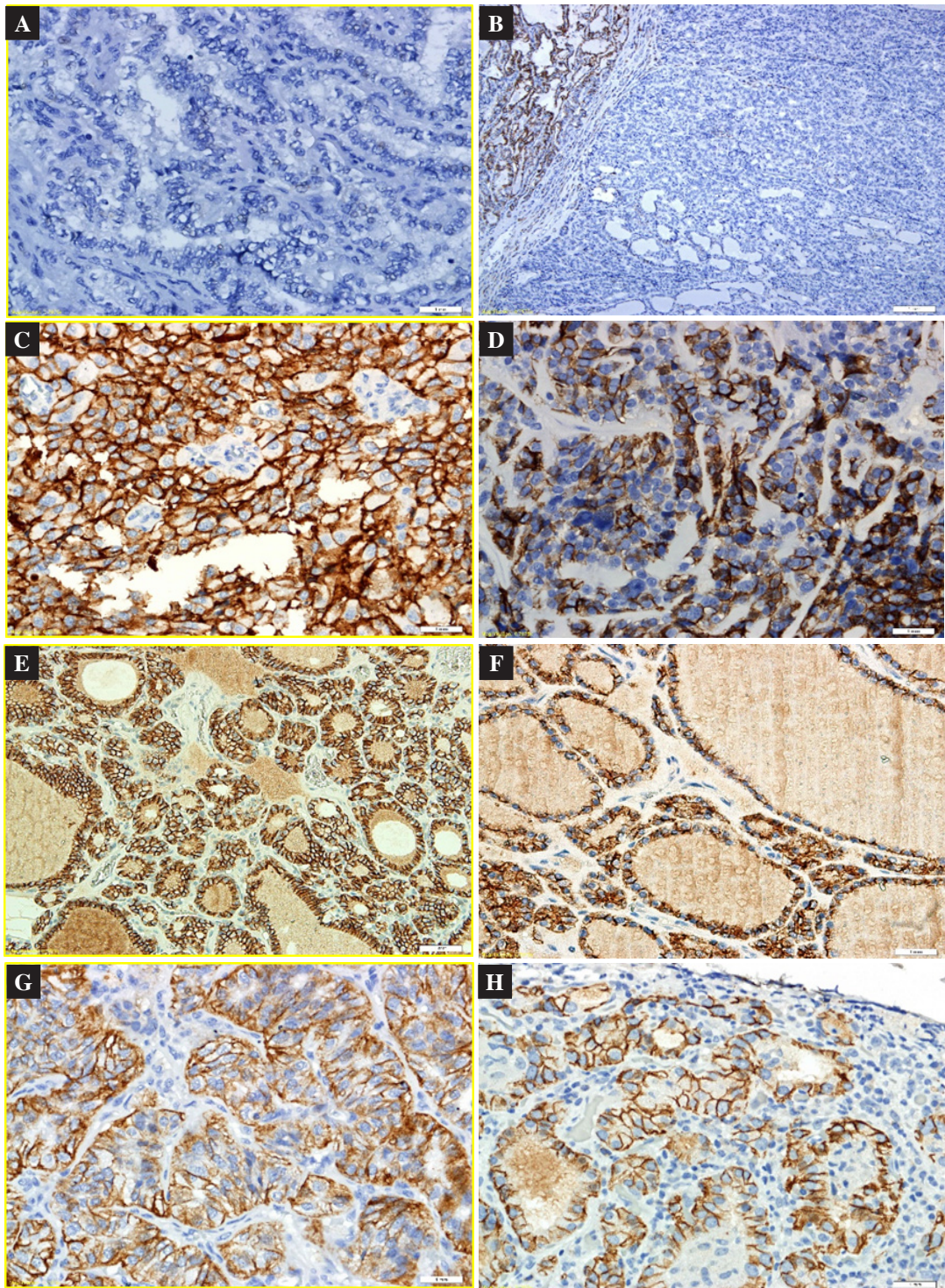


FIG. 2: CD56 expression in benign and malignant thyroid lesions. A) Papillary thyroid carcinoma showed negativity for CD56 (0). B) Absent CD56 expression in a follicular variant of papillary thyroid carcinoma; with expression in adjacent benign thyroid follicular cells. C) Strong membranous expression (3+) in a medullary thyroid carcinoma. D) Positive CD56 expression in follicular carcinoma (2+). E) Positive CD56 expression in follicular adenoma: diffusely positive (3+). F) Strong membranous expression (3+) in a nodular hyperplasia. G) Hyalinising trabecular adenoma, and H) lymphocytic thyroiditis.

**TABLE 4: CD56 expression in benign thyroid lesions**

Types of benign thyroid lesions	CD56 negative	CD56 positive			Total (%)
		1+	2+	3+	
Follicular adenoma n (%)	1/14 (7.1%)	1/14 (7.2%)	3/14 (21.4%)	9/14 (64.3%)	13/14 (92.9%)
Nodular hyperplasia n (%)	1/29 (3.4%)	7/29 (24.2%)	7/29 (24.2%)	14/29 (48.2%)	28/29 (96.6%)
Thyroiditis n (%)	0/10 (0%)	0/10 (0%)	0/10 (0%)	0/10 (0%)	10/10 (100%)
Hyalinising trabecular tumour n (%)	0/1 (0%)	0/1 (0%)	0/1 (0%)	1/1 (100%)	1/1 (100%)
Total (%)	2/54 (3.7%)	8/54 (14.8%)	10/54 (18.5%)	34/54 (63%)	52/54 (96.3%)

no statistical significant difference. There were 5 cases of follicular variant papillary thyroid carcinoma of which one case showed positive staining (2+) and 4 cases showed negative (0) staining. A statistically significant difference (P= <0.01) was also observed between the benign and malignant group. Study by Park (2009)<sup>14</sup>, Demellawy (2008)<sup>15-16</sup> and Alshenawy (2013)<sup>6-7</sup> also showed similar findings. Similarly, Nechifor-Boila (2014)<sup>1</sup> reported that CD56 was the most sensitive negative marker (81.8%) in thyroid carcinomas, showing a “malignant” profile in 5/6 classical papillary thyroid carcinomas and 4/5 follicular variant papillary thyroid carcinomas.<sup>1</sup>

Our results suggest that CD56 is a potentially good immunohistochemical diagnostic marker for differentiating papillary thyroid carcinoma from other benign follicular lesions of the thyroid. Therefore, it may be useful in differentiating follicular variant papillary thyroid carcinoma from follicular adenoma in equivocal cases, however, it may not be a useful marker to distinguish follicular adenoma from follicular carcinoma.

**ACKNOWLEDGEMENT**

This study was conducted with the support of a grant from the Fundamental Fund Universiti Kebangsaan Malaysia Medical Centre (Project code: FF-2016-234). The preliminary results of this study were presented as a poster in the 4<sup>th</sup> Annual Scientific Meeting 2017 of the International Academy of Pathology (Malaysian Division) in Penang, Malaysia in September 2017. The poster abstract was published in the

Malaysian Journal of Pathology in the December issue 2017.

*Conflict of interest:* The authors declare no conflicts of interest.

**REFERENCES**

1. Nechifor-Boila A, Catana R, Loghin A, Radu TG, Borda A. Diagnostic value of HBME-1, CD56, Galectin-3 and Cytokeratin-19 in papillary thyroid carcinomas and thyroid tumours of uncertain malignant potential. Rom J Morphol Embryol. 2014; 55: 49-56.
2. Saleh HA, Jin B, Barnwell J, Alzohaili O. Utility of immunohistochemical markers in differentiating benign from malignant follicular-derived thyroid nodules. Diagn Pathol. 2010; 5:1-1.
3. Fischer S, L.S. Application of immunohistochemistry to thyroid neoplasms. Arch Pathol Lab Med. 2008;132; 359-72.
4. Wu G, Wang J, Zhou Z, Lai T, Tang F. Combined staining for immunohistochemical markers in the diagnosis of papillary thyroid carcinoma: Improvement in the sensitivity or specificity? J Int Med Res 2013;4: 975-83.
5. Omar, Ariffin Z, Ali ZM, Tamin NSI. “Malaysian Cancer Statistics-Data and Figure, Peninsular Malaysia.” National cancer registry, ministry of health Malaysia. 2006.
6. Alshenawy HA. Utility of immunohistochemical markers in differential diagnosis of follicular cell-derived thyroid lesions. Journal of Microscopy and Ultrastructure. J Microsc Ultrastruct. 2014; 2:127-36.
7. Alshenawy HA. Utility of immunohistochemical markers in diagnosis of follicular cell derived thyroid lesions. Pathol Oncol Res 2014; 20:819-28.
8. Mokhtari M, Eftekhari M, Tahririan R. Absent CD56 expression in papillary thyroid carcinoma: A finding of potential diagnostic value in problematic cases of thyroid pathology. J Res Med Sci 2013;18:1046-0.

9. Rosai J. Papillary thyroid carcinoma: a root-and-branch rethink. *Am J Clin Pathol.* 2008;130: 683-86.
10. Shahebrahimi K1, Madani SH, Fazaeli AR, Khazaei S, Kanani M, Keshavarz A. Diagnostic value of CD56 and nm23 markers in papillary thyroid carcinoma. *Indian J Pathol Microbiol.* 2013; 56: 2-5.
11. Yang AH, Chen JY, Lee CH, Chen JY. Expression of NCAM and OCIAD1 in Well-differentiated Thyroid carcinoma. *J Clin Pathol* 2012; 3:206-12.
12. Scarpino S, Di Napoli A, Melotti F, Talerico C, Cancrini A, Ruco L. Papillary carcinoma of the thyroid; low expression of NCAM (CD56) is associated with down regulation of VEGF-D production by tumour cells. *J Pathol* 2007; 212:411-9
13. Ma H, Sanpeng X, Yan J, *et al.* The value of tumour markers in the diagnosis of papillary thyroid carcinoma alone and in combination. *Pol J Pathology.* 2014;65:202-9.
14. Park WY, Jeong SM, Lee JH, *et al.* Diagnostic value of decreased expression of CD56 protein in papillary carcinoma of the thyroid gland. *Basic Appl Pathol.* 2009; 2: 63–68.
15. El Demellawy D, Nasr A, Alowami S. Application of CD56, P63 and CK19 immunohistochemistry in the diagnosis of papillary carcinoma of the thyroid. *Diagn Pathol* 2008; 3: 1-2.
16. El Demellawy D, Nasr AL, Babay S, Alowami S. Diagnostic utility of CD56 immunohistochemistry in papillary carcinoma of the thyroid. *Pathol Res Pract.* 2009; 5: 303-9
17. Shin MK, Kim JW, Ju YS. CD56 and High Molecular Weight Cytokeratin as Diagnostic Markers of Papillary Thyroid Carcinoma. *Korean J Pathol* 2011;45: 477-84.
18. Atti El, Abdul RM, Shash LS. Potential diagnostic utility of CD56 and claudin-1 in papillary thyroid carcinoma and solitary follicular thyroid nodules. *J Egypt Natl Canc Inst* 2012; 24: 175-84.