

# Delayed Spontaneous Traumatic Pneumocephalus

**T Hari Chandran, FRCSEd\*, N Prepageran, FRCSEd\*\*, R Philip, MMed (ORL-HNS)\*\*\*, K Gopala, FRCSEd\*\*, A L Ahmad Zubaidi, FRCSEd\*, M A Jalaludin, FRCSEd\*\***

\*Department of ENT, \*\*Department of Neurosurgery, Universiti Malaya Medical Center, \*\*\*Department of ENT, Hospital Ipoh, 30990, Jalan Hospital, Ipoh, Perak

## SUMMARY

**Pneumocephalus or collection of air in the intracranial cavity can occur after trauma or surgery. However, delayed pneumocephalus occurring months after the initial injury is not common. We would like to report a case of spontaneous traumatic pneumoencephalocele presenting with transient recurrent hemiparesis 14 months after the initial trauma.**

## KEY WORDS:

*Pneumocephalus, Frontal sinus*

## CASE REPORT

A.A.R, an 18 year old gentleman was referred with a history of recurrent, transient unilateral weakness of body. He presented with a sudden onset of complete right sided weaknesses of whole body of five days duration, which gradually improved. He had a similar episode 11 months ago, which lasted for three hours. He didn't seek treatment at that time. He has been symptom free in between. He had no headaches, visual disturbances or slurring of speech. He could not recollect any aggravating factor: He denied any precipitating sneezing, coughing episodes or straining. He was involved in a motor vehicle accident 14 months before where he sustained a left maxillary fracture with loss of consciousness for a few minutes. He was hospitalized in another center for a week and surgical fixation of his left maxillary fracture was carried out. He was discharged well.

On examination, he appeared comfortable, with normal orientation to time, place and person. He had right upper motor neuron facial nerve palsy (grade 2 House Brackman), with generalized right sided weakness of upper and lower limb. The right limbs had power of 4 out of 5 (able to move against gravity but not against resistance), normal reflexes, with normal sensation and proprioception.

His left limbs and other cranial nerves were normal. Pupils were both reactive to light with normal accommodation. No other neurological deficits were noted. No cerebrospinal fluid leak was noted.

Examination of his nose and paranasal sinuses was essentially normal. CT scan from the referring physician revealed a large collection of air in left frontal lobe, causing a compression mass effect with a tract leading to a fracture at the posterior table of the frontal sinus (Figure 1 & 2). He underwent a frontal craniotomy and exploration of frontal sinus under general anesthesia. A defect was noted in the posterior table of frontal sinus with herniation of frontal lobe through the

defect with intact dura matter. The frontal sinus was normal otherwise. The herniated part of frontal lobe was reduced; the defect in the posterior table of frontal sinus was repaired with bone graft. Fascia lata was placed over the repaired defect intracranially and the frontal sinus was obliterated with abdominal fat and temporalis muscle. A temporary conduit was inserted into the subdural space.

Post operatively, he recovered well and the temporary conduit was removed on 4th postoperative day. A repeat CT scan two days postoperative showed marked reduction in the size of the pneumocephalus. He was discharged well and has been asymptomatic for the last four years.

## DISCUSSION

Pneumocephalus or collection of air in the intracranial cavity can occur post surgery or post trauma. It can also occur after invasive procedures like lumbar puncture, barotrauma and infection with gas producing organism. It has also been reported to occur after surgical procedures to the nasal and paranasal sinuses; after nasal septum resection<sup>1</sup> and nasal polypectomy<sup>2</sup>. Recent papers have reported pneumocephalus after prolonged nasal continuous positive airway pressure and failed ventricular tap<sup>3,4</sup>. It occurs when a defect in the skull base and dura forms a fistula into the cranial cavity. Minimal accumulation of air can be asymptomatic. However, a large pneumocephalus can cause a mass effect and give rise to symptoms and signs according to the corresponding area of brain under pressure<sup>5</sup>. Bilateral weakness of lower limbs has been reported<sup>2</sup> and we report a transient hemiplegia. In our patient, the pneumocephalus must have compressed the left precentral gyrus resulting in a right-sided body weakness. The transient nature of his presentation is probably due to the collection of air reabsorbed after a period of time. The aggravating factor is usually an episode of sneezing, coughing or straining. This would induce positive pressure in the upper airway, opening the fistula and resulting in a pneumocephalus. Cerebrospinal fluid leaks can occur with pneumocephalus and occasionally a pneumoencephalocele can complicate a cerebrospinal rhinorrhea.

CT scan remains the investigation of choice. Pneumocephalus is easily diagnosed on CT, which can detect quantities of air as low as 0.5ml. Air appears black and has a Hounsfield coefficient of -1000<sup>3</sup>. Defects in the skull base can be identified in high resolution CT scans. MRI despite its superior soft tissue enhancement is not useful in delineating bony defects. A simple pneumocephalus does not need treatment. It is vital to differentiate it from tension

*This article was accepted: 8 September 2007*

*Corresponding Author: Philip Rajan, Department of ENT, Hospital Ipoh, Hospital, 30990 Jalan Hospital, Ipoh, Perak Email: prajan333@yahoo.com*

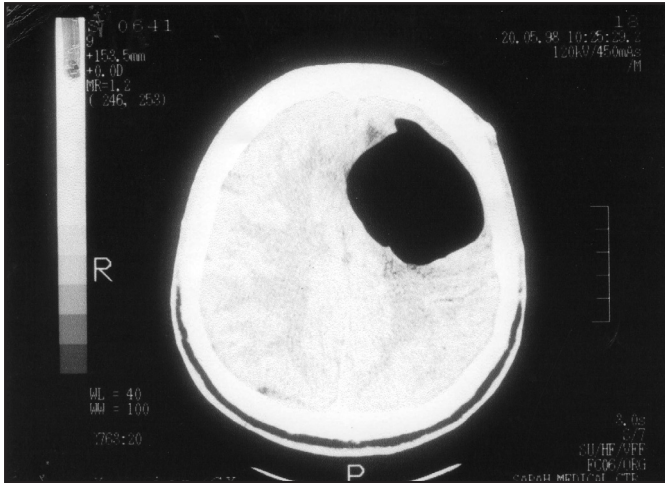


Fig. 1: CT scan revealing a large pneumocephalus.

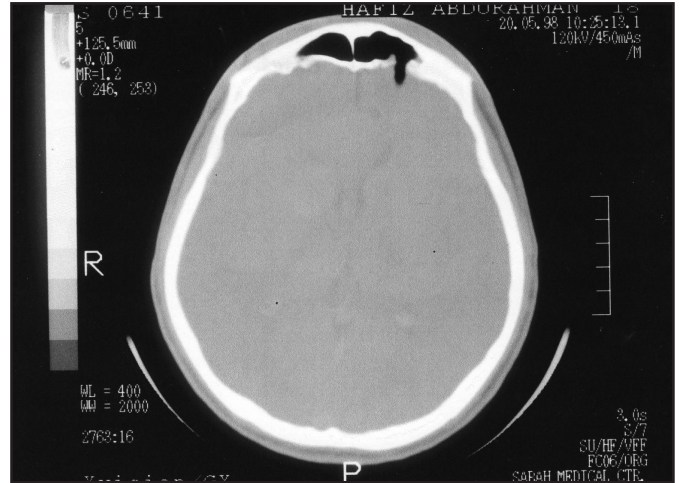


Fig. 2: CT scan revealing fracture of posterior table of frontal sinus.

pneumocephalus, which need evacuation if symptomatic<sup>5</sup>. The management depends on the symptomology of the pneumocephalus and its etiology. Pneumocephalus of significant size that causes compression symptoms would need surgical exploration. It is vital that the defect in the floor of cranium is identified and repaired to prevent recollection of air in the cranial cavity. Cerebrospinal fistulas that persist after conservative management should be repaired to prevent pneumocephalus. If there is no leak, the gas would be reabsorbed in time<sup>5</sup>.

**REFERENCES**

1. Langauer-Lewowicka H, Kickza J, Romanowski B. Pneumoencephalocoele as a complication of nasal septum resection. *Neurol Neurochir Pol* 1971; 5(4): 583-5.
2. Misra BK, Harris P. Tension pneumocephalus following nasal polypectomy. *Surg Neurol* 1987; 28(4): 307-10.
3. Bernstein AL, Cassidy J, Duchynski R, Eisenberg SS. Atypical headache after prolonged treatment with nasal continuous positive airway pressure. *Headache*. 2005; 45(5): 609-11.
4. Meguro T, Terada K, Hirotsune N, Nishino S, Asano T, Manabe T. Pneumocephalus caused by failed ventricular tap: case report. *No Shinkei Geka* 2005; 33(6): 607-10.
5. Mark S. Greenberg. *Handbook of Neurosurgery*. 4th Edition 1997. Volume 2, Greenberg Graphics Inc.