

# Chance Fracture Secondary to a Healed Kyphotic Compression Osteoporotic Fracture

Teh KK, MS Orth, Chan CYW, MS Orth, Saw LB, MS Orth, Kwan MK, MS Orth

Orthopaedic Surgery, University Malaya Medical Center, Kuala Lumpur, Malaysia

## ABSTRACT

Chance fracture is an unstable vertebral fracture, which usually results from a high velocity injury. An elderly lady with a previously healed osteoporotic fracture of the T12 and L1 vertebra which resulted in a severe kyphotic deformity subsequently sustained a Chance fracture of the adjacent L2 vertebrae after a minor fall. The previously fracture left her with a deformity which resulted in significant sagittal imbalance therefore predisposing her to this fracture. This case highlights the importance of aggressive treatment of osteoporotic fractures in order to prevent significant sagittal imbalance from resultant (i.e. kyphotic) deformity.

## Key Words:

*Chance Fracture, Kyphotic Deformity, Sagittal Imbalance*

## INTRODUCTION

First described by G.Q. Chance in 1948<sup>1</sup>, findings of a Chance fracture include a “horizontal splitting of the spine and neural arch”, which in today’s terms involve all 3 spinal columns as, described by Denis. This type of fracture is usually seen after significant trauma such as from high speed motor vehicle accidents or a fall from height. The mechanism of injury in such cases is that of flexion-distraction. We report here a rare case of Chance fracture following a minor fall that occurred subsequent to previous kyphotic deformity in an osteoporotic elderly lady.

## CASE REPORT

A 69-year-old Indian female with diabetes mellitus, hypertension and ischaemic heart disease presented with a past history of a fall that was associated with severe back pain and was treated conservatively as an outpatient 4 years prior to admission. No radiograph was taken at that time. Current presentation to the hospital was due to a minor fall at home with patient complaints of low grade fever, malaise and weakness of the lower limbs. On clinical examination, she was febrile, tachycardic but normotensive, and generally weak but could obey commands. There was no obvious source of sepsis found from systemic review. There was a

kyphotic deformity at the upper back that was tender to palpation. Examination of the lower limbs revealed Frankel C muscle power. Although, there was decreased sensation below the level of L2., upper limb findings were normal. The provisional diagnosis was pyogenic infection of the spine causing weakness of the lower limbs and sepsis.

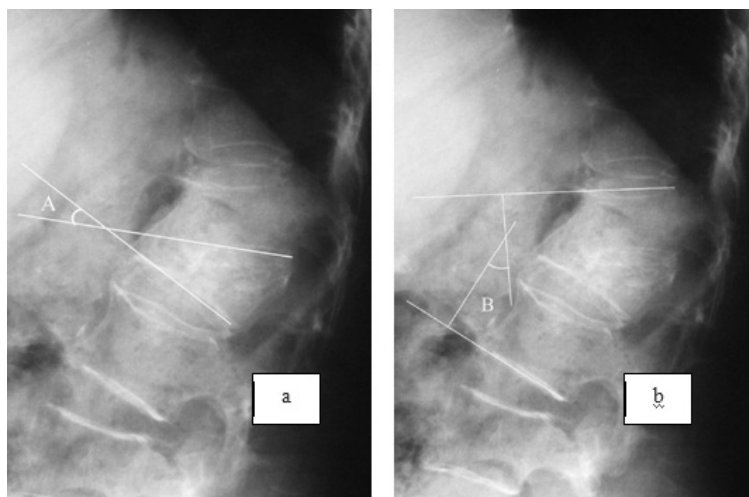
Radiograph of the spine showed healed compression fracture of T12 and L1 vertebra (Fig.1) and a significant resultant kyphotic deformity of the spine. There was no end plate or vertebral body erosion and no new fracture was apparent from the plain radiographs. An urgent MRI was arranged to look for the cause of the lower limb weakness. However due to her generally weakened condition, the MRI was abandoned and an urgent computed tomography of the spine was performed instead.

The CT scan revealed a bony “Chance” type fracture of L2 just below the old compression fracture (Fig 2). There was no evidence of infection such as vertebral body erosion, end plate erosion or soft tissue collection. In the ward, her vital signs were labile and therefore a decision was made to treat the Chance fracture with bed rest and bracing. Her condition then deteriorated and she was transferred to the intensive care unit for closer observation, inotropic support and empirical high dose antibiotics.

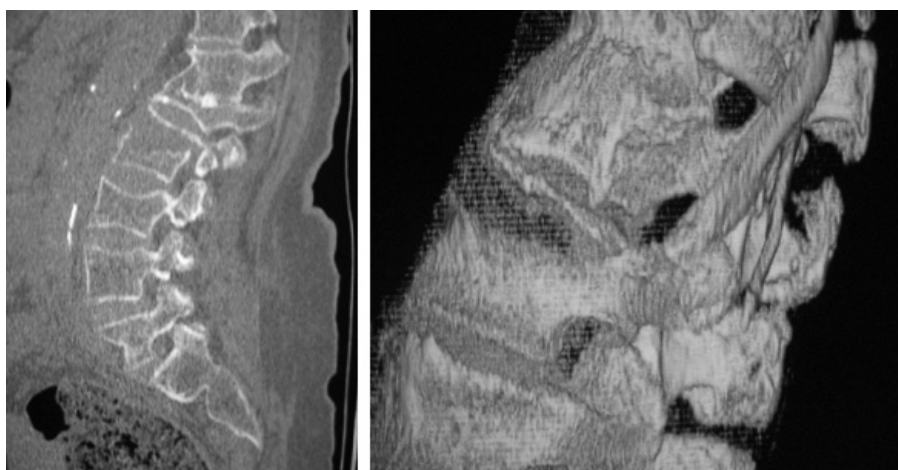No organism was cultured from the sputum, urine, blood or cerebral spinal fluid sample. A computed tomography of the brain showed multifocal old infarcts. She passed away five days after admission due to acute coronary syndrome with underlying septic shock.

## DISCUSSION

Osteoporotic spine fracture usually affects the elderly. Following osteoporotic vertebral fracture, the standardized mortality ratio rises to 1.66 in women and 2.38 in men<sup>2</sup>. Unlike hip fractures, this increased mortality rate extends well beyond the first year after the fractures<sup>3</sup>. Most osteoporotic spine fractures are considered stable as they only involve one column of the vertebra. Riggs and Melton has tried to classify osteoporotic fractures according to its



**Fig. 1A & B:** Healed fracture with kyphotic deformity and Local Sagittal angle (a) of 29 degrees and Regional Sagittal Angle (b) of 38 degrees respectively prior to the fracture.



**Fig. 2:** Computed Tomography of the spine with sagittal and 3-D reconstruction scans revealed a bony "Chance type" fracture of L2 just below an old compression fracture.

plain radiographic features: wedge, biconcave or codfish and crush types of fracture<sup>4</sup>.

Neurological deficit is a rare occurrence after an osteoporotic spine fracture. For example, a study by Lee et al in Hong Kong found neurological deficit in only 2% of 497 patients<sup>5</sup>. The presentation of neurological deficit is usually delayed.

In this case, the patient had a wedge fracture of T12 and L1, which healed with a kyphotic deformity (local sagittal angle of A and regional sagittal angle of B of 29 and 38 degrees at the thoraco-lumbar junction respectively). The kyphotic deformity resulted in a fixed sagittal imbalance thereby increasing the stress on T11 and L2 vertebra. The T11 vertebra, being a thoracic vertebra is biomechanically more

stable than the L2 vertebra<sup>6</sup>. In this patient, although there was only a low velocity trauma, a three column Chance fracture occurred over the L2 vertebra. The healed T12-L1 compression fracture kept the spine in a stiff and kyphotic, allowing all the force to go through the vertebra below it when the patient fell. Therefore, the occurrence of fixed sagittal imbalance after a healed spinal fracture may alter the biomechanics of the spine and subsequently lead to more severe and devastating fractures.

Osteoporotic vertebral fractures are increasingly more important in a society where there is a lengthening life span. Fractures previously considered to be benign should no longer be taken lightly. With the availability of preventive treatments for osteoporosis, these complications can be hopefully prevented with early diagnosis and treatment<sup>7</sup>.

## REFERENCES

1. Chance GQ. Note on a type of flexion fracture of the spine. *Br J Radiol*, 1948; 21: 452-3.
2. Center JR, Nguyen TV, Schneider D, Sambrook PN, Eisman JA. Mortality after all major types of osteoporotic fracture in men and women: an observational study. *The Lancet*, 1999; 353(9156): 878-82.
3. Cooper C, Atkinson EJ, Jacobsen SJ, O'Fallon WM, Melton LJ 3rd. Population-based study of survival after osteoporotic fractures. *Am J Epidemiol*, 1993; 137(9): 1001-5.
4. Stephen I, Esses JB, editors. Textbook of Spinal Disorders. Philadelphia: Lippincott Company; 1995; 320-2.
5. Lee YL, Yip KMH. The osteoporotic spine. *Clin Orthop*, 1996; 323: 91-7.
6. Jensen ME, Evans AJ, Mathis JM, Kallmes DF, Cloft HJ, Dion JE. Percutaneous polymethylmethacrylate vertebroplasty in the treatment of osteoporotic vertebral body compression fractures: technical aspects. *AJNR Am J Neuroradiol*, 1997; 18(10): 1897-904.
7. Garfin SR, Yuan HA, Reiley MA. New technologies in spine: Kyphoplasty and vertebroplasty for the treatment of painful osteoporotic compression fractures. *Spine*, 2001; 26(14): 1511-5.