

# Bilateral Traumatic Hip Dislocation in a Child: A Case Report

**S M Khoo**, MS Ortho (U Malaya)  
Putra Specialist Hospital, Batu Pahat, Johor, Malaysia

## ABSTRACT

Traumatic hip dislocation in children is uncommon; when this condition is diagnosed in paediatric patients, it is most frequently seen as a unilateral posterior dislocation and is rarely associated with fracture. We report here a case involving a young girl who dislocated both hips in two separate incidents.

### Key Words:

*Bilateral hip dislocation, Traumatic hip dislocation, Paediatric hip dislocation*

## INTRODUCTION

Traumatic hip dislocation in children is uncommon, and most reported cases are posterior dislocation following low-energy injury. Dislocated hips in paediatrics are rarely associated with fractures of the acetabulum especially in younger children<sup>1,3</sup>. Outcomes following immediate reduction are usually satisfactory, although avascular necrosis (AVN) and other complications may occur. Reduction is easily achieved under sedation or general anaesthesia; however labral, capsular, and osteochondral fragment interposition may prevent concentric reduction. To date, there have been no reported cases in which a child dislocated both hips in two separate incidents.

## CASE REPORT

A 4-year-old Malay female first presented to our institution in 2005 after she tripped and fell while playing. She developed severe pain in her right hip and was unable to move or ambulate. Clinical examination showed an irritable child with apparent shortening of the right lower limb which was adducted and internally rotated. Neurological examination revealed no sensory or motor deficits. Plain radiographs [Fig. 1A] showed posterior dislocation of the right hip. The dislocation was reduced immediately after diagnosis utilizing sedation and Allis' manoeuvre. The hip was stable with full range of motion (ROM) after the reduction. Post-reduction radiographs [Fig. 1B] showed a

concentrically reduced hip without any associated fracture or asymmetry of joint space. After one week of skin traction, the patient was discharged from the hospital with advice not to bear weight on the affected limb for 6 weeks. At 6 weeks post-reduction, clinical and radiological assessments revealed no abnormality.

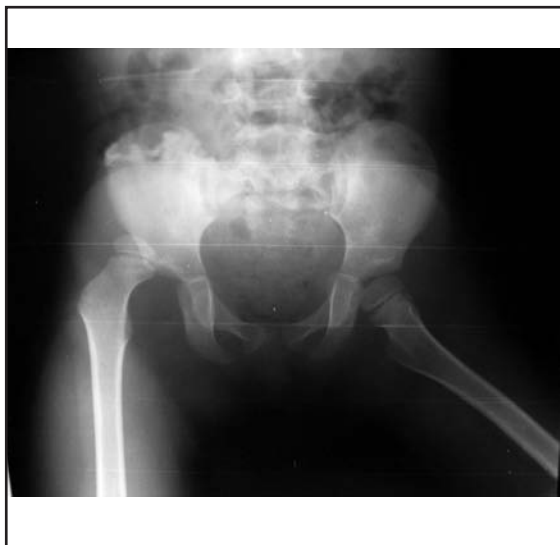The child presented to us again 4 months later after another injury; this time she was knocked down by a bicycle while playing and developed severe pain in the left hip. Clinical examination did not reveal any sign of skin hyper-extensibility or joint hyper-mobility. There was no similar history among other family members. Plain radiograph [Fig. 1C] showed posterior dislocation of the left hip with no evidence of fracture. Reduction and post-procedure care was accomplished similarly to the previous dislocation.

CT scan of both hips [Fig. 2A] performed 2 months after the second dislocation showed no deficiency in acetabular coverage or excessive femoral ante-version. The child was last evaluated 8 months after the second hip dislocation. She demonstrated normal gait and both hips were stable on physical examination. ROM of both hips was full and painless: flexion 0° to 140°; extension 0° to 30°; abduction 0° to 50°; adduction 0° to 30°; internal rotation 0° to 60° and external rotation 0° to 80°. A plain radiograph taken at that time [Fig. 2B] did not reveal any abnormality.

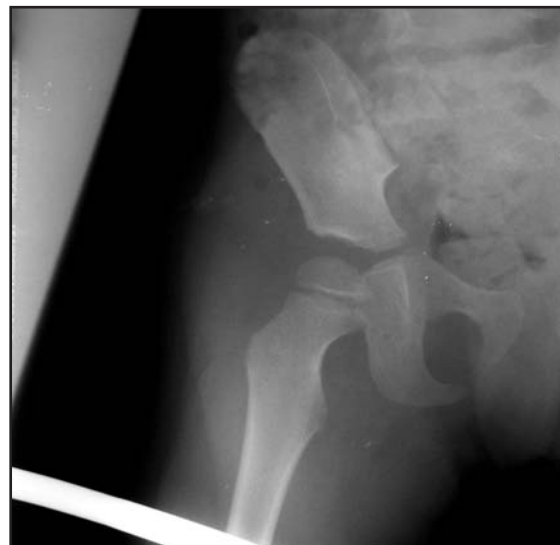## DISCUSSION

A review of the literature finds few case reports or series of traumatic hip dislocation in children. Bilateral traumatic hip dislocation in children is even more limited. There has not been any report about a child who dislocates both hips in separate injuries.

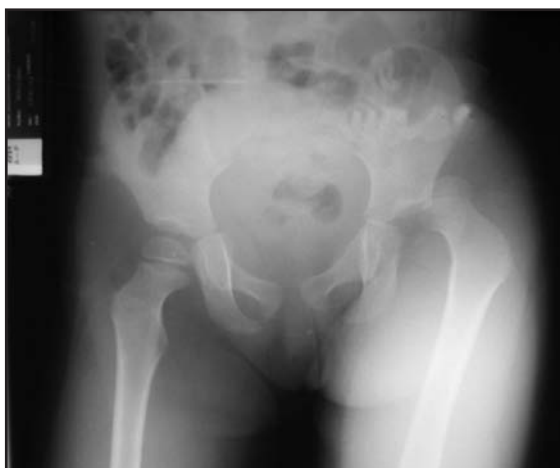The trauma required to produce a dislocation at the hip joint can range from trivial injury, such as occurs by tripping or falling, to severe high-impact injury, as in motor vehicle accidents. Generally younger children require less force to dislocate their hips<sup>1</sup>. Low-energy trauma can cause dislocations in younger patients because their periarticular



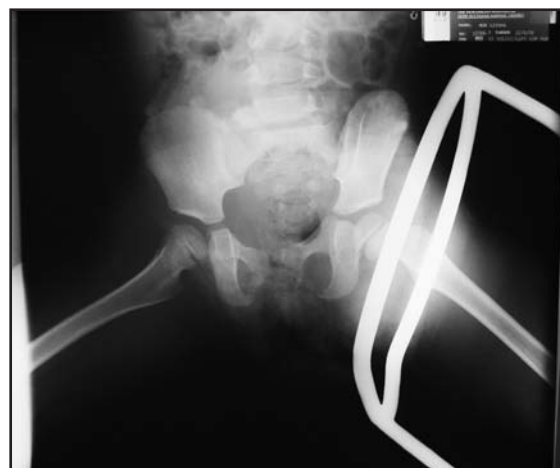**Fig 1A:** Posterior Dislocation of Right Hip.



**Fig.1B:** Concentrically reduced right hip with applied traction.



**Fig. 1C:** Posterior Dislocation of Left Hip.



**Fig. 1D:** Concentrically Reduced Left Hip

structures are more flexible. This joint laxity also explains the absence of fractures of the acetabulum or femoral head in majority of the cases in these younger patients. The laxity reduces with age as does the cartilage to bone ratio<sup>4</sup>. As the child enters adolescence, the hip is more likely to dislocate only as a result of significant high-impact trauma more in line with the adult pattern of hip dislocation.

The vast majority of hip dislocations in children can be managed by closed manipulation and reduction under sedation or general anaesthesia followed by casting, traction, or bed rest. Radiographs should be taken after all closed or open reductions to ensure that reduction is concentric and to exclude the presence of fracture fragments. If there is any doubt about concentric reduction, a CT scan is indicated. Many potential complications of traumatic hip dislocations in children have been reported and include avascular necrosis

(AVN) of the femoral head, myositis ossificans, post-traumatic osteoarthritis and femoral head deformity such as coxa magna, premature physeal fusion, sciatic nerve injury and recurrent hip instability.

AVN of the femoral head is the most serious complication that can occur after traumatic hip dislocation in childhood and accounts for the poor prognosis of this injury. Risk factors are prolonged interval before reduction, older age and the presence of fracture-dislocations. Patients whose hips were reduced more than 6 hours after injury have a 20-fold increase in risk of having AVN<sup>2</sup>. Even under ideal conditions, however, the risk of AVN cannot be completely eliminated. Affected children should be followed regularly until skeletal maturity since abnormalities in the development of the hip may only manifest years later.

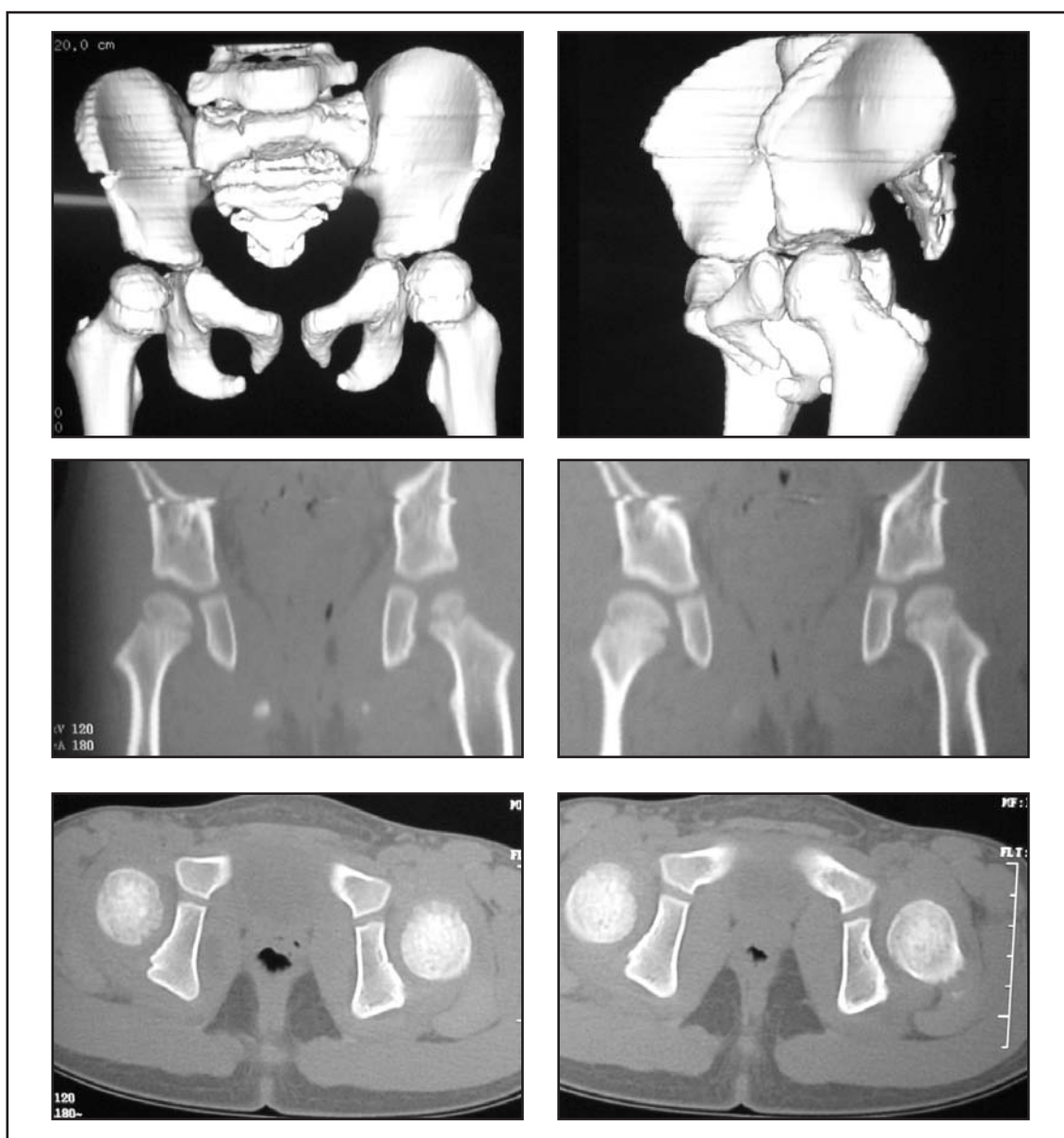


Fig. 2A : CT scan of the hips did not reveal any abnormality two months after the second reduction.

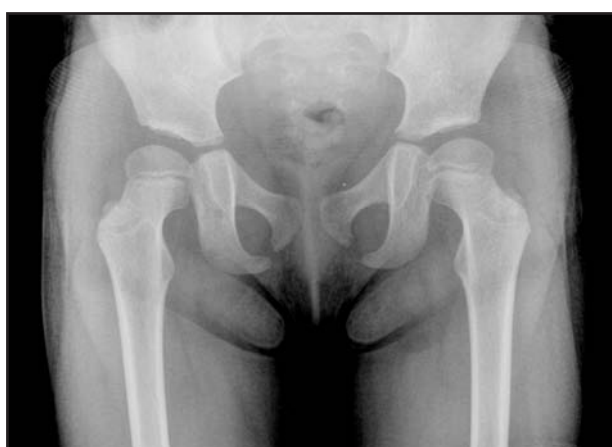

Fig. 2B: Plain radiograph of both hips showing no evidence of abnormal development eight months after reduction of the second dislocation.

## REFERENCES

1. Hamilton PR, Broughton NS. Traumatic Hip Dislocation in Childhood. *J Pediatr Orthop.* 1998; 18(5): 691-4.
2. Mehlman CT, Hubbard GW, Crawford AH, Roy DR, Wall EJ. Traumatic Hip Dislocation in Children. Long Term Follow-up of 42 patients. *Clin Orth.* 2000; 376: 68-79.
3. Salisbury RD, Eastwood DM. Traumatic Dislocation of the Hip in Children. *Clin Orthop.* 2000; 377: 106-111.
4. Vialle R, Odent T, Pannier S, Pauthier F, Laumonier F, Glorion C. Traumatic Hip Dislocation in Children. *J Pediatr Orthop.* 2005; 25(2): 138-44.