

ORIGINAL ARTICLE

The effect of water extracts of *Euphorbia hirta* on cartilage degeneration in arthritic rats

Kah Heng LEE ^aB.MedSc, Yu Sui CHEN ^aPh.D, John Paul JUDSON ^aM.D.,
Srikumar CHAKRAVARTHI ^bM.D., Yen Mi SIM ^aB.MedSc, Hui Meng ER ^cPh.D

^aHuman Biology Section, ^bPathology Section, ^cSchool of Pharmacy & Health Sciences, International Medical University, Kuala Lumpur, Malaysia

Abstract

The effect of water extracts of *Euphorbia hirta* on the histological features and expressions of matrix metalloproteinases (MMPs) and tissue inhibitors of matrix metalloproteinases (TIMPs) in the rat articular cartilage was investigated. Arthritis was induced in rats using Freund's Complete Adjuvant containing heat-killed *M. tuberculosis*, and treated with water extracts of *E. hirta*. Paraffin tissue sections of the arthritic joints were evaluated. The extent of cartilage degeneration was found to be greatest in rats treated with the highest dosage of *E. hirta*, followed by rats in the untreated group. Rats treated with the intermediary and low dosages of *Euphorbia hirta* showed improved histology. MMP-13 levels were found to be decreased with decreasing dosages of *E. hirta*. TIMP-1 levels were found to increase with decreasing dosages of *E. hirta*. MMP-3 levels fluctuated without any appreciable pattern.

Low dosages of *E. hirta* seem to be beneficial in reducing cartilage degeneration in cases of arthritis.

Keywords: *Euphorbia hirta*; MMP-3; MMP-13; TIMP-1; arthritis

INTRODUCTION

Arthritis is a group of conditions characterized by inflammation of and damage to the joints of the body, which can be due to many reasons including infection, metabolic disorders, or autoimmune conditions. One of the key features of osteoarthritis is the degeneration of articular cartilage. Some members of a group of endopeptidase enzymes known as matrix metalloproteinases (MMPs) and tissue inhibitors of matrix metalloproteinases (TIMPs), are known to be partially responsible for mediating the process of cartilage degeneration in arthritic diseases. MMP-13 is known as collagenase-3 which is produced by chondrocytes, and some of its effects include the cleavage of collagen, inducing the release of β -fibroblast growth factor (β -FGF), and osteoclast activation.^{1,2} MMP-3 is known as stromelysin-1 and it can be expressed in various types of cells including fibroblasts, chondrocytes, endothelial cells, macrophages, vascular smooth muscle cells, osteoblasts and keratinocytes in response to appropriate stimuli.³

Stromelysins have a role in the breakdown of extracellular matrix components, and MMP-3 also has additional roles in activating a number of proMMPs.⁴ The stromelysin MMP-3 is structurally very similar to the collagenase MMP-13, but it is unable to cleave either type I or type II collagen.⁵ Some of the effects of MMP-3 include inducing the release of β -FGF, pro-inflammatory actions, the processing of IL-1 β from its precursor, and the increased bioavailability of transforming growth factor β (TGF- β).² MMP-3 has been found in increased levels at the sites of cartilage erosion in cases of rheumatoid arthritis and osteoarthritis.⁶ Both MMP-3 and MMP-13 have been shown to be present in elevated levels in cases of cartilage degeneration such as that found in osteoarthritis.⁷ During pathological processes caused by unbalanced MMP activity, changes of TIMP levels are considered to be important because they directly affect the level of MMP activity.⁴ This study was to estimate levels of MMP-3 and MMP-13 as well as the presence of TIMP-1, which is the TIMP class responsible for the inhibition of MMP-3 and MMP-13.

Euphorbia hirta is a common herb from the *Euphorbiaceae* or spurge family. It is also known as *Euphorbia pilulifera* and *Chamaesyce hirta*.⁸ *Euphorbia hirta* has a worldwide distribution, and its common names include cats hair, asthma weed, basri dudhi, chara, malnommee, patikan kerbau, fei yang cao, gelang susu, amampat chaarisi and erva de santa luzia. *Euphorbia hirta* is known to have analgesic, antipyretic, anti-inflammatory, expectorant, anti-catarhal, antisyphilitic, antiviral and antibacterial properties.⁹

The focus of this study was to examine the histological features of the articular cartilage and the levels of MMP-3, MMP-13 and TIMP-1 of arthritic rats treated with aqueous extracts of the herb *Euphorbia hirta*.

MATERIALS AND METHODS

Extraction

Dried, powdered whole plant material was extracted sequentially with n-hexane, chloroform, methanol and water using a soxhlet extractor. The water extract was then dried under reduced pressure at 50°C using a rotary evaporator (Buchi Rotavapor R-200), and further freeze-dried (Labconco freeze dry system/Freezone 4.5). The yield was about 16% from dried material.

Animals

Male Wistar rats weighing 200-250gm were obtained from the animal house of Universiti Kebangsaan Malaysia for the experiment. The animals were kept in the International Medical University (IMU) animal holding facility, with food and water *ad libitum*. All experimental procedures were approved by the IMU Research and Ethics committees.

Induction of arthritis

The rats were divided into 5 groups of 8 animals each. The animals were anaesthetized intraperitoneally with 140mg/kg of ketamine chloride (Mavlab, Australia) before the administration of adjuvant. Group A (control group) rats received injections consisting of 0.1 mL of Freund's Incomplete Adjuvant (Sigma Chemical Co, USA) in the sub-plantar tissue of the right posterior paw. Groups B, C, D and E (arthritis induced groups) were injected with 0.1 mL of Freund's Complete Adjuvant containing 150 µg of heat-killed *Mycobacterium tuberculosis* (Sigma Chemical Co, USA).¹⁰

Treatment of animals with *Euphorbia hirta*

Groups A and B were not treated, but given water by oral gavage. Groups C, D and E were fed aqueous extracts of *Euphorbia hirta* at concentrations of 500 mg/kg, 100 mg/kg and 50 mg/kg respectively via oral gavage. The water and extracts were given once every 2 days for 52 days, beginning on the tenth day after arthritis induction. After the treatment period, the animals were humanely sacrificed for study.

Histopathological processing

During the subsequent necropsy, the tarsal joints of the right posterior paws were removed and fixed in 10% buffered formalin. The joints were treated with a decalcifying agent made up of 1000 ml of distilled water containing EDTA (added till saturated) and 50 mL of concentrated hydrochloric acid. The joints were then embedded in paraffin wax and sectioned at 4µm.

Immunohistochemistry

The method used in this study was indirect immunohistochemistry (IHC). Target retrieval was done using a hot water bath immersion of 70°C for 1 hour. This lower-than-average temperature was used to prevent excessive destruction of the sample tissues. The MMP-13 antibody (rabbit anti-MMP-13 polyclonal antibody, Biovision Inc, USA) was diluted to a concentration of 2µg/mL. The TIMP-1 antibody (goat anti-TIMP-1 polyclonal antibody, Santa Cruz Biotechnology Inc, USA) was diluted to a concentration of 0.8µg/mL. The MMP-3 antibody (mouse anti-MMP-3 monoclonal antibody, Chemicon of Millipore, USA) was diluted to a concentration of 5µg/mL. Primary antibody incubation was done for 90 minutes. For MMP-3 and MMP-13, horseradish peroxidase with secondary antibodies (DAKO, Denmark) was used. For TIMP-1, the sections were instead incubated first with biotinylated link (DAKO, Denmark) and then with streptavidin-HRP (DAKO, Denmark).

Light microscopical analysis

The slides were examined under a Nikon Brightfield Compound Microscope (YS100) with a 5.1 megapixel resolution, at magnifications of 100X, 200X and 400X, and the relevant images were captured. The sections were visually graded for tissue pathology between 0 and 3 based on the criteria in Table 1. Normal cartilage would have a score of 0 (no significant pathology), and the most badly degenerated cartilage would

TABLE 1: Criteria used in the grading for histopathology

| Pathology | Grade | | | |
|-----------------------|--------------|-----------------------------|---|---|
| | 0 | 1 | 2 | 3 |
| Oedema | Nil | Mild | Moderate | Severe |
| Cellular infiltration | Nil | Mild scattered infiltration | Lymphocytes and macrophages | Sheets of inflammatory cells/granulomas/MNG cells |
| Joint space | No narrowing | Mild narrowing | Moderate narrowing with very little intermarginal space | Total obliteration of joint space |
| Synovial hyperplasia | Nil | Mild | Moderate | Extensive |
| Fibrosis | Nil | Mild | Moderate | Extensive/Severe |
| Erosion | Absent | Present | | |

have a maximum graded score of 16 (worst possible pathology in each category). MMP and TIMP expressions on the sections were graded negative, weakly positive, or positive and assigned numerical scores according to the criteria in Table 2. The results were expressed as a percentage of maximum score each group can obtain.

Statistical analysis

The results for the histopathological grading of the cartilage sections were analyzed using ANOVA and Tukey's *post hoc* analysis. The scores for MMP and TIMP staining were analyzed using the Kruskal-Wallis test and the Mann-Whitney test. Statistical significance was set $p < 0.05$.

RESULTS

Histopathological analysis

The control group (Group A) animals injected with Freund's incomplete adjuvant showed no significant histological changes. All other groups developed different degrees of degenerative changes and inflammation including oedema, cellular infiltration, joint narrowing, synovial hyperplasia, fibrosis and erosion. Figure 1 shows a summary of the scores obtained by all the groups. The highest score was obtained by Group C and the lowest by Group A. Scores obtained by Group A are significantly lower than those of B, C, D and E ($p < 0.05$). Figure 2 shows sections of joint cartilage displaying the studied pathologies.

TABLE 2: Criteria used in the grading for MMP and TIMP staining

| Description | Grade | Score |
|--|-----------------|-------|
| Tissue not stained | Negative | 0 |
| Staining is low in intensity and/or less than 50% of the cartilage area is stained | Weakly Positive | 1 |
| Staining shows good intensity and more than 50% of the cartilage area is stained | Positive | 2 |

Means of grading scores

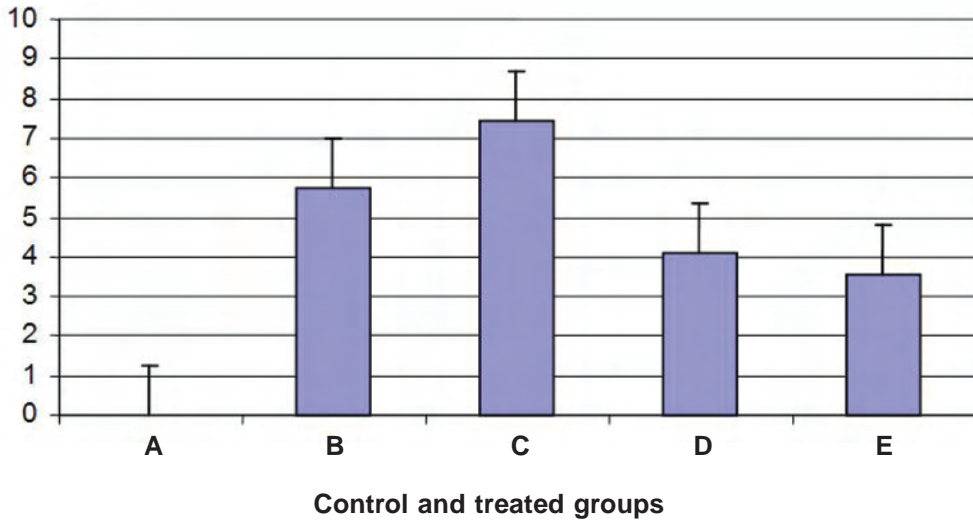


FIG. 1: Summary of total scores obtained in each group. Group A rats received Freund’s incomplete adjuvant and water treatment (n=8). Groups B to E received Freund’s Complete Adjuvant containing heat-killed *Mycobacterium tuberculosis*. Group B received water treatment (n=8). Group C received 500 mg/kg *E. hirta* water extract (n=7). Group D received 100 mg/kg *E. hirta* water extract (n=8). Group E received 50 mg/kg *E. hirta* water extract (n=7). Groups where C and E have n=7 because one rat in each of the groups perished during the course of the experiment. Group A score is significantly lower than groups B, C, D and E (p<0.05).

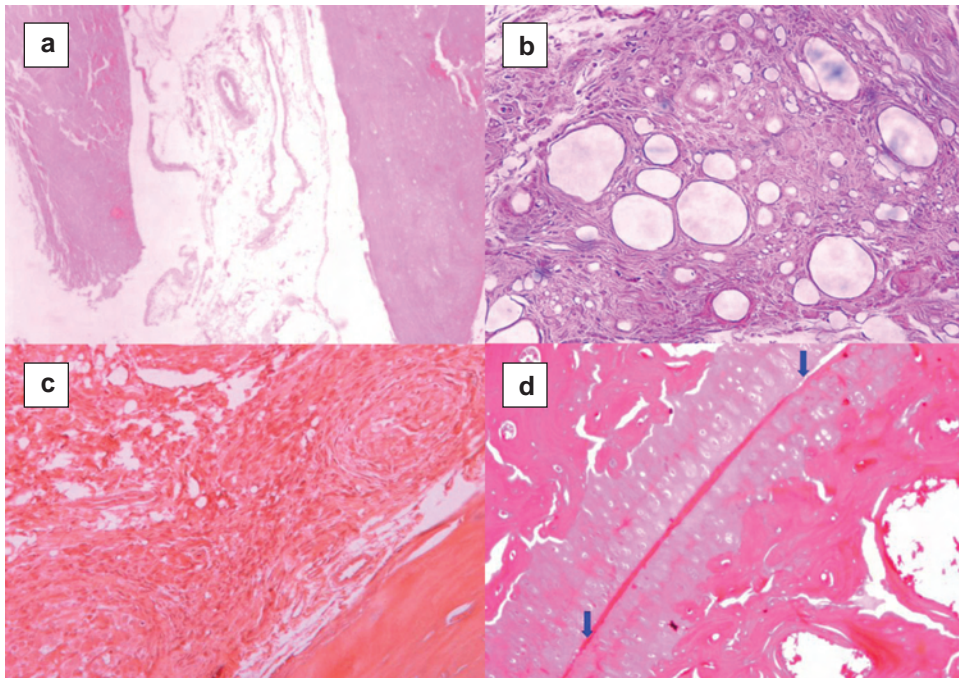


FIG. 2: Sections from the tarsal joints of the right posterior paws of rats in (a) group C showing oedema (100x); (b) group B showing mild scattered inflammation (400x); (c) group B showing a granuloma (200x); (d) group D showing a narrowed joint space. The blue arrows indicate the joint space.

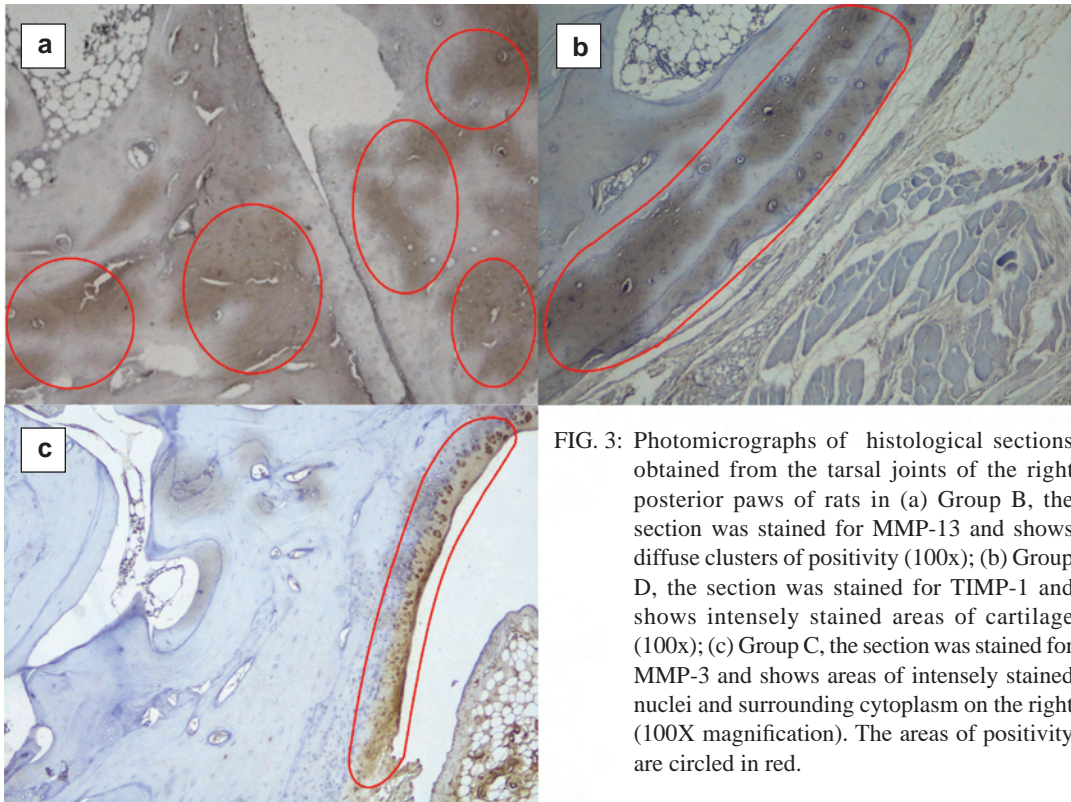


FIG. 3: Photomicrographs of histological sections obtained from the tarsal joints of the right posterior paws of rats in (a) Group B, the section was stained for MMP-13 and shows diffuse clusters of positivity (100x); (b) Group D, the section was stained for TIMP-1 and shows intensely stained areas of cartilage (100x); (c) Group C, the section was stained for MMP-3 and shows areas of intensely stained nuclei and surrounding cytoplasm on the right (100X magnification). The areas of positivity are circled in red.

Immunohistochemistry staining of cartilage MMPS and TIMP-1

Photomicrographs of the IHC staining results are shown as Figure 3. Figure 4 shows an overview of the findings which reflects the expression of MMP-3, MMP-13, and TIMP-1 in the joint cartilage of the five groups. Figure 3(a) shows that MMP-13 was diffusely over-expressed in the cellular cytoplasm, as indicated by the vivid

staining. TIMP-1 was well accentuated in the cellular cytoplasm as shown in Figure 3(b). Good expression of MMP-3 was observed in the cellular cytoplasm as well as the nuclei in sections as shown in Figure 3(c).

Figure 4 shows the percentage of maximum scores of each group. A score of 100% denotes the highest a group can achieve. MMP-13 expression increased as the dosage of the herbal extract was

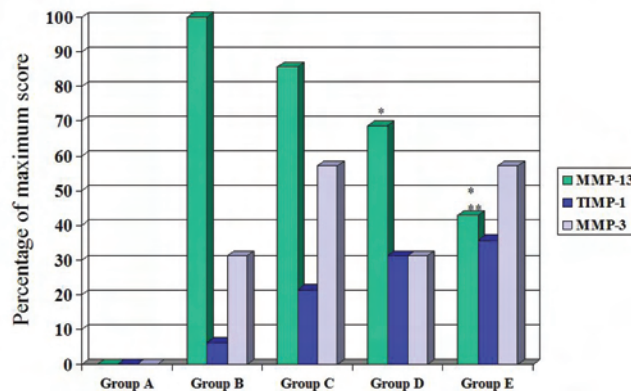


FIG. 4: The percentage of maximum scores for MMP-13, TIMP-1 and MMP-3 for each group. Group A is the non-arthritic group receiving water treatment. Group B to E are the arthritic groups. Group B received water treatment whereas Groups C, D and E received water extracts of *E. hirta* at 500 mg/kg, 100 mg/kg and 50 mg/kg respectively. Shows statistical significance from group B* ($p < 0.05$) and C** ($p < 0.001$).

increased. However, when comparing MMP-13 levels, Groups C, D and E showed lower MMP-13 levels than that of the arthritis-induced non-treated group at all dosages. Meanwhile, TIMP-1 expression decreased as the dosage of the herbal extract was increased. TIMP-1 levels were lowest in the arthritis-induced non-treated group. MMP-3 expression showed no appreciable trend with different dosages of the herbal extract.

DISCUSSION

The effects of Euphorbia hirta on histological findings

At the lowest experimental dose of 50mg/kg, the aqueous extract of *Euphorbia hirta* had the most beneficial effect as the cartilage joints showed the least signs of degeneration and inflammation. This effect was reduced as the dosage increased. This reversed correlation between dosage and histological result could be due to higher concentrations of the herbal extract causing toxicity from the levels of manganese, copper, zinc and nitrate found in *Euphorbia hirta*. It has been shown that the levels of these chemicals are high enough to constitute a source of toxicosis to animals that consume the herb.¹¹ This is supported by the findings of Huxley *et al.* that the sap containing latex is toxic on ingestion and highly irritant externally, causing severe inflammation especially on contact with eyes or open cuts. The toxicity can remain high even in dried plant material.¹²

Group A (Non-arthritis induced and non-treated control group)

Tissue samples from Group A rats were negative for MMP-13, TIMP-1 and MMP-3. This corresponds with the findings of Spinale, F. G. that MMP-13 is expressed in very low levels in normal tissue such as myocardium.¹³ Gabison *et al.* similarly report that MMP levels are so low as to be undetectable in corneal tissue except during wound healing.¹⁴ Elliot *et al.* also found that under normal circumstances, cellular basal levels of MMP-1 and MMP-13 were very low,¹⁵ while Phillips *et al.* also reported that TIMP-1 is found at a low basal level in most cell types.¹⁶

MMP-13

For MMP-13, Group B had the highest score, followed by Groups C, D, and E. Kamekura *et al.* found that MMP-13 expression was clearly positive in arthritic animals but only expressed in certain highly differentiated cells in the

control group.¹⁷ In this study, a low dose of aqueous extract of *Euphorbia hirta* seemed to reduce MMP-13 levels the most effectively. This may suggest that *Euphorbia hirta* may have a bell-shaped curve effect on cartilage MMP-13 expression. Therefore, further study needs to be done using lower dosages of *Euphorbia hirta* to properly study its effects.

MMP-3

In the non-arthritis induced control Group A, MMP-3 expression was not detectable, whereas all four arthritis-induced groups had detectable MMP-3 expressions at varying amounts. This could indicate that while MMP-3 is indeed involved in the pathophysiology of arthritis, its involvement is less direct than that of MMP-13 and TIMP-1. This could be due to the fact that MMP-3 is not a collagenase and thus cannot degrade the collagen found in cartilage, but is a stromelysin with broad-acting effects on various components of the extracellular matrix. Peeters-Joris *et al.* reported that collagenolytic, caseinolytic, gelatinolytic and proteoglycanolytic activities were mainly due to MMP-13, although MMP-3 was also present.¹⁸ In addition, TIMP-1 has greater effectiveness in the inhibition of MMP-9, MMP-1 and MMP-3 than other MMPs.¹⁹ This could be the reason for the levels of MMP-13 positivity being generally higher than that of MMP-3 in this study. No appreciable pattern of correlation was seen between the levels of TIMP-1 and MMP-3 in this study.

TIMP-1

In this study, Group E had the highest score for TIMP-1, while Group B had the lowest. The overall low score of TIMP-1 may be due to the fact that TIMP-1 is produced in low basal levels in most cell types and may not be visible in IHC under normal circumstances. However, Pang *et al.* reported detectable basal amounts of cellular TIMP-1.²⁰ This could possibly be due to the higher sensitivity of the ELISA method used in that study as opposed to IHC. The findings of this study display an inverse relationship between MMP-13 and TIMP-1. Rats fed with the lowest dose of *Euphorbia hirta* extract seemed to be the most effective at raising TIMP-1 levels and suppressing MMP-13 levels. This may suggest that *Euphorbia hirta* can either directly suppress MMP-13 or do so via the action of raised TIMP-1 levels.

Euphorbia hirta as an alternative or future form of treatment for arthritis

Most forms of treatment for arthritis are mainly symptomatic and aim to alleviate symptoms such as pain and swelling instead of addressing the underlying pathology of cartilage degeneration. The main exception to this is surgical intervention, which is an intrusive method of treatment and commonly cost-prohibitive. Common forms of treatment include non-steroidal anti-inflammatory drugs (NSAIDs) and painkillers. Glucosamine and chondroitin are used by many for osteoarthritis but Sawitzke *et al.* reported that this combination had not shown clinically important difference in joint space width loss in a 2-year glucosamine/chondroitin arthritis intervention trial.²¹ Another drug, Diacerin, a symptomatic slow-acting osteoarthritis drug which has been shown to be effective for the treatment of knee osteoarthritis and has a long carryover effect could be promising.²² Nevertheless, the inhibition of the enzymes involved in cartilage degeneration, including MMPs, continues to be a major therapeutic target. Janusz *et al.* found that the administration of MMP inhibitors to rats in a meniscal tear model of osteoarthritis resulted in significant inhibition of cartilage degradation and osteophyte formation.²³ In this study, it was found that *Euphorbia hirta* water extracts, at lower dosages, were able to improve the cartilage degeneration in arthritic joints. This effect of *Euphorbia hirta* water extracts is not like due to its capacity in lowering the level of MMP-13 expression and increasing the level of TIMP-1 expression. In addition, water extracts of *Euphorbia hirta* had been shown to have significant dose-dependant anti-inflammatory activity on acute inflammation.²⁴

Conclusion

In conclusion, these findings indicate that MMP-13 and TIMP-1 are good markers for cartilage degeneration and are heavily involved in the pathophysiology of arthritis. It is possible that *Euphorbia hirta* affects cartilage degeneration through MMP-13 pathways and TIMP-1 pathways, but not as directly through MMP-3 pathways. *Euphorbia hirta* displays dose-dependant effects on MMP-13 and TIMP-1 levels. As these mediators are involved in the pathogenesis of arthritis, it is possible that *Euphorbia hirta* may prove to be a viable alternative to current forms of treatment for arthritis.

ACKNOWLEDGEMENT

This study was supported by IMU research grants BMS-002-2005(03) and BMS I-02/2006(05). The authors would like to thank Ms Kellyn Fang from Centre of Medical Education, International Medical University for assisting in statistical analysis.

REFERENCES

1. Murphy G, Knäuper V, Atkinson S, Butler G, English W, Hutton M, Stracke J, Clark I. Matrix metalloproteinases in arthritic disease. *Arthritis Res* 2002; 4(3): 39-49.
2. Nagase H, Visse R, Murphy G. Structure and function of matrix metalloproteinases and TIMPs. *Cardiovas Res* 2006; 69: 562-73.
3. Overall CM, Lopez-Otin C. Strategies for MMP inhibition in cancer: innovations for the post-trial era. *Nat Rev Cancer* 2002; 2: 657-72.
4. Visse R, Nagase H. Matrix metalloproteinases and tissue inhibitors of metalloproteinases: structure, function, and biochemistry. *Circ Res* 2003; 92: 827-39.
5. Woessner JF, Nagase H. Matrix metalloproteinases and TIMPs. Oxford, (UK): Oxford University Press; 2000.
6. Hembry RM, Bagga MR, Reynolds JJ, Hamblen DL. Immuno-localisation studies on six matrix metalloproteinases and their inhibitors, TIMP-1 and TIMP-2, in synovia from patients with osteo- and rheumatoid arthritis. *Ann Rheum Dis* 1995; 54: 25-32.
7. Fuchs S, Skwara A, Bloch M, Dankbar B: Differential induction and regulation of matrix metalloproteinases in osteoarthritic tissue and fluid synovial fibroblasts. *Osteoarthr Cartil* 2004; 12: 409-18.
8. Plants for a Future [Online] 2006 October 1 [cited 2007 June 20] URL: http://www.ibiblio.org/pfaff/cgi-bin/arr_html?Euphorbia+hirta#WEBREFS
9. Tropilab © Inc. [Online] 2007 [cited 2007 June 20] URL: <http://www.tropilab.com/astmaweed.html>
10. Donaldson LF, Seckl JR, McQueen DS. A discrete adjuvant-induced monoarthritis in the rat: effect of adjuvant dose. *J Neurosci Methods* 1993; 49: 5-10
11. Adedapo AA, Abatan MO, Olorunsogo OO. Phytochemical Analysis of the Leaves of *Phyllanthus amarus* and *Euphorbia hirta*. *Trop Vet* 2004; 22 (1): 16-22.
12. Huxley A. *The New RHS Dictionary of Gardening*. MacMillan Press; 1992. ISBN 0-333-47494-5
13. Spinale FG. Matrix Metalloproteinases: Regulation and Dysregulation in the Failing Heart. *Circ Res* 2002; 90: 520-30.
14. Gabison EE, Mourah S, Steinfels E, Yan L, Huang-Xuan T, Watsky MA *et al.* Differential Expression of Extracellular Matrix Metalloproteinase Inducer (CD147) in Normal and Ulcerated Corneas. *Am J Pathol* 2005; 166: 209-19
15. Elliott S, Hays E, Mayor M, Sporn M, Vincenti M.

- The triterpenoid CDDO inhibits expression of matrix metalloproteinase-1, matrix metalloproteinase-13 and Bcl-3 in primary human chondrocytes. *Arthritis Res Ther* 2003; 5(5): 285-91.
16. Phillips BW, Sharma R, Leco PA, Edwards DR. A sequence-selective single-strand DNA-binding protein regulates basal transcription of the murine tissue inhibitor of metalloproteinases-1 (*timp-1*) gene. *J Biol Chem* 1999; 274(32): 22197-207
 17. Kamekura S, Hoshi K, Shimoaka T, Chung U, Chikuda H, Yamada T *et al.* Osteoarthritis development in novel experimental mouse models induced by knee joint instability. *Osteoarthritis and Cartilage* 2005; 13: 632-41.
 18. Peeters-Joris C, Hammani K, Singer CF. Differential regulation of MMP-13 (collagenase-3) and MMP-3 (stromelysin-1) in mouse calvariae. *Biochim Biophys Acta* 1998; 1405 (1-3): 14-28
 19. Woessner JF Jr. Matrix metalloproteinases and their inhibitors in connective tissue remodeling. *FASEB J.* 1991; 5: 2145-54.
 20. Pang I, Hellberg PE, Fleenor DL, Jacobson N, Clark AF. Expression of matrix metalloproteinases and their inhibitors in human trabecular meshwork cells. *Invest Ophthalmol Vis Sci* 2003; 44 (8): 3485-93.
 21. Sawitzke AD, Shi H, Finco MF, Dunlop DD, Bingham III CO, Harris CL, et al. The effect of glucosamine and/or chondroitin sulfate on the progression of knee osteoarthritis: A report from the glucosamine/chondroitin arthritis intervention trial. *Arthritis Rheum* 2008; 58 (10): 3183-91.
 22. Pavelka K, Trc T, Karpas K, Vitek P, Sedláčková M, Vlasáková V, Böhmová J, Rovenský J. The efficacy and safety of diacerein in the treatment of painful osteoarthritis of the knee: A randomized, multicenter, double-blind, placebo-controlled study with primary end points at two months after the end of a three-month treatment period. *Arthritis Rheum* 2007; 56 (12): 4055-64.
 23. Janusz MJ, Bendele AM, Brown KK, Taiwo YO, Hsieh L, Heitmeyer SA. Induction of osteoarthritis in the rat by surgical tear of the meniscus: Inhibition of joint damage by a matrix metalloproteinase inhibitor. *Osteoarthr Cartil* 2002; 10: 785-91
 24. Lanhers MC, Fleurentin J, Dorfman P, Mortier F, Pelt JM. Analgesic, antipyretic, and anti-inflammatory properties of *Euphorbia hirta*. *Planta Med* 1991; 57(3): 225-31.