

Case Report

A Case of Right Upper Abdominal Pain Misdiagnosed on Computerized Tomography

Seema SINGH, Ashesh Kumar JHA, Naveen SHARMA, Tushar Subhadarshan MISHRA

Submitted: 14 Nov 2013

Accepted: 13 Mar 2013

Department of Surgery, University College of Medical Sciences & GTB Hospital, Dilshad Garden, Delhi-110095, India

Abstract

Right upper abdominal pain is a common symptom in patients presenting to surgery emergency. Most of these cases can be diagnosed accurately on clinical evaluation or imaging. We report an unusual case of right upper abdominal pain, which could not be diagnosed correctly preoperatively despite using various imaging modalities.

Keywords: abdominal pain, appendix, perforation, imaging

Introduction

A number of patients present to surgery emergency with right upper abdominal pain, which usually can be diagnosed accurately based on clinical and radiological findings. However, we encountered a case of right upper abdominal pain due to a perforated subhepatic appendix, which was misdiagnosed as gall bladder perforation even on contrast-enhanced computerized tomography (CECT) of the abdomen. Acute appendicitis is a common surgical emergency (1). The clinical presentation of this entity differs with the varying positions of the appendix. Appendicitis in the subhepatic position is one such rare condition that is often misdiagnosed as acute cholecystitis or hepatic abscess (2,3).

The present case is being reported for its rarity and diagnostic dilemma, and to highlight the fact that even ultrasonography (USG) or computerized tomography (CT) may not be able to successfully diagnose this condition preoperatively.

Case Report

A 55-year-old woman was admitted to the surgery emergency with right upper abdominal pain along with fever, chills, and vomiting for eight days. On examination, she had tenderness in the right hypochondrium without any guarding or rigidity. USG of the abdomen revealed gall stones with minimal free fluid in the hepatorenal pouch. She was diagnosed as a case of acute cholecystitis and started on conservative treatment. After three days of this treatment, an ill-defined lump was noted in the

right hypochondrium. A repeat USG showed an abscess in the right lobe of the liver, the aspiration of which failed. A CECT of the abdomen was done, which revealed gall bladder calculus with pericholecystic collection and inflammatory fat stranding in the pericholecystic region (Figure 1). There was a subcapsular collection along the right lobe of the liver with an air locule within,

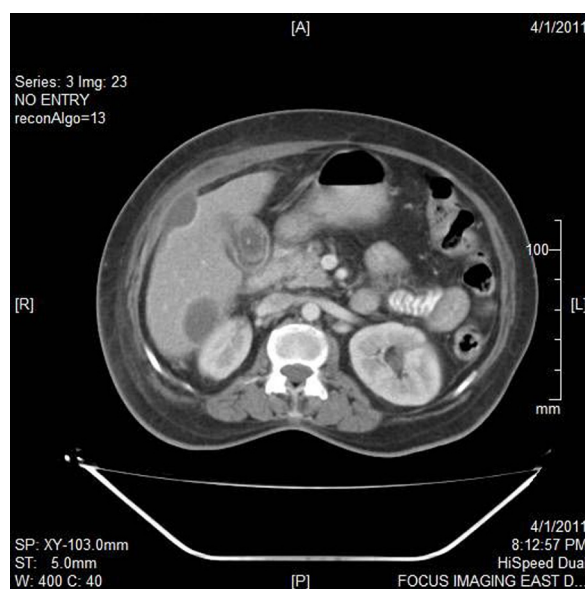


Figure 1: Contrast-enhanced computerized tomography (CECT) of the abdomen showing gall bladder calculus with pericholecystic collection and inflammatory fat stranding in the pericholecystic region.

which was abutting the anterior abdominal wall and causing buckling of the hepatic parenchyma (Figure 2). Based on this clinical and radiological picture, a gall bladder perforation was suspected and the patient was taken for an exploratory laparotomy.

On laparotomy, a purulent collection with dense omental adhesions was noted in the right upper quadrant of the abdomen. The cecum was subhepatic in position with a gangrenous, perforated, subhepatic appendix. The gall bladder was not perforated. An appendicectomy with cholecystectomy was done. The patient was discharged from the hospital on post-operative day 15 and continues to be well on follow-up.

Discussion

The demonstration of gallstones by ultrasound in a patient with right upper quadrant pain, tenderness, fever, and leucocytosis is usually considered enough evidence to warrant a diagnosis of acute cholecystitis (2). However, there have been many reported incidences in the literature where what was thought to be a hepatobiliary pathology in a case of right upper abdominal pain turned out to be an appendicular pathology on surgery or further imaging. In a case of recurrent right upper quadrant pain reported by Ball and Privitera (4), the patient had already

undergone a laparoscopic cholecystectomy for her symptoms before being diagnosed as a case of subhepatic appendix on diagnostic laparoscopy. Algin et al. (5) recently reported a case of subhepatic retrocecal appendicitis mimicking acute cholecystitis on USG with the presence of pericholecystic fluid—as in our patient.

Patel et al. (2) have reported a case of subhepatic appendix with fecalith, which mimicked acute cholecystitis with gallstones. Rangarajan et al. (3) reported the case of a perforated subhepatic appendix, which was diagnosed as a liver abscess on USG as well as on CT. In a series of four cases of right upper quadrant pain, reported in 2009 by Ong and Venkatesh (6), two were initially diagnosed as acute cholecystitis and two had a subhepatic collection on ultrasound. However, CT could make an accurate diagnosis of appendicitis in all the four cases (6). In our case, even the CT scan gave a probable diagnosis of perforated gall bladder. We did not find any reported case of perforated subhepatic appendix mimicking gall bladder perforation even on a CT scan.

Acute appendicitis is one of the most common clinical conditions requiring emergency general surgery. This condition can be diagnosed clinically in most cases. USG is frequently used for the assessment of suspected cases, especially in young children, but it requires expertise and dedicated techniques, such as graded compression (7). Due to the shortcomings of ultrasound, a CT has often been advocated as it has been shown to be more sensitive than ultrasound in diagnosing acute appendicitis (6).

However, the classical clinical picture of appendicitis may not always be present due to variations in the position of the appendix. The commonly reported positions of the appendix are retrocecal (74%), pelvic (21%), subcecal (1.5%), preileal (1%), and postileal (0.5%) (1). The rarer types include subhepatic, lateral pouch, mesocolic, left-sided, intraherniary, and lumbar. Reports of appendicitis in these rare positions are scarce in literature. Inflammation of a subhepatic appendix has been reported to account for only 0.09% of all cases of appendicitis in one study (8).

The subhepatic position of the appendix has been attributed to a failure of descent of the cecum during embryonic development (9). This abnormal position of the cecum and the appendix makes the clinical diagnosis of subhepatic appendicitis almost impossible. These patients usually present with right upper quadrant pain, which may mimic acute cholecystitis, liver abscess, ureteric colic, or acute pyelonephritis—the most common of which are acute cholecystitis and liver abscess (8). The

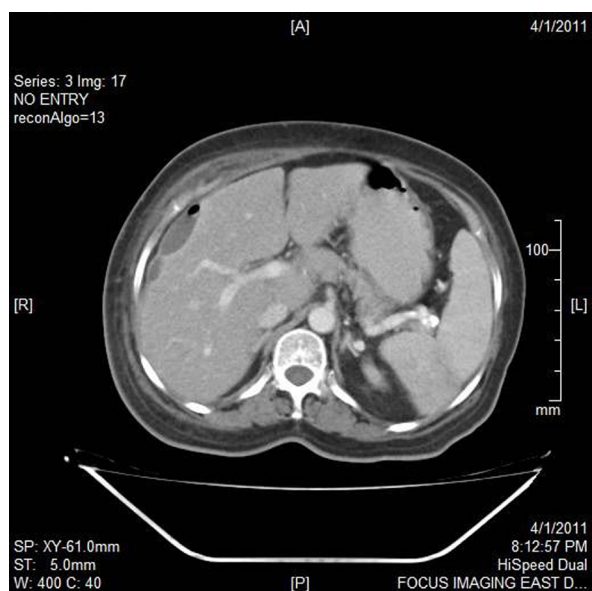


Figure 2: Contrast-enhanced computerized tomography (CECT) of the abdomen showing a subcapsular collection along the right lobe of the liver with an air locule within.

ultrasound in our patient initially showed only gall stones; the liver abscess was revealed later.

Palanivelu et al. (8) have described the use of a tailored approach of laparoscopic surgery in these cases. Ates et al. (10) have also recommended the use of laparoscopy in patients with suspected appendicitis in whom the diagnosis cannot be made by physical examination and noninvasive methods. The role of the colonoscopy has also been evaluated in the diagnosis of appendicitis in patients with atypical presentation due to an unusual location of the appendix. Chang et al. (11), in a study published in 2002, concluded that, "Colonoscopy may be useful in the diagnosis of appendicitis when the clinical presentation is atypical for appendicitis and/or imaging studies are nondiagnostic (p.343)." Magnetic resonance imaging has also been found to be useful in visualizing the appendix in an atypical location (12). However, in the absence of the availability of emergency laparoscopic surgery or advanced imaging, the surgical management of these patients can be challenging. A delay in the diagnosis of subhepatic appendicitis may then lead to complications such as perforation and peritonitis.

Acknowledgement

None.

Conflict of Interest

None.

Funds

None.

Authors' Contributions

Conception and design and drafting of the article: SS

Analysis and interpretation of the data: AKJ

Critical revision of the article for the important intellectual content: NS

Final approval of the article: TSM

Correspondence

Dr Seema Singh
MBBS (BHU), MS (BHU)
1203, Antriksh Green
Kaushambi, Ghaziabad
Uttar Pradesh-201010, India
Tel: + 91-981886 6619
Email: drseemas@gmail.com

References

1. Ronan O'Connell P. The vermiform appendix. In: Williams NS, Bulstrode CJK, Ronan O'Connell P, editors. *Bailey & Love's Short practice of Surgery*. London (LN): Edward Arnold (Publishers) Ltd; 2008. p. 1204–1218.
2. Patel NR, Lakshman S, Hays TV, Thomas E. Subhepatic appendix with fecalith mimicking acute cholecystitis with gallstone. *J Clin Ultrasound*. 1996;**24**(1):45–47.
3. Rangarajan M, Palanivelu C, Senthilkumar R, Madankumar MV. Appendicular abscess masquerading as a liver abscess: value of laparoscopy in diagnosis and management. *Intern J Surg*. 2006;**4**(1).
4. Ball WR, Privitera A. Subhepatic appendicitis: a diagnostic dilemma. *BMJ Case Reports*. 2013. doi: 10.1136/bcr-2013-009454.
5. Algin O, Özmen E, Özcan AS, Erkekel S, Karaoğlanoğlu M. Unusual manifestation of acute retrocecal appendicitis: pericholecystic fluid. *Ulus Travma Acil Cerrahi Derg*. 2013;**19**(1):80–82. doi: 10.5505/tjtes.2013.74508.
6. Ong EMW, Venkatesh SK. Ascending retrocecal appendicitis presenting with right upper abdominal pain: Utility of computed tomography. *World J Gastroenterol*. 2009;**15**(28):3576–379.
7. Lee JH, Jeong YK, Park KB, Park JK, Jeong AK, Hwang JC. Operator-dependent techniques for graded compression sonography to detect the appendix and diagnose acute appendicitis. *Am J Roentgenol*. 2005;**184**(1):91–97.
8. Palanivelu C, Rangarajan M, John SJ, Senthilkumar R, Madhankumar MV. Laparoscopic appendectomy for appendicitis in uncommon situations: the advantages of a tailored approach. *Singapore Med J*. 2007;**48**(8):737–740.
9. Linder HH. Embryology of gastrointestinal tract. In: Linder HH, editor. *Clinical Anatomy*. East Norwalk (CT): Appleton & Lange; 1989. p. 275–282.
10. Ates M, Sevil S, Bulbul M. Routine use of laparoscopy in patients with clinically doubtful diagnosis of appendicitis. *J Laparoendosc Adv Surg Tech A*. 2008;**18**(2):189–193. doi: 10.1089/lap.2007.0040.
11. Chang HS, Yang SK, Myung SJ, Jung HY, Hong WS, Kim JH, Min YI, Ha HK, Kim JC, Yu CS, Kim HC, Kim JS. The role of colonoscopy in the diagnosis of appendicitis in patients with atypical presentations. *Gastrointest Endosc*. 2002;**56**(3):343–348.
12. Lutfi I. Appendicitis Imaging [Interenet]. New York (NY): Medscape; 2014 [cited 2014 Feb 20]. Available from: <http://emedicine.medscape.com/article/363818-overview>.