

# Mirizzi Syndrome Type II with Cholecystoduodenal Fistula: An Infrequent Combination

Mohammad Shazib FARIDI<sup>1</sup>, Anshuman PANDEY<sup>2</sup>

Submitted: 19 Nov 2012  
Accepted: 17 Feb 2013

<sup>1</sup> Department of Surgery, University College of Medical Sciences & Guru Tegh Bahadur Hospital, Dilshad Garden, Delhi, 110095, India

<sup>2</sup> Department of Gastro-Surgery, Chatrapati Shahuji Maharaj Medical University, Lucknow, UP, 226013, India

## Abstract

We report a case of Mirizzi syndrome type II associated with biliary enteric fistula. It is important to identify this combination early, as it is associated with high morbidity. In our case, intraoperative findings were cholecystoduodenal fistula and communication of Hartmann's pouch with common bile duct (CBD). A subtotal cholecystectomy with excision of cholecystoduodenal fistula was performed. A minimal surgical maneuver of Calot's Triangle with repair of cholecystoduodenal fistula is required during the intraoperative period.

**Keywords:** cholecystoduodenal fistula, gallstones, Mirizzi syndrome

## Introduction

Mirizzi syndrome is uncommon, only around 1% (1). Mirizzi syndrome type II with associated biliary enteric fistula is even rarer. To our knowledge, there is only one reported case that refers to coexistence of Mirizzi type II syndrome with a parapapillary choledochoduodenal fistula (2). It is important to identify Mirizzi syndrome and fistula formation because of serious morbidity and mortality related to the condition (3). Correct surgical approach and management are very important as chronic biliary tree inflammation and bile duct anatomic alteration necessitate a meticulous technique.

## Case Report

A 30-year-old woman presented with pain in right hypochondrium, intermittent fever and jaundice. There was associated anorexia and occasional non bilious vomiting. There was evidence of icterus, and clinical abdominal evaluation was normal. Blood tests: total bilirubin 2.61 mg/dL (normal 0.2–1 mg/dL), conjugated bilirubin 1.6 (normal < 0.2 mg/dL), serum glutamic oxaloacetic transaminase (SGOT) 50 U/L (normal 5–40 U/L), serum glutamic-pyruvic transaminase (SGPT) 62 U/L (normal 5–40 U/L), alkaline phosphatase 156 U/L (< 106 U/L), glutamyl transferase 110 U/L (normal

< 45 U/L). Ultrasound abdomen showed large calculus located in cystic duct and compressing over proximal CBD. Computed tomograph abdomen showed large calculus at Hartmann's pouch, which was contracted, compressing upon proximal common bile duct (CBD); there was no pneumobilia and vascular anatomy was normal (Figure 1). The final diagnosis was made intra operatively.

There were dense adhesions in the right sub hepatic space and two anatomic alterations were observed. The first was cholecystoduodenal communication with second part of duodenum and fundus of gall bladder and associated communication of Hartmann's pouch with CBD in presence of large impacted stone (Figure 2, 3). Excision of cholecystoduodenal fistulous tract and suturing duodenal wall in two layers were done with subsequent extraction of 25 mm mixed stone through an incision in gallbladder fundus. Intraoperative cholangiogram revealed dilated right and left hepatic ducts and normal distal CBD of normal calibre. There were no other stones. A subtotal cholecystectomy with choledochoplasty was done with the remnant gallbladder after cauterizing the mucosa. Histopathology was suggestive of cholecystitis. Post-operative course was uneventful and patient was discharged after one week of operation. At the eight month follow-

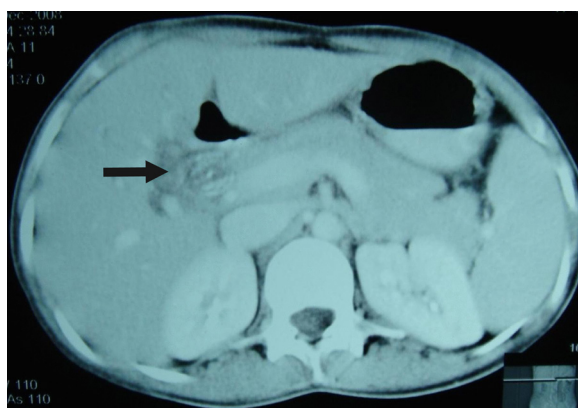
up, patient was asymptomatic.

## Discussion

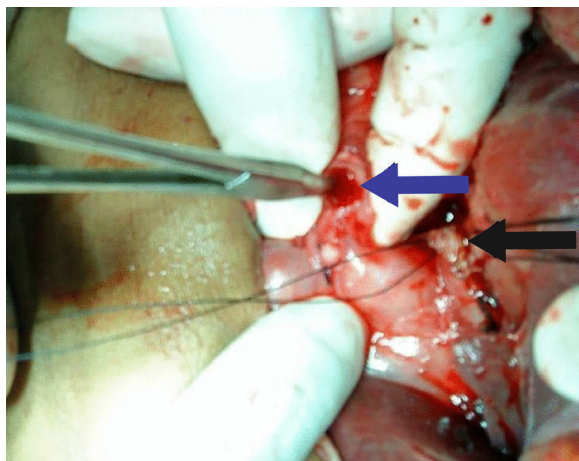
Mirizzi syndrome is a rare complication of chronic cholelithiasis that consists of inflammatory process of gall bladder wall and direct compression or erosion of CBD and subsequent fistula formation (4). After Mirizzi and McSherry, most prominent classification was made by Csendes, according to whom Mirizzi syndrome consists of direct extraneous compression of CBD (type I) or erosion of CBD and subsequent fistula formation (type II, III, IV). In his study, Csendes et al. reported that of 219 patients 11% of patients were of type I Mirizzi syndrome; 41%, 44%, 4% had type II, III, IV respectively (5).

Spontaneous biliary enteric fistula has also been rarely reported (1.2–5%) (6). The most common type of biliary enteric fistula is cholecystoduodenal (75%); cholecystocolic is the next common (10–20%), with a variety of other types being less common (15%) (7). According to Bauer (8), best management of Mirizzi syndrome type II is to avoid dissection of Calot's Triangle to avoid injury to CBD and to perform subtotal cholecystectomy with cholecystoenteric anastomosis. The proper surgical treatment mentioned in literature is partial cholecystectomy and a biliary drainage procedure (roux en y anastomosis), especially in types III and IV. Recognition of this syndrome is important to avoid inadvertent ligation or severance of the bile duct. An attempt to expose Calot's Triangle may lead to severe bile duct injury such as: (i) Iatrogenic communication between the gall bladder and CBD; (ii) complete transaction of the CBD after dissection of gall bladder neck; (iii) tear of CBD (3).

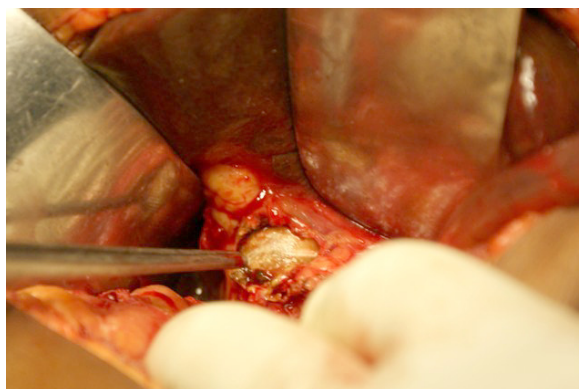
In our case, the associated cholecystoduodenal fistula was probably due to intense inflammation and erosion of duodenal wall at a site away from gall bladder neck. Excision of cholecystoduodenal fistula and repair with subtotal cholecystectomy and choledochoplasty was done. Due to presence of severe adhesion, cholecystoenteric anastomosis was avoided. Per operative cholangiogram revealed dilated right and left hepatic ducts and normal distal CBD of normal calibre. The rarity of this combination and the pre-operative recognition remains a challenge for the surgeon (9). Open operation for Mirizzi Syndrome is accepted as the reported incidence rate of conversion to open cholecystectomy was remarkably high, with a range of 37–78% (10).



**Figure 1:** In computed tomography scan, arrow shows large calculus in Hartmann's pouch compressing upon proximal common bile duct (CBD).



**Figure 2:** Blue arrow shows excised cholecystocholedochal fistula and black arrow shows excised cholecystoduodenal fistula.



**Figure 3:** A large impacted stone at Hartmann's pouch.

Primary repair of cholecystoduodenal fistula and minimal surgical maneuvers of Calot's Triangle at the time of operation for Mirizzi syndrome type II in order to avoid bile duct injury are two important key points for successful management of these clinical entities.

### Acknowledgement

None.

### Conflict of Interest

None.

### Funds

None.

### Authors' Contributions

Conception and design, drafting of the article collection and assembly of data: MSF  
Analysis and interpretation of the data Critical revision of the article for the important intellectual content Final approval of the article: AP

### Correspondence

Dr Mohammad Shazib Faridi  
MCh General Surgery (Era's Lucknow Medical College)  
Department of Surgery  
University College of Medical Sciences & Guru Tegh  
Bahadur Hospital, Dilshad Garden  
Delhi, 110095, India  
Tel: +0091 9868 399529  
Fax: +9111 2259 0495  
Email: drshazibfaridi@gmail.com

### References

1. Redaelli CA, Buchler MW, Schilling MK, Krähenbühl L, Ruchti C, Blumgart LH, et al. High coincidence of Mirizzi syndrome and gallbladder carcinoma. *Surgery*. 1997;**121**(1):58–63.
2. Harrison N, Hashimoto L. Coexistence of Mirizzi Type II syndrome with a parapapillary choledochoduodenal fistula: a case report. *Curr Surg*. 2002;**59**(4):416–417.
3. Contini S, Dalla Valle R, Zinicola R, Botta GC. Undiagnosed Mirizzi's Syndrome: a word of caution for laparoscopic surgeons—a report of three cases and review of the literature. *J Laparoendosc Adv SurgTech A*. 1999;**9**(2):197–203.
4. Johnson LW, Sehon JK, Lee WC, Zibari GB, McDonald JC. Mirizzi's syndrome: Experience from a multi-institutional review. *Am Surg*. 2001;**67**(1):11–14.
5. Csendes A, Diaz JC, Burdiles P, Maluenda F, Nava O. Mirizzi syndrome and cholecystobiliary fistula: a unifying classification. *Br J Surg*. 1989;**76**(11):1139–1143. doi: 10.1002/bjs.1800761110.
6. England RE, Martin DF. Endoscopic management of Mirizzi's syndrome. *Gut*. 1997;**40**(2):272–276. doi: 10.1136/gut.40.2.272.
7. Elsas LJ, Gilat T. Cholecystocolonic fistula with malabsorption. *Ann Intern Med*. 1965;**63**(3):481–486. doi: 10.7326/0003-4819-63-3-481.
8. Bauer HU, Matthews JB, Schweiser WP, Gertsch P, Blumgart LH. Management of the Mirizzi syndrome and the surgical implications of cholecystocholedochal fistula. *Br J Surg*. 1990;**77**(7):743–745.
9. Memon M, Tahir SM, Ali SA, Shaikh AR, Muneer A, Shaikh NA. Mirizzi Syndrome: An unusual presentation of cholelithiasis. *Rawal Med J*. 2010;**35**(1):68–71.
10. Mithani R, Schwesinger WH, Bingener J, Sirinek KR, Gross GW. The Mirizzi syndrome: multidisciplinary management promotes optimal outcomes. *J Gastrointest Surg*. 2008;**12**(6):1022–1018. doi: 10.1007/s11605-007-0305-x.