

A Case Report of Atypical Teratoid/Rhabdoid Tumour in a 9-Year-Old Girl

Kin Hup CHAN¹, Mohammed Saffari MOHAMMED HASPANI², Yew Chin TAN¹, Fauziah KASSIM³

Submitted: 22 Oct 2009
Accepted: 20 Mar 2011

¹ Department of Neurosciences, School of Medical Sciences, Universiti Sains Malaysia, 16150 Kubang Kerian, Kelantan, Malaysia

² Department of Neurosurgery, Hospital Kuala Lumpur, Jalan Pahang, 50586 Kuala Lumpur, Malaysia

³ Department of Pathology, Hospital Kuala Lumpur, Jalan Pahang, 50586 Kuala Lumpur, Malaysia

Abstract

Primary central nervous system atypical rhabdoid/teratoid tumour (ATRT) is a rare and highly malignant tumour that tends to occur in infancy and early childhood. The majority of tumours (approximately two-third) arise in the posterior fossa. The optimal treatment for ATRT remains unclear. Options of treatment include surgery, radiotherapy, and chemotherapy. Each of their role is still not clearly defined until now. The prognosis of the disease is generally unfavourable. This is a case report of ATRT in an atypical site in a 9-year-old girl.

Keywords: central nervous system neoplasms, child, oncology, recurrence, rhabdoid tumour, teratoma

Introduction

Atypical rhabdoid/teratoid tumour (ATRT) of the central nervous system (CNS) is a rare and malignant tumour that usually occurs in early childhood. This type of tumour was first described as a histological variant of Wilm's tumour that mainly occurs in infants and has a very poor prognosis. A CNS tumour of rhabdoid cells was first described in 1985, but its clinical and pathological features were not well defined until 1995–1996 (1).

The age at presentation is usually less than 2 years. However, it has also been reported to occur in older children and adults (2). Disseminated forms occur in 20% to 30% of cases. Patients with ATRT typically follow a dismal course, and the median time to death is only a few months after the diagnosis (3,4).

Radiological findings are non-specific (3,5). ATRT shares some morphological features with medulloblastoma and can also closely resemble choroid plexus papillomas (6). The histological hallmark of ATRT is the presence of rhabdoid cells; these cells have brightly eosinophilic cytoplasm, large and eccentrically placed nuclei, and a single prominent nucleolus each, with or without fibrillary globoid inclusions (6).

Because of its rarity and rapid course, there has been no consensus as to the optimal treatment of this tumour. However, surgery, radiation therapy, and chemotherapy may all play a role (7).

We report an unusual case of ATRT occurring in the temporal lobe of a 9-year-old girl.

Case Report

A previously healthy 9-year-old girl presented to our neurosurgical outpatient department with a 2-month history of progressive right hemiparesis. The onset was insidious and involved both the upper and lower limbs. There was no numbness or sensory loss. She experienced associated intermittent headaches that were worse in the morning but had no vomiting. There were no other neurological or systemic complaints.

On examination, the child was afebrile and had stable vital signs. She was alert, cooperative, and had intact higher mental functions. Her speech was normal, and her cranial nerves were intact. Her right upper and lower limbs were hypertonic compared with the left limbs and had grade 3 power. Reflexes were brisk with an extensor Babinski response on the right. Sensation was intact.

Magnetic resonance imaging (MRI) of her brain was done, but it was incomplete because of the patient's uncooperativeness. T1, T2, and fluid-attenuated inversion recovery sequences were obtained, but no contrast study was done. The results (Figure 1) showed a huge, lobulated intra-axial tumour occupying almost the whole left temporal lobe. It was mainly hypointense to grey matter on T1- and T2-weighted sequences. There were cystic components, as evidenced by areas of hyperintensity on T2-weighted images. It was large enough to cause effacement of the ipsilateral basal cisterns and a mild line shift of about 5 mm.

The patient underwent surgery to excise the tumour. During surgery, the tumour was found to be encapsulated, but it had diffusely infiltrated normal brain tissue in some areas. It was greyish, friable, and moderately vascular. The tumour was subtotaly excised because of its infiltration of surrounding eloquent tissue. The patient recovered well post-operatively but her hemiparesis remained. On follow-up 1 month later, she had developed left 3rd cranial nerve palsy (Figure 2). Repeat computed tomography and MRI showed a recurrence of the tumour at the same location (Figures 2 and 3). Spinal

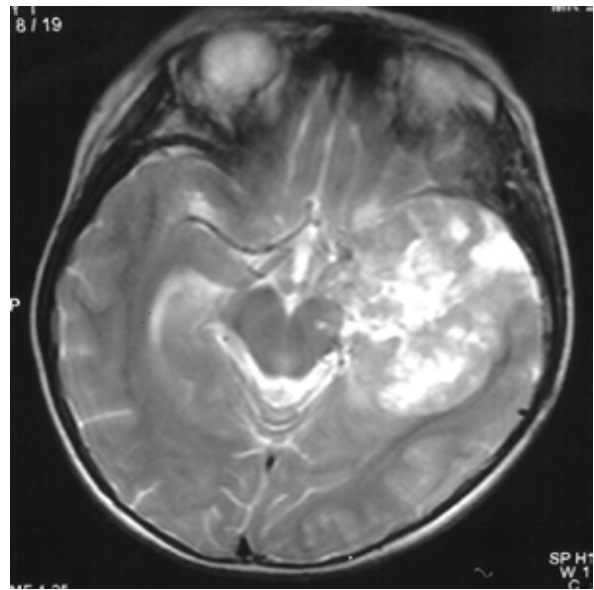


Figure 2: Post-operative T2 weighted magnetic resonance 1 month after surgery showed that the tumour had recurred to almost the same size of the previous tumour.

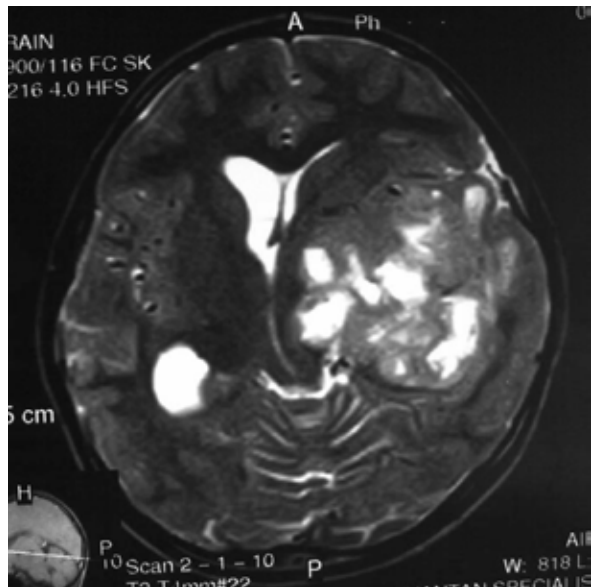


Figure 1: Pre-operative T2 weighted magnetic resonance image showing a large intraaxial tumour in the left temporal lobe, which was hypo- to isointense to the grey matter and had internal cystic components.

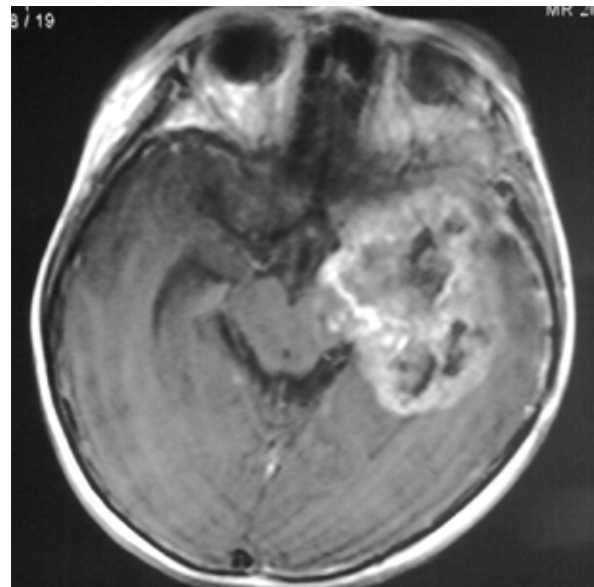


Figure 3: Gadolinium-enhanced magnetic resonance image 1 month after surgery showed a non-homogeneously enhancing tumour with central areas of necrosis extending into the interpeduncular cisterns causing the third cranial nerve palsy.

dissemination could not be determined because a spinal MRI was not performed. However, there were no areas of leptomeningeal enhancement on the brain MRI to suggest cerebrospinal fluid (CSF) dissemination. Repeat surgery was performed and the patient was referred to the oncology team for radiation therapy.

Histological sections (Figure 4) showed a malignant tumour composed of cells arranged in a diffuse pattern interspersed in areas with dilated vascular channels and areas of necrosis. The tumour cells showed a mixture of primitive cells with scant cytoplasm, hyperchromatic nuclei, and epithelioid cells that are larger than normal. There were also rhabdoid cells with abundant eosinophilic cytoplasm and large vesicular nuclei containing nucleoli. There were some areas showing cords and strands of tumour cells with abundant chondromyxoid matrix. The mitotic activity was brisk.

Immunohistochemical staining (Figures 5 and 6) was positive for vimentin, glial fibrillary acidic protein (GFAP), and epithelial membrane antigen (EMA). Stains for synaptophysin, smooth muscle actin (SMA), and neurofilament were negative.

These features were consistent with a diagnosis of ATRT (World Health Organization grade IV). The patient was eventually lost during the follow-up period. A phone call to the patient's home revealed that the patient passed away at home 6 months after the onset of the disease.

Discussion

ATRT of the CNS are rare and present mainly in early childhood. They comprise 2%–3% of tumours in children under the age of 18 years and have a slight male predominance, with a male to female ratio of 1.6:1 (8). However, most patients who are diagnosed are younger than 3 years of age. The majority of these tumours (approximately two-third) occur in the posterior fossa (8,9). Other areas reported to be affected include the cerebral hemispheres, the pineal region, and the spine (10). Up to one-third of patients have CSF dissemination at diagnosis (4).

This is a case report of ATRT that occurred in a 9-year-old girl in the supratentorial region at the left temporal lobe. These tumours are highly aggressive and have malignant local infiltration, making total excision unfeasible if the tumour is in eloquent areas, as was the case for this patient. Prognosis is dismal, with a median survival of 6 months. Those with CSF dissemination have

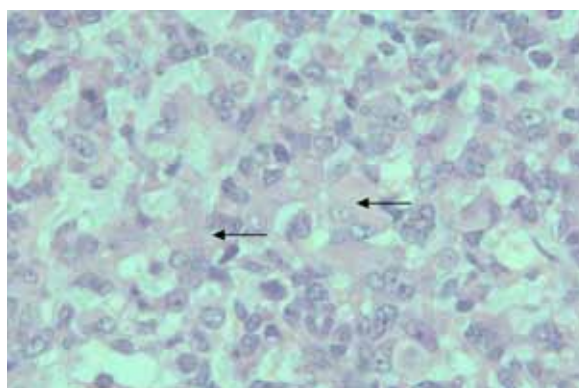


Figure 4: Haematoxylin and eosin stain of tumour tissue showing rhabdoid cells (arrows) with eccentrically placed vesicular nuclei and brightly eosinophilic cytoplasm. Some of the cells showed mitotic activity.

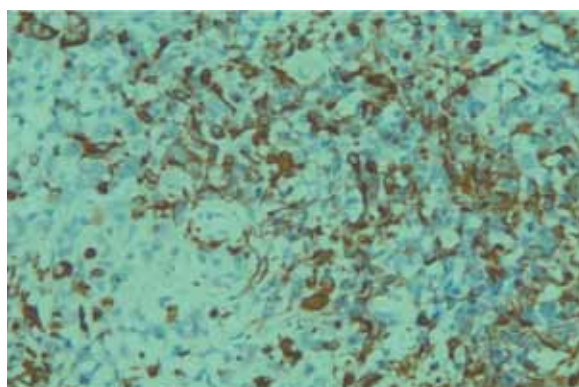


Figure 5: The tumour tissue stained positive for vimentin by immunohistochemistry.

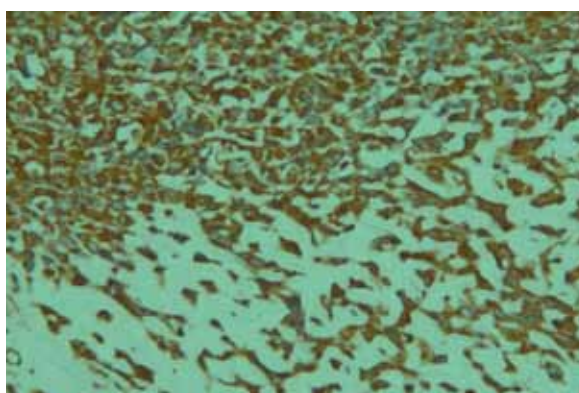


Figure 6: Tumour tissue stained positive for glial fibrillary acidic protein by immunohistochemistry.

been reported to survive only up to 2.5 months. This is especially true for children below 3 years of age. Moreover, children of this age group are more likely to have dissemination at diagnosis and have a faster rate of progression (4). In our case, the patient had already presented with a local recurrence and a new deficit just 1 month after subtotal excision. Dissemination at the time of recurrence could not be determined in this case because, even though brain MRI showed no area of leptomeningeal enhancement, no MRI of the spine was performed.

Histologically, the appearance of ATRT can vary, although the characteristic feature is the presence of rhabdoid cells (1,6). The cells have been described as medium to large cells with eccentrically placed nuclei and brightly eosinophilic cytoplasm equal to, or larger than, the size of the nucleus. The nuclei frequently contain prominent nucleoli (6). These features were present in this case. In addition, ATRT can have areas resembling medulloblastoma/primitive neuroectodermal tumours, containing small, primitive looking neuronal cells with hyperchromatic nuclei and anaplasia (1). Rosette formation could also be seen (1). Our patient's tumour had this type of appearance. It is therefore important to have a differential diagnosis of ATRT in mind, especially in younger children.

On immunohistochemical staining, ATRT stain positive for vimentin, GFAP, EMA, cytokeratins, synaptophysin, chromogranin, and SMA (11). In our case, staining was positive for vimentin, GFAP, and EMA.

The optimal treatment for ATRT remains unclear. To date, the role of surgery for ATRT has not been well defined. While surgery is effective in reducing the mass, children who receive surgery without adjuvant therapy can die within a month (12). The role of the extent of surgery in different locations is also unclear. To achieve gross total resection, some authors have recommended aggressive surgical excision, including second surgery where feasible (4). Chemotherapy also has a part to play in treatment of this tumour, especially in children younger than 3 years of age, in whom radiation therapy needs to be delayed due to its deleterious effect on the developing CNS. Several different regimens have been tried, including baby Paediatric Oncology Group protocols, 8 drugs in 1 day, single-agent cyclophosphamide, and single-agent ifosfamide (4). However, the responses to these regimens are still not convincing, and some tumours have even been reported to progress during treatment. In addition, recurrent or

progressive ATRT appears to be chemoresistant in children younger than 3 years of age (4). The largest published series to date by the North American Atypical Teratoid/Rhabdoid Tumor Registry found long-term remission only in approximately 55% of patients with intensified chemotherapy (4). Gardner reported long-term survival with multi-drug chemotherapy, including high-dose methotrexate and myeloablative chemotherapy, after surgery in only 3 out of 7 patients. The disadvantages and side effects of chemotherapy include haematopoietic toxicity, sepsis, hepatic toxicity, and hearing loss (13).

As mentioned earlier, radiation therapy is usually delayed until the child reaches 3 years of age in order to avoid neurocognitive impairment. Tekautz et al. (7) reported improved survival for children older than 3 who received combined radiation and chemotherapy. Chen et al. (5) and Tekautz et al. (7) also found that radiotherapy should be initiated in children older than 3 years of age soon after surgery and before chemotherapy. Bouvier et al. (2) reported a case of a 7-year-old with an ATRT in the left frontal lobe who had a 7-year event-free survival following treatment with gross total resection and external cranial radiotherapy. As children with ATRT may have leptomeningeal spread at diagnosis or recurrence (10), it may be desirable to administer craniospinal radiotherapy in addition to treatment of the primary tumour. In our case, spinal MRI needed to be performed first before proceeding to radiotherapy. Because the patient was an older child, she should have more favourable results from treatment compared with in children younger than 3 years of age.

This is an uncommon case of ATRT with typical histological features but presenting in an older child in the supratentorial compartment. This tumour is highly malignant and the optimal treatment is still unclear. Although older children with ATRT tend to have better outcomes than that of their younger counterparts', it has unfortunately carried fatal prognosis in this patient.

Authors' Contributions

Conception and design, collection, assembly, analysis, interpretation of the data, drafting and final approval of the article, administrative, technical, and logistic support: KHC
Provision of patient: FK
Critical revision of the article: YCT
Administrative, technical, or logistic support: KHC, MSMH

Correspondence

Dr Kin Hup Chan
MBBS (Malaya), MMed Neurosurgery (USM)
Department of Surgery
Kulliyah of Medicine
International Islamic University Malaysia
Jalan Istana Bandar Indera Mahkota
25200 Kuantan
Pahang, Malaysia
Tel: +609-571 6770
Email: khchan@hotmail.com

References

1. Rorke LB, Packer RJ, Biegel JA. Central nervous system atypical teratoid/rhabdoid tumors of infancy and childhood: Definition of an entity. *J Neurosurg.* 1996;**85**(1):56–65.
2. Bouvier C, De Paula AM, Fernandez C, Quilichini B, Scarvada D, Gentet JC, et al. Atypical teratoid/rhabdoid tumour: 7-year event-free survival with gross total resection and radiotherapy in a 7-year-old boy. *Childs Nerv Syst.* 2008;**24**(1):143–147.
3. Lee IH, Yoo SY, Kim JH, Eo H, Kim OH, Kim IO, et al. Atypical teratoid/rhabdoid tumors of the central nervous system: Imaging and clinical findings in 16 children. *Clin Radiol.* 2009;**64**(3):256–264.
4. Hilden JM, Meerbaum S, Burger P, Finlay J, Janss A, Scheithauer BW, et al. Central nervous system atypical teratoid/rhabdoid tumor: Results of therapy in children enrolled in a registry. *J Clin Oncol.* 2004;**22**(14):2877–2884.
5. Chen YW, Wong TT, Ho DM, Huang PI, Chang KP, Shiau CY, et al. Impact of radiotherapy for pediatric CNS atypical teratoid/rhabdoid tumor (single institute experience). *Int J Radiation Oncol Biol Phys.* 2006;**64**(4):1038–1043.
6. Parwani AV, Stelow EB, Pambuccian SE, Burger PC, Ali SZ. Atypical teratoid/rhabdoid tumor of the brain: Cytopathologic characteristics and differential diagnosis. *Cancer.* 2005;**105**(2):65–70.
7. Tekautz TM, Fuller CE, Blaney S, Fouladi M, Broniscer A, Merchant TE, et al. Atypical teratoid/rhabdoid tumors (ATRT): Improved survival in children 3 years of age and older with radiation therapy and high-dose alkylator-based chemotherapy. *J Clin Oncol.* 2005;**23**(7):1491–1499.
8. Lee YK, Choi CG, Lee JH. Atypical teratoid/rhabdoid tumor of the cerebellum: Report of two infantile cases. *ANJR Am J Neuroradiol.* 2004;**25**(3):481–483.
9. Hilden JM, Watterson J, Longee DC, Moertel CL, Dunn ME, Kurtzberg J, et al. Central nervous system atypical teratoid/rhabdoid tumor: Response to intensive therapy and review of literature. *J Neurooncol.* 1998;**40**(3):265–275.
10. Tinsa F, Jallouli M, Douira W, Boubaker A, Kchir N, Hassine DB, et al. Atypical teratoid/rhabdoid tumor of the spine in a 4-year-old girl. *J Child Neurol.* 2008;**23**(12):1439–1444.
11. Reedy AT. Atypical teratoid/rhabdoid tumors of the central nervous system. *J Neurooncol.* 2005;**75**(3):309–313.
12. Bansal KK, Goel D. Atypical teratoid/rhabdoid tumors of central nervous system. *J Paediatr Neurosci.* 2007;**2**(1):1–6.
13. Gardner SL, Asgharzadeh S, Green A, Horn B, McCowage G, Finaly J. Intensive induction chemotherapy followed by high dose chemotherapy with autologous hematopoietic progenitor cell rescue in young children newly diagnosed with central nervous system atypical teratoid rhabdoid tumors. *Pediatr Blood Cancer.* 2008;**51**(2):235–240.