

PAEDIATRIC OCULAR TRAUMA IN KUCHING, SARAWAK, MALAYSIA

AK Tan¹, PS Mallika¹, T Asokumaran², S Mohamad Aziz², G Intan²

¹Department of Ophthalmology, Faculty of Medicine and Health Sciences, Universiti Malaysia Sarawak (UNIMAS), Malaysia. (Tan Aik Kah, Mallika Premseenthil)

²Department of Ophthalmology, Hospital Umum Sarawak, Kuching, Malaysia. (Asokumaran Thanaraj, Mohamad Aziz Salowi, Intan ak Gudom)

Address of correspondence: Dr Tan Aik Kah, Trainee Lecturer, Ophthalmology Unit, Faculty of Medicine and Health Sciences, Universiti Malaysia Sarawak, Lot 77, Sekysen 22 Kuching Town Land District, Jalan Tun Ahmad Zaidi Aduce, 93150 Kuching, Sarawak, Malaysia. Tel: +6082-416 550, Fax: + 6082-422 564, Email: portwinestain@hotmail.com, aktan@fmhs.unimas.my

Funding and conflict of interest: None.

ABSTRACT

Purpose: To evaluate the demography, aetiology, type and outcome of paediatric ocular trauma in tertiary centre in Malaysia.

Method: We retrospectively studied 118 eyes from 117 patients over a period of 36 months (January 2006 to December 2008). All ocular injuries in patients aged 12 and below seen in the Ophthalmology Department for the first time were included in this study.

Results: Mean age of patients was 6.1±3.0 years. 68 cases (58.2%) occurred in pre-school children, whereas 49 (41.9%) in school-aged children. Boys accounted for 65.8% of cases. There was no predilection for either right or the left eye. 47% of cases (56 patients) occurred in Malay. Most of the injuries took place at home when the children were alone ($p<0.05$). Sharp objects were the commonest cause (45 cases, 38.1%). The majority of cases (103, 87.3%) were considered preventable. The frequency of open and closed globe injury was similar. Hyphema was more common in closed globe injury compared to open globe injury ($p<0.05$). Other associated injuries such as cataract, vitreous hemorrhage and retinal hemorrhage are similar between the two groups. Visual outcome is generally poor with only 34 eyes (28.8%) had no visual impairment.

Conclusion: Ocular trauma in children is an important cause of visual loss. Most cases occurred at home and were preventable. Prevention through education is the best approach.

Tan AK, Mallika PS, Asokumaran T, Mohamad Aziz S, Intan G. Paediatric ocular trauma in Kuching, Sarawak, Malaysia. *Malaysian Family Physician*. 2011;6(2&3):68-71

INTRODUCTION

Sight is considered to be the most important of the five human senses; vision is a critical aspect of many occupations. Ocular trauma is therefore an important public health issue as it is the major cause of acquired unocular blindness among children.¹⁻³ The Prevention of Blindness America stated that about 90% of all eye injuries and 50% cases of blindness are preventable.⁴ Harrison and Telander pointed that children are pre-disposed to eye injury because of their developing coordination, daring manner of play, as well as lack of anatomical protection from the eyebrow, cheekbone and the nose.⁵ Additional factors include limited common sense, lack of emotional control, relative ignorance, imitation of behaviour and natural curiosity.^{3,6} Visual lost in the paediatric age group can be a direct consequence of the trauma or secondary to amblyopia. This in turn impairs their psychosocial development.

The characteristics of children at risk, the agents of injury, and the environmental determinants of ocular trauma vary in different

countries. One common factor was that most injuries involved boys.¹⁻³ Local data is important to create awareness of the magnitude of the problem and for the planning of preventive strategies, especially in a multiracial country like Malaysia. So far, there is not much data on paediatric ocular trauma in Malaysia. Mallika presented the causes and visual outcome of childhood eye injuries seen in Malaysian primary eye care setting.⁷ The aim of this study was to determine the demography, aetiology, type and outcome of paediatric ocular trauma in tertiary centre in Malaysia. These data are valuable in the provision of specific recommendations for primary prevention measures.

METHOD

This was a retrospective study where medical records over a period of 36 months (January 2006 to December 2008), at the Ophthalmology Department of Sarawak General Hospital, Kuching, Malaysia were examined. All ocular injuries in patients aged 12 and below seen in the Ophthalmology Department for

the first time were included in this study. Children with repeated eye trauma were also included. Patients treated elsewhere and patients on follow-up were excluded from the study. Patients with severe form of ocular trauma were hospitalised and others treated as outpatients. The demographic details included name, age, gender, and ethnicity. The details about injury included the date of injury, eye affected, place, intent, source and type of injury. The different ethnic groups were divided into Iban, Bidayuh, Malay, Chinese and others. Place of occurrence of the injury were classified as follows: home, school, place of recreational or sports and streets or highway. Circumstances where the injury occurred were divided into whether the injury occurred when the child was alone or when playing with their peers. The aetiology of injury was divided into sharp objects, blunt objects, fall, nail or others. The type of ocular injury was classified according to the Birmingham Eye Trauma Terminology (BETT) system.⁸

Visual acuity was measured with Snellen chart or E-chart at six meter for school-aged children. For pre-school children, Sheridan Gardiner test was used. Visual acuity was categorised as follows: 6/6 to 6/9, 6/12 to 6/36, 6/60 to CFCF (counting finger close to the face), HM (hand movement), and PL (perception of light), NPL (no perception of light) and NA (not available due to poor patient cooperation).

RESULTS

A total of 117 children were included, age ranged from one to 12 years (mean age 6.1 ± 3.0 years). None of the children had repeated eye trauma. Boys accounted for the majority of cases 65.8% (77:40, 95% CI: 56.5% to 74.3%, $p < 0.001$). Figure 1 showed the distribution of age and gender.

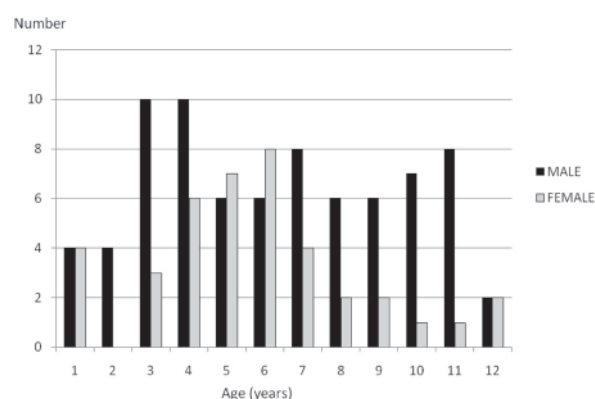


Figure 1: Distribution of ocular trauma by age and gender of 117 children in Kuching, Malaysia in 2006-2008

68 cases (58.2%) occurred in pre-school children (0 to 6-year-old age group), whereas 49 (41.9%) in school children (7 to 12-year-old age group). This difference was not statistically significant

($p = 0.195$). The male-female ratio was 3.1:1 in the school-aged children compared to 1.4:1 in pre-school children.

One patient had trauma to both eyes. 64 patients (54.7%) had right eye involvement (95% CI: 45.2% to 63.9%, $p = 0.307$). The majority of paediatric ocular trauma occurred in Malay (55 patients, 47.0%), followed by Iban (25 patients, 21.4%), Chinese (19 patients, 16.2%), Bidayuh (17 patients, 14.5%) and other races (1 patient, 0.9%). Most of the injuries took place at home (88 patients, 75.2%), 10 (8.5%) at school, 16 (13.7%) at streets and 3 (2.6%) at recreational places. 95 cases (81.2%) of injuries occurred when the children were alone, 22 (18.8%) during play with other children ($p < 0.05$).

Sharp objects were responsible for 45 cases (38.1%), blunt objects 31 (26.3%) and fall 15 (12.7%). The male-female ratio was 2:1 in injuries due to sharp objects (Table 1). Accidental fall was responsible for 15 (12.7%) cases. The majority of cases (103, 87.3%) was caused by objects and was considered preventable.

Table 1: Causes of injury by gender

Causes of injury	Number (%) of children		
	Male	Female	Total
Sharp	30 (38.5)	15 (37.5)	45 (38.1)
Blunt object	19 (24.4)	12 (30.0)	31 (26.3)
Fall	7 (9.0)	8 (20.0)	15 (12.7)
Nail	1 (1.3)	0 (0.0)	1 (0.8)
Unknown objects	21 (26.9)	5 (12.5)	26 (22.0)
Total	78 (100.0)	40 (100.0)	118 (100.0)

Open globe injury accounted for 60 of eyes (50.8%) while closed globe injury 58 cases (49.2%). The difference was not statistically significant ($p = 0.927$). Figure 2 showed the type of ocular trauma by patients' age.

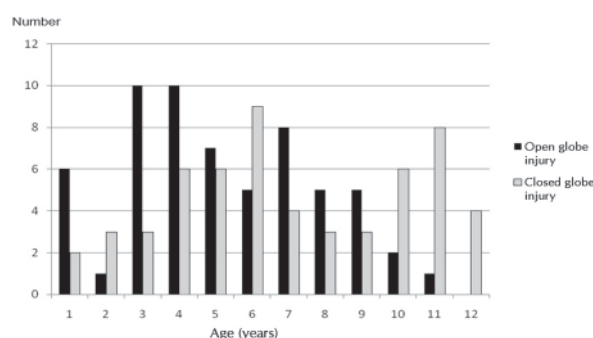


Figure 2: Distribution of ocular trauma by age and types of injury of 117 children in Kuching, Malaysia in 2006-2008

Of the 60 eyes with open globe injury, 7 (11.7%) had injury confined to the anterior segment only while the remainder 53 (88.3%) involved the posterior segment as well. Corneoscleral laceration occurred in 7 patients (11.7%). In closed globe injury, 23 (39.7%) had corneal oedema, 12 (20.7%) corneal abrasion and 6 (10.3%) lamellar corneal laceration. Cornea was normal in 17 (29.3%) patients. One patient had corneal foreign body.

Hyphema was more common in closed globe injury compared to open globe injury (64%, 95% CI: 49.2% to 77.1%, $p < 0.05$). The development of cataract, vitreous haemorrhage and retinal haemorrhages was not statistically different between the two groups (Table 2). One patient with closed globe injury had lens subluxation while three patients with open globe injury had endophthalmitis.

Table 2: Conditions associated with open globe and closed globe injuries

Associated injuries	Type of globe injury		p value
	Open globe injury, n=60 n (%)	Closed globe injury, n=58 n (%)	
Hyphema	18 (27.69)	32 (61.54)	<0.05
Cataract	7 (10.77)	10 (19.23)	>0.05
Vitreous haemorrhage	6 (9.23)	4 (7.70)	>0.05
Retinal haemorrhage	3 (4.62)	1 (1.90)	>0.05

Admission was required for all patients with open globe injury (n=60) and closed-globe injury with hyphema (n=32). The remainder 25 patients (21.4%) were treated as outpatient.

Final visual acuity was classified as no visual impairment (6/6 to 6/9; level 0 visual impairment), mild to moderate visual impairment (6/12 to 6/36; level 1 visual impairment), severe visual impairment (6/60 to light perception; level 2 visual impairment) and no light perception (level 3 visual impairment). At six months of follow up, those who cannot cooperate for visual acuity assessment (n=17) were excluded from analysis (Table 3).

Table 3: Visual outcome associated with open globe and closed globe injuries

Visual outcome	Type of global injury	
	Open globe injury, n (%)	Closed globe injury, n (%)
Level of visual impairment		
0	21 (35.0)	13 (22.4)
1	4 (6.7)	19 (32.8)
2	22 (36.7)	19 (32.8)
3	3 (5.0)	0 (0.0)
NA	10 (16.7)	7 (12.1)
Total	60 (100.0)	58 (100.0)

In the closed globe injury subgroup, 13 (22.4%) had no visual impairment, 19 (32.8%) had level 1 visual impairment, 19 (32.8%) level 2 and none had level 3 visual impairment. In patients with open globe injury, 21 (35.0%) had no visual impairment, 4 (6.7%) level 1, 22 (36.7%) level 2 and 3 (5.0%) had level 3 visual impairment ($p < 0.01$). All three patients with endophthalmitis were treated with intravitreal antibiotics, unfortunately all had no light perception.

DISCUSSION

In the year 2006, there were 233 reported cases of ocular trauma in Kuching; of which 14.1% (33 cases) are due to paediatric ocular trauma.⁹ Boys are pre-disposed to ocular trauma due to involvement in activities with higher risk of injury. The ratio of boys to girls of 1.9:1 in our population is consistent with other studies.^{3,6,10} This is due to competitive and aggressive nature of play among boys.⁶ The findings of this hospital-based study are similar to those of a primary eye care setting, where the majority of cases occurred at home.⁷

The final visual outcomes in our study were poor as only 34 eyes (28.8%) had no visual impairment. Amblyopia is one of the three commonest causes of eye problems seen in children.⁴ Permanent visual impairment, even in mild degree is amblyogenic. Hence every effort should be taken to prevent ocular trauma in this age group. As most of the injuries occurred during unsupervised play at home, it is important to educate parents on parental supervision. The provision of safe environment at home is crucial.¹⁰ Sharp objects and other dangerous household objects should be kept out of reach. The Prevention of Blindness America published a list of the most dangerous toys to children's eyes.¹¹ Parents should be cautioned before buying such toys for their children.

Mallika found that social, economic and educational factors determined the urgency of patients presented to the clinic or to the hospital. Delay in seeking immediate primary eye care or specialist treatment also led to poor visual outcome. Malaysian parents were also generally not keen to have their children admitted to the hospital, regardless of the type and degree of severity of injuries.⁷ Primary physicians, due to the good rapport and trust by the community, are often in the front-line of medical emergencies. They are in the best position to advice parents on the provision of safe environment at home. Emergency care and management of patients with ocular trauma are also mostly handled by family physicians. Early and effective first-aid care provided by family physicians is crucial in the prevention of future complications.¹²

Firework injuries are relatively common in the East Coast of Peninsular Malaysia but not common in Sarawak. Rashid *et al.* reported 30 cases of fireworks related ocular injury in a single

Aidilfitri celebration,¹³ but there were none reported during our study period and only four cases reported in Kuala Kangsar (West Coast of Peninsular Malaysia) over the period of nine years.⁷ This strongly suggests that the difference in socio-economic structure, cultural background and stricter law enforcement by the local authority are important modifiable factors in the prevention of ocular injuries.

The main limitation of this study is its retrospective nature, where data were not completed in a standardised manner. This hospital-based study also suffered from under reporting of ocular trauma. We believed that many ocular injuries with no or minor visual consequences were not referred to our hospital. These cases were treated in private medical centres or primary health care centres. Ocular trauma may escape unnoticed by the parents because visual changes in the affected eye were masked by reliance on the better-seeing eye. Furthermore, children are poor historian, and many are unable to identify their injury. As such, we were not able to calculate the local incidence rate of paediatric ocular trauma.

CONCLUSION

Ocular trauma in children is an important cause of visual loss. Most cases occurred at home and were preventable. Prevention through education is the best approach.

ACKNOWLEDGEMENT

The authors would like to thank the staff of the Ophthalmology Department, Hospital Umum Sarawak, for the assistance provided during the study.

REFERENCES

1. Strahlman E, Elman M, Daub E, *et al.* Causes of pediatric eye injuries. A population-based study. *Arch Ophthalmol.* 1990; 108(4):603-6.
2. Jandack C, Kellner U, Bornfeld N, *et al.* Open globe injuries in children. *Graefes Arch Clin Exp Ophthalmol.* 2000;238(5):420-6.
3. Serrano JC, Chalela P, Arias JD. Epidemiology of childhood ocular trauma in a northeastern Colombian region. *Arch Ophthalmol.* 2003;121(10):1439-45.
4. StarPupils.org. Quick Facts: Children 's Eye Problems. [Online]
5. Harrison A, Telander DG. Eye injuries in the young athlete: a case-based approach. *Pediatr Ann.* 2002;31(1):33-40.
6. Lee CH, Su WY, Lee L, *et al.* Pediatric ocular trauma in Taiwan. *Chang Gung Med J.* 2008;31(1):59-65.
7. Mallika MB. Causes and visual outcome of childhood eye injuries seen in a Malaysian primary eye care clinic. 3rd World Conference on Rural Health; 1-4 July 1999; Kuching, Sarawak, Malaysia.
8. Kuhn F, Morris R, Witherspoon CD. Birmingham Eye Trauma Terminology (BETT): terminology and classification of mechanical eye injuries. *Ophthalmol Clin North Am.* 2002;15(2):139-43.
9. Mallika PS, Tan AK, Asok T, *et al.* Pattern of ocular trauma in Kuching, Malaysia. *Malaysian Family Physician.* 2008;3(3):140-5.
10. Thompson CG, Kumar N, Billson FA, *et al.* The aetiology of perforating ocular injuries in children. *Br J Ophthalmol.* 2002;86(8):920-2.
11. StarPupils.org. Most Dangerous Toys to Children's Eyes. [Online]
12. Nichols BD. Ocular trauma: emergency care and management. *Can Fam Physician.* 1986;32:1466-71.
13. Rashid RA, Heidary F, Hussein A, *et al.* Ocular burns and related injuries due to fireworks during the Aidil Fitri celebration on the East Coast of the Peninsular Malaysia. *Burns.* 2011;37(1):170-3.