

Case Report

Sub-Brachialis Course of the Median Nerve in the Arm and its Possible Clinical Complications: A Case Report

Melanie RD¹, Anitha G², Naveen K² (✉), Satheesha BN²

¹Department of Anatomy, KMC International Center, Manipal University, Manipal 576104, Karnataka, India.

²Department of Anatomy, Melaka Manipal Medical College (Manipal Campus), Manipal University, Manipal 576104, Karnataka, India.

Abstract

The median nerve in its normal course in the arm crosses the brachial artery from lateral to medial side. It then passes superficial to the brachialis muscle and then enters the cubital fossa. During routine cadaveric dissection of the right upper limb, an unusual variation in the course of the median nerve was observed. The median nerve in the arm crossed the brachial artery from medial to lateral side and passed deep to the brachialis muscle. It then emerged from beneath the brachialis muscle and entered the cubital fossa. In the cubital fossa, it ran medial to the brachial artery as the normal course of the nerve. Further distribution of median nerve in the forearm and hand was observed to be normal. The anomaly reported here may result in the compression of the median nerve deep to the brachialis and hence resulting in mechanical disadvantages in the flexion at the wrist joint.

Keywords: Median nerve, sub brachialis course, median nerve entrapment, compression of median nerve

Correspondence:

Naveen Kumar, Department of Anatomy, Melaka Manipal Medical College (Manipal Campus), Manipal University, Manipal 576104, Karnataka, India. Tel: +91 9880548636 Email: naveentonse@gmail.com

Date of submission: 24 Aug, 2012

Date of acceptance: 25 Oct, 2012

Introduction

Disorders of the peripheral nervous system are common. Among these disorders, entrapment neuropathies, i.e. cases in which the nerve is compressed by adjacent anatomic structures, are frequently encountered by the clinician (1).

Classically, the median nerve receives fibers from C5, C6, C7, C8 and T1 spinal nerves, and supplies motor, sensory and sympathetic nerve fibers to the upper limb. The median nerve is normally formed by the union of two roots: lateral root of median nerve (LRM) derived from the lateral cord (C5, C6, C7) of brachial plexus and medial root of median nerve (MRM) derived from the medial cord (C8, T1) of brachial plexus. The two roots embrace the third part of the axillary artery, uniting anterior or lateral to it. In the

arm, the course of the median nerve is closely related to the brachial artery. It descends along the lateral side of the third part of axillary artery and proximal part of brachial artery. At the middle of the arm opposite the insertion of coracobrachialis the nerve crosses from lateral to medial, usually in front of the artery and then accompanies along the medial side of the brachial artery. It appears in the cubital fossa beneath the bicipital aponeurosis and rests on the brachialis. The nerve leaves the cubital fossa through a gap between the superficial and deep heads of pronator teres.

Case Report

During routine dissections for medical undergraduates, a few variations were found in the anterior compartment of the arm. The variations were found in the right limb and were unilateral. The median nerve (MN) trunk was

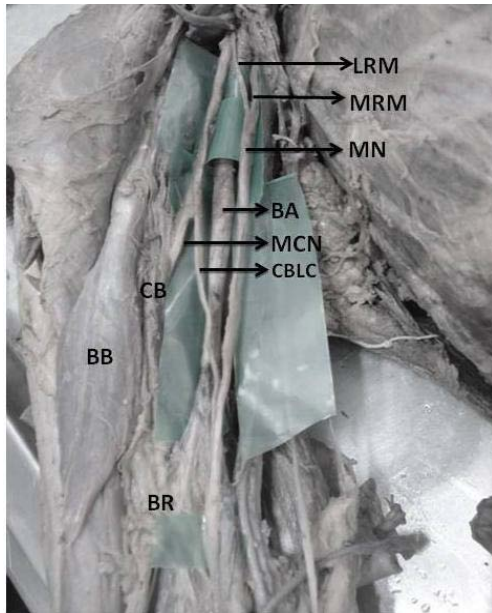


Figure 1: Dissection of front of the right arm: Formation of median nerve trunk (MN) from lateral root (LRM) and medial root (MRM) of median nerve and its relation with brachial artery (BA) is shown. CB: Coracobrachialis, BB: Biceps brachii, BR: Brachialis, MCN: Musculocutaneous nerve, CBLC: communicating branch from lateral cord of brachial plexus.

found medial to the third part of axillary artery formed by the union of the lateral root (arising from the lateral cord of the brachial plexus) and the medial root (arising from the medial cord of the brachial plexus), the former passing anterior to the artery. After its formation, median nerve trunk continued medial to the brachial artery.

At the level of the insertion of coracobrachialis muscle, MN crossed the brachial artery from medial to lateral side. The median nerve trunk then received a communicating branch from the lateral cord of brachial plexus, after the latter gave off the musculocutaneous nerve.

MN then passed deep to the brachialis. It then emerged out just before entering the cubital fossa. In the cubital fossa it was situated medial to the brachial artery as is the normal course of the nerve. Further course and distribution of median nerve in the forearm and hand was observed to be normal. These kinds of variations are vulnerable to damage in surgical operations of the axilla and upper arm.

Discussion

The distribution, course and the branching pattern of the nerves of brachial plexus is significant from the clinical perspective. A more defined knowledge than that found in classical anatomical texts is necessary for

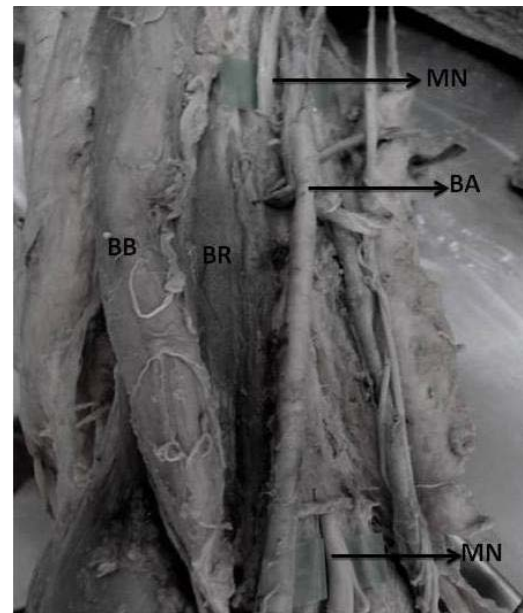


Figure 2: Dissection showing course of the median nerve in the front of the arm: Median nerve (MN) piercing the Brachialis muscle (BR) followed by its deep course and exit through the muscle is shown. BB: Biceps brachii, BA: Brachial artery.

clinical investigation and the surgical treatment of peripheral nerve injury (2).

In the present study, there was a change in relationship of LRM with axillary artery where the LRM has crossed the artery anteriorly from lateral to medial side to join the MRM to form the trunk of the median nerve. The median nerve was medial to the axillary artery, unlike the usual case of MRM crossing the artery from medial to lateral to form the median nerve lateral to axillary artery. This type of variation of formation of median nerve has also been mentioned in literature (3, 4).

Understanding the embryologic development of the brachial plexus is of importance in explaining such anatomic variations. The change in relationship between cords of brachial plexus and axillary artery might be due to a change in the source of the subclavian artery, from the usual 7th segmental artery which is between lateral and medial cords, to 6th or 8th segmental artery which may cause medial or lateral displacement of cords in relation to artery respectively (5).

Variations in the formation of median nerve were noted by some earlier workers. The variations related to the formation of median nerve by more than two roots which have been observed in the present study are rare, as revealed by survey of literature (4,6). These variations may be explained in the light of

embryonic development. The need of brachial plexus arises for ease of distribution of peripheral nerves as each nerve can receive contribution from several spinal segments and one spinal segment can be distributed to several peripheral nerves (7). Plexus is a complex of branching of nerve fibers that usually happens near the root of limbs, which is axilla for the upper limb. The complex network is sometimes extending into the arm & can be the cause for variations. Over the years various principles (8, 9) concerning with the variant formation of nerves have evolved which may explain the present formation of the median nerve in this case.

As observed in this case, the course of the median nerve was found to be deep to the brachialis muscle. There are well described entrapment syndromes involving median nerve or its branches, namely carpal tunnel syndrome, pronator teres syndrome and anterior interosseous syndrome (10, 11).

A few case reports were found in the literature, explaining the possible median nerve entrapment due to a third head of biceps brachii (12, 13) and ligament of Struthers (14). Bilecenoglu et al. (2005) (15) observed a variation of the median nerve at the level of the brachialis in which the nerve was separated from the brachial artery and passed through the cubital fossa piercing the muscle. This anatomic variation was considered as a possible cause for entrapment.

In the present study, the median nerve pierced the brachialis muscle at the distal half of the arm and emerged at the cubital fossa as its normal position, medial to the brachial artery. The further course of the MN was found to be normal. The anomaly reported here may result in the compression of the median nerve deep to the brachialis and hence resulting in mechanical disadvantages in the flexion at the wrist joint. Variant nerves, in terms of unusual beginning, course or distribution, are usually prone for injuries and entrapment neuropathies (15).

Conclusion

Knowledge of the variations related to the formation of median nerve by more than two roots is important particularly to the surgeons for carrying out surgical procedures in axilla and arm. Our observation of compression of median nerve by the brachialis muscle differed from the previous reports. Precise knowledge of such variations also helps Clinicians and Orthopaedicians in interpretation of unusual clinical findings, clinical neurophysiological tests and radiological images.

References

1. Kothari MJ. Hospital Physician. Neurology Board review. Manual Neurology 2001;6:1-15.
2. Linell EA. The distribution of nerves in the upper limb, with reference to variabilities and their clinical significance. J Anat 1921; 55(Pt 2-3):79-112.
3. Saeed M, Rufai AA. Median and musculocutaneous nerves: Variant formation and distribution. Clin Anat 2003; 16(5):453-457.
4. Satyanarayana N, Vishwakarma N, Kumar GP, Guha R, Dattal K, Sunitha P. Rare variations in the formation of median nerve-embryological basis and clinical significance. Nepal Med Coll J 2009; 11(4): 287-290.
5. Hollinshead WH. Anatomy for Surgeons. 3rd Ed. Philadelphia: Harper and Row, 1982, pp-259-340.
6. Bharat RS. An unusual case of asymmetrical formation and distribution of median nerve International Journal of Anatomical Variations 2011; 4: 57-60.
7. Sinnatamby CS. Last's Anatomy. Regional and Applied. 11th Ed. New York: Churchill Livingstone Elsevier, 2006, pp-1-34.
8. Ramon Y, Cajal S. Accion neurotropica de los epitelios. Algunos detalles sobre el mecanismo genetico de las ramificaciones nerviosas intraepiteliales sensitivas ysensoriales. Trab Lab Invest Biol 1919; 17: 65-8.
9. Weiss P. Nerve patterns: the mechanics of nerve growth. Growth (suppl 5) 1941; 163-203.
10. Gessini L, Jandolo B, Pietrangeli A. Entrapment neuropathies of the median nerve at and above the elbow. Surg Neurol. 1983; 19: 112-116.
11. Laha RK, Lunsford D, Dujovny M. Lacertus fibrosus compression of the median nerve. J Neurosurg. 1978; 48(5): 838-841.
12. Paval J. A rare case of possible median nerve entrapment. Neuroanatomy 2006; 5:35-38.
13. Mas N, Pelin C, Zagyapan R, Bahar H. Unusual relation of the median nerve with the accessory head of the biceps brachii muscle: an original case report. Int J Morphol. 2006; 24: 561-564.

14. Stephen F. Gunther SF, DiPasquale D, Martin R. Struthers' Ligament and Associated Median Nerve Variations in a Cadaveric Specimen. *Yale J Biol Med* 1993; 66(3):203-208.
15. Bilecenoglu B, Uz A, Karalezli N. Possible anatomic structures causing entrapment neuropathies of the median nerve: an anatomic study. *Acta Orthop Belg* 2005; 71: 169–176.