

**Case Report**

## **Mucopyocele in the oral region: an unusual case**

Ajay Telang <sup>a\*</sup>, Lahari T. <sup>b</sup>, James P. Chacko <sup>c</sup>

<sup>a</sup> Department of Oral Pathology, <sup>b</sup> Department of Oral Medicine & Radiology, <sup>c</sup> Department of Oral & Maxillofacial Surgery, Penang International Dental College, Lvl 19- 21, NB Towers, 5050, Jalan Bagan Luar, 12000 Butterworth, Pulau Pinang, Malaysia.

\* Corresponding author: [ajaytelang@yahoo.com](mailto:ajaytelang@yahoo.com), [ajay@pidc.edu.my](mailto:ajay@pidc.edu.my)

Received: 24/02/2011. Accepted: 05/10/2011. Published online: 12/10/2011.

**Abstract** Mucopyoceles are rare lesions defined as infected mucoceles. They have been reported only in the paranasal sinuses and appendix. Our case is the first to be reported in the oral region. A 58-year-old male presented with complaint of a painless swelling of two years duration in the right buccal sulcus with associated pus discharge. Radiographic examination ruled out pulpal and periodontal foci of infection and histopathology confirmed an underlying mucopyocele in the right buccal mucosa.

**Keywords:** mouth, mucocoele, salivary gland.

### **Introduction**

Mucocele is defined as mucus filled cavity that can occur in the oral cavity, appendix, gallbladder, paranasal sinuses or lacrimal sac (Baurmash, 2003; Ozturk *et al.*, 2005). A mucocele that gets secondarily infected is termed as a mucopyocele and it has been reported to occur in the paranasal sinuses and appendix (Mustapha and Boucree, 2004; Pinto *et al.*, 2005; Shrivastava *et al.*, 2006; Kandoğan *et al.*, 2007). The incidence of mucoceles in the general population is 0.4 to 0.8% (Yagüe-García *et al.*, 2009) but the occurrence of mucopyoceles in the oral cavity has not been reported in English language scientific literature. We report a rare case of a mucopyocele in the oral cavity.

### **Case report**

A 58-year-old apparently healthy male presented to the oral medicine clinic of Penang International Dental College, Malaysia with the complaint of a

painless swelling in the right buccal sulcus for the previous two years. He reported that the swelling was recurrent, appearing in the same region each time and was associated with pus discharge. There was no history of toothache, fever or dysphagia associated with the onset of the swelling. The patient was an amateur boxer and in his anamnesis, he has reported a fish bone lodgment during mastication in the same region two years ago.

Examination revealed a diffuse swelling roughly 2cm x 1cm in size in the right mandibular buccal sulcus in relation to 45, 46 regions. The mucosa over the swelling appeared normal with pus oozing from a blind sinus tract upon palpation. A pulpal or periodontal focus of infection was ruled out by clinical and radiographic examination (Fig. 1). An intraoral radiograph with a gutta-percha stick inserted through the sinus tract ruled out a bony focus (Fig. 2). Regional lymphnodes were not palpable. A provisional diagnosis of a buccal abscess with differential diagnoses of

foreign body granuloma and orofacial granulomatosis was considered.

The patient underwent an excisional biopsy of the lesion under local anaesthesia which was approached by a mucosal incision in the lower vestibule, after careful dissection around the mental nerve the lesion was identified and excised. The completely excised lesion was submitted for histopathological examination. Primary mucosal closure and haemostasis was achieved, the patient tolerated the procedure well and was discharged immediately.

Microscopically, multiple sections showed stratified squamous non keratinised and parakeratinised epithelium with underlying connective tissue which was fibro-collagenous with a large cystic space, mucin pooling and pus within the lumen (Fig. 3). Cyst wall was lined by tall columnar to cuboidal ductal cells. Also noted were severe periductal inflammation, acinar degeneration, numerous dilated ducts and chronic inflammatory cell infiltration (Fig. 4). The histopathological findings suggested a mucopyocele of the buccal mucosa.

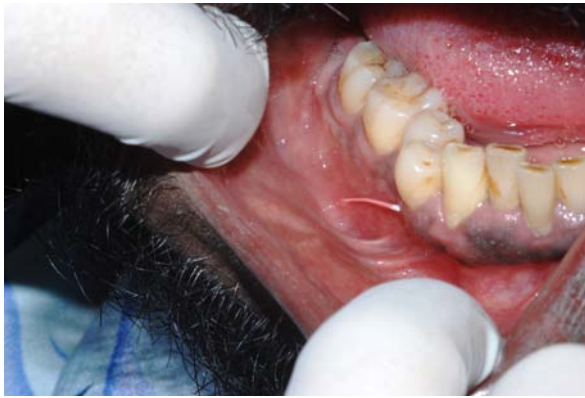## Discussion

Mucocele of the oral cavity is a clinical term which is classified as extravasation or retention types based on histopathology. The extravasation type consists of extravasated mucus in the connective tissue and the retention mucocele results from mucus retained in an epithelial-lined cavity, usually a dilated duct of minor salivary glands (Harrison, 1975). The more common extravasation type, usually results from local trauma such as biting and is found commonly in the lower lip and in younger age groups while retention mucocele occurs in the older age group as a result of dilatation of the duct due to blockage by a sialolith or a mucus plug and is usually found in the palate and floor of mouth. The extravasated saliva elicits inflammatory reaction and results in formation of granulation tissue whereas the retention variety is enclosed in the dilated minor salivary gland duct and may be confused

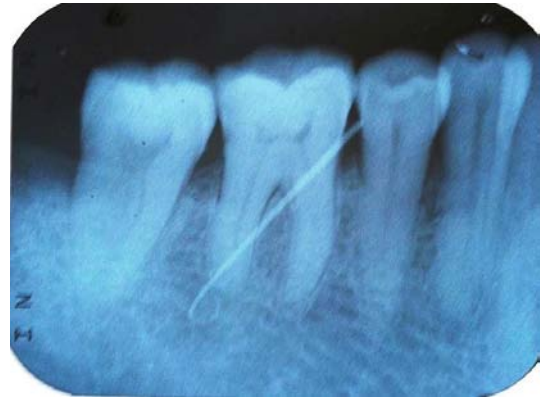with true cysts (Greenberg, 1997). Mucopyocele is a term used to describe a mucocele that gets secondarily infected by pyogenic bacteria and develops pus (Pappas *et al.*, 1993). It is a relatively rare condition reported mainly in the frontal sinus followed by ethmoidal, maxillary and sphenoidal sinuses among other rare locations in the human body (Shrivastava *et al.*, 2006). A microbiological study of 36 mucopyoceles (21 from the maxillary sinus, 8 from frontal sinus, 4 from ethmoid sinus and 3 from sphenoid sinus) showed a polymicrobial aerobic and anaerobic bacteriology composed of predominant aerobic isolates of *Staphylococcus aureus* (6 isolates), alpha-hemolytic streptococci (6 isolates), *Hemophilus* spp. (5 isolates), and Gram-negative bacilli (6 isolates) (Brook and Frazier, 2001). The predominant anaerobes were *Peptostreptococcus* sp. (22), *Prevotella* sp. (15), *Fusobacterium* sp. (5), and *Propionibacterium acnes* (5) (Brook and Frazier, 2001).

Our case had a clinical history suggestive of trauma with recurrent swelling and intraoral pus discharge which lead to a clinical diagnosis of buccal abscess and differential diagnosis of foreign body granuloma and orofacial granulomatosis. Foreign body granuloma was considered because of a history of fish bone lodgement. The possibility of orofacial granulomatosis was thought of as the less likely diagnosis due to the absence of other systemic findings and limitation of the lesion to only one side buccal sulcus.

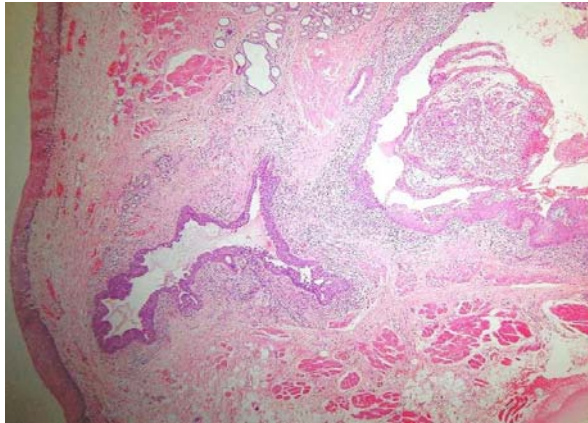
Microscopically in our case, superficial sections showed a central area of localized collection of mononuclear cells, small amounts of mucus pooling, dilated ducts, periductal inflammation and acinar degeneration with no evidence of a foreign body granuloma. This made us think in terms of possible salivary gland pathology. Deeper sections clearly revealed a large dilated duct lined by cuboidal to columnar epithelium with large amounts of mucus pooling which was densely infiltrated by acute and chronic inflammatory cells



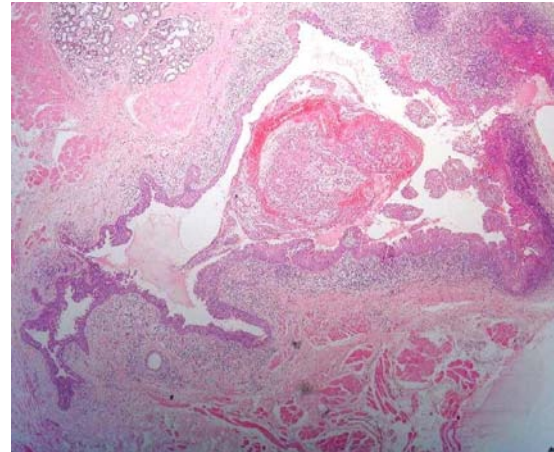
**Figure 1** Clinical picture showing intraoral swelling with gutta-percha stick inserted into the sinus tract.



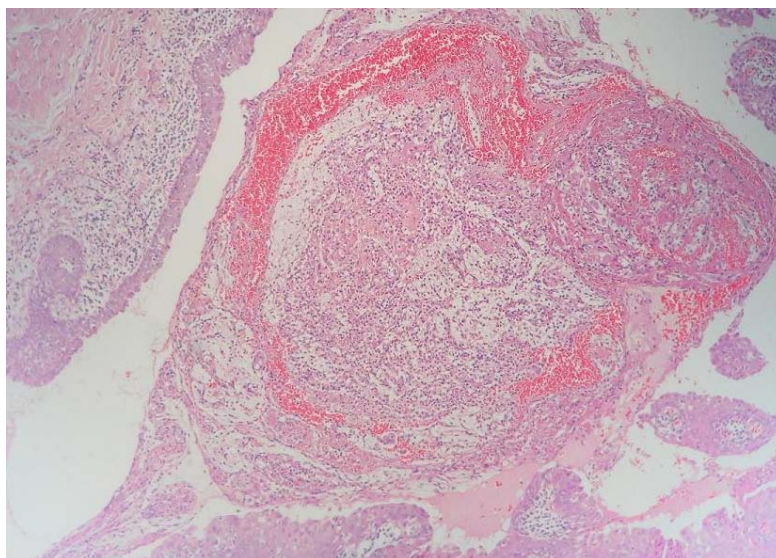
**Figure 2** Intraoral periapical radiograph with gutta-percha stick ruling out a periapical or bone pathology.



**Figure 3** Superficial section showing overlying buccal mucosa, dilated duct with mucus pooling, pus, periductal inflammation and acinar degeneration (haematoxylin-eosin, original magnification 4X).



**Figure 4** Large dilated duct with mucus plugging, pus, periductal inflammation & acinar degeneration (haematoxylin-eosin, original magnification 4X).



**Figure 5** Mucus pooling with pus in the dilated duct (haematoxylin-eosin, original magnification 10X).



and pus (Fig. 5). These findings suggested a secondarily infected retention type mucocoele. This confirmed our suspicion of salivary gland pathology with compatible microscopic findings of a mucopyocele.

The most frequent microscopic findings in mucocoeles are the presence of a predominantly mono-nuclear inflammatory process in the sub-epithelial connective tissue, made up mainly by mature lymphocytes and plasma cells. Histopathology of oral mucocoeles described in standard literature does not mention secondary infection of the mucus and pus formation.

A search in the English language scientific literature for similar cases from the oral region was carried out, but the result was scanty.

The suggested pathogenesis in this case is that of trauma caused due to the patients boxing hobby which probably lead to mucus plugging in the ductal orifice leading to the formation of a mucocoele in the right buccal region. Repeated trauma which is common in the sport of boxing may have introduced the flora from the oral cavity into the developing mucocoele which lead to the secondary infection of the mucocoele and subsequent sinus formation. Due to chronic drainage of pus from the mucopyocele the clinical presentation was compatible with that of a chronic painless recurrent swelling.

## Conclusion

Mucopyocele of the oral cavity can be caused by repeated trauma in the oral region. Our case presented with a chronic course and an unusual site which was misleading in the early stage of diagnosis. As far as we are aware, our report is the first documented case

that described a mucopyocele in the oral cavity.

## Acknowledgments

Authors would like to acknowledge the assistance given by Dr. Sathy Ramakrishnan, Consultant Pathologist & Director, Phoenix Pathology Lab Sdn. Bhd., Pulau Pinang, Malaysia.

## References

- Baurmash HD (2003). Mucocoeles and ranulas. *J Oral Maxillofac Surg*, **61**(3): 369-378.
- Brook I, Frazier EH (2001). The microbiology of mucopyocele. *Laryngoscope*, **111**(10): 1771-1773.
- Greenberg MS (1997). Salivary gland disease. In: Lynch MA (ed.), *Burket's Oral Medicine: Diagnosis and Treatment*. Lippincott-Raven: Philadelphia, PA, pp. 415-418.
- Harrison JD (1975). Salivary mucocoeles. *Oral Surg Oral Med Oral Pathol*, **39**(2): 268-278.
- Kandoğan T, Özür MZ, Sezgin O (2007). Mucopyocele of the maxillary sinus: a case report. *Kulak Burun Bogaz Ihtis Derg*, **17**(4): 235-236.
- Mustapha IZ, Boucree SA Jr (2004). Mucocoele of the upper lip: case report of an uncommon presentation and its differential diagnosis. *J Can Dent Assoc*, **70**(5): 318-321.
- Ozturk K, Yaman H, Arbag H, Koroglu D, Toy H (2005). Submandibular gland mucocoele: report of two cases. *Oral Surg Oral Med Oral Pathol Oral Radiol Endod*, **100**(6): 732-735.
- Pappas CTE, Dickman CA, Herman JM, White WL, Baldree M (1993). Bipolaris sphenoid mucopyocele: three cases and literature review. *BNI Quarterly*, **9**(2): 68-72.
- Pinto JA, Cintra PPVC, de Marqui ACS, Perfeito DJP, Ferreira RDP, da Silva RH (2005). Middle turbinate mucopyocele: a case report. *Rev Bras Otorrinolaringol*, **71**(3): 378-381.
- Shrivastava U, Mundra RK, Varma P, Bhaisare V, Sodani P, Padheiriya M, Pawar N (2006). A case of sphenoidal mucopyocele with bilateral loss of vision. *AIOC Proceedings*, 416-417.
- Yagüe-García J, España-Tost AJ, Berini-Aytés L, Gay-Escoda C (2009). Treatment of oral mucocoele-scalpel versus CO<sub>2</sub> laser. *Med Oral Patol Oral Cir Bucal*, **14**(9): e469-e474.