

## Cases of hydatidosis in patients referred to Governmental hospitals for cyst removal in Sana'a City, Republic of Yemen

Latifa A.N. Al-Shibani<sup>1</sup>, Samira M.A. Al-Eryani<sup>1</sup>, Ahmed A. Azazy<sup>1</sup> and Abdulsalam M. Al-Mekhlafi<sup>\*1,2</sup>

<sup>1</sup>Department of Parasitology, Faculty of Medicine and Health Sciences, Sana'a University, Sana'a – Yemen

<sup>2</sup>Department of Parasitology, Faculty of Medicine, University of Malaya, 50603 Kuala Lumpur, Malaysia

\*Corresponding author email: halkasemi@yahoo.com

Received 4 July 2011; received in revised form 2 September 2011; accepted 5 September 2011

**Abstract.** Hydatidosis is a parasitic infestation caused by *Echinococcus granulosus*. This disease is endemic in many countries including Yemen. The present review article aims to have a glimpse at the present status of hydatidosis in Yemen. This is the first descriptive study, investigating recorded cases of hydatidosis from the five main governmental hospitals in the capital Sana'a city, over a longer period starting from 2001 and ending in 2008. A total of 796 medical records of patients referred to the five main governmental hospitals in Sana'a city for cyst removal, were studied. Of these cases 482 were females and 314 were males. Their mean age was  $30.0 \pm 16.9$  years. Information regarding the location of the cyst in the body, age, sex and residence of each patient was recorded. A higher infection rate was found in females than males (60.6% and 39.4%, respectively). Single organ involvement was observed in 98.6% cases, among which, the most frequent localizations were the liver (60.8%) followed by the lung (24.7%). Cases of hydatidosis appeared to increase during the period 2001-2008, with the lowest number (n=26) and the highest number (n=140) recorded in 2001 and 2007, respectively. We conclude that the risk of hydatidosis is still high in Yemen, where street or stray dogs move freely down town and the population should be aware about the role of dogs in the transmission of this disease. Hospital records provide a useful indication of infection expressed as annual rate of hospital cases. Finally, the collaboration of Public Health Authorities, the Veterinary Medical Authorities and the Environmental Affairs Authorities is a must to control this disease.

### INTRODUCTION

Human hydatid disease or hydatidosis is an important zoonotic disease caused by the larval stage of the dog tapeworm, *Echinococcus granulosus*. It has a worldwide distribution and is highly endemic in most of the Mediterranean region, North Africa, the Middle East, South America and Australia (Matossian *et al.*, 1977; McManus *et al.*, 2003). It has been reported as one of the major parasitic infections leading to many health problems (Eroglu *et al.*, 2002; Rostami *et al.*, 2007; El Malki *et al.*, 2010). The parasite is maintained mainly in sheep or cattle raising countries, where dogs, usually the primary definitive hosts, are closely associated with

these animals which act as intermediate hosts. Mode of transmission is through ingestion of the eggs of this parasite excreted in the faeces of the definitive hosts. Humans are accidental intermediate hosts, in which the life cycle ends blindly, preventing further transmission to other hosts. Yemen is one of the endemic countries in which this disease contributes a major health problem with high numbers of human cases being reported (Dhaifalah, 2001; Ghallap & Alsabahi, 2008; Alghoury *et al.*, 2010). This is the first descriptive study, investigating recorded cases of hydatid disease from the five main governmental hospitals in the capital Sana'a, over a longer period starting from 2001 and ending in 2008.

## MATERIALS AND METHODS

Cases were reviewed from the registry records of five public hospitals in Sana'a city (Al-Thawra, Al-Kuwait, Al-Gomhory, Al-Sabeen and Al-Askari hospital) for the period 2001-2008. Individuals from different parts of the province are referred to these hospitals for examination. None of the records were kept on computer except for the year 2008 in Al-Thawra hospital; therefore, the medical records were searched and reviewed manually for evidence of patients with hydatidosis. The location of the cyst in the body, age, sex and residence of each patient were recorded.

## RESULTS

A total of 796 individuals were operated on and confirmed positive for hydatid cysts at these five hospitals in Sana'a city during 2001 – 2008. Of these cases 482 were females and 314 were males, aged between <10 - > 60 years with a mean age of  $30.0 \pm 16.9$  years. The prevalence rate of hydatid cyst was highest among the age group of 20 - < 30 years (27.1%). In all age groups the prevalence rate was higher among females than males with an overall prevalence of 39.4% and 60.6% for both males and females, respectively. This difference was statistically significant ( $p < 0.05$ ) (Table 1). Analysis of data with chi-square revealed that infection rate of hydatid cyst in the liver of females was higher than that in males (68.4% and 31.6% respectively,  $P < 0.05$ ). In the lung, the infection rate was nearly similar in both sexes (Table 2). In all age groups, the infection rate of hydatid cyst was higher in the liver than other organs, except for the age group of less than 10 years where the infection rate was higher in the lung (49.3 %) than liver (40.3 %) (Table 3).

Single organ involvement was observed in 98.6% cases. The most frequent localization was the liver (60.8%) followed by the lung (24.7%). Other organs (kidney, spleen, and abdomen) represented 13.1%. In eleven patients (1.4%) the cyst was found in more than one organ (Table 2). Cases of hydatid cyst appeared to increase during the period

2001-2008, with the lowest number ( $n=26$ ) and the highest number ( $n=140$ ) recorded in 2001 and 2007, respectively (Figure 1).

## DISCUSSION

Hydatid disease is a parasitic infestation caused by *E. granulosus*. It is endemic in many countries and Yemen is one of the endemic regions (Ellaban *et al.*, 1994). There has been no recent published literature to show the trend of hydatidosis in Yemen. Hence, the present review article aims to have a glimpse at the present status of hydatidosis in Yemen.

In the present study, a total of 796 human hydatidosis were recorded from the five main governmental hospitals in Sana'a city. According to the results of this study, females were found to have a higher infection rate of

Table 1. Distribution of patients with hydatid cysts according to age and sex admitted to public hospitals in Sana'a city

Age (year)*	Male No. (%)	Female No. (%)	Total No. (%)
<10	33 (49.3)	34 (50.7)	67 (8.4)
10-	79 (47.0)	89 (53.0)	168 (21.1)
20-	79 (36.6)	137 (63.4)	216 (27.1)
30-	33 (30.3)	76 (69.7)	109 (13.5)
40-	27 (30.3)	62 (69.7)	89 (11.2)
50-	33 (40.2)	49 (59.8)	82 (10.3)
60+	30 (46.2)	35 (53.8)	65 (8.2)
Total	314 (39.4)	482 (60.6)	796 (100)

\* mean age =  $30.0 \pm 16.9$  years

Table 2. Site of hydatid cysts and sex distribution of patients

Organ	Male No. (%)	Female No. (%)	Total No. (%)
Liver	153 (31.6)	331 (68.4)	484 (60.8)
Lung	99 (50.3)	98 (49.7)	197 (24.7)
Other organs*	57 (54.8)	47 (45.2)	104 (13.1)
Multi-organs**	5 (45.5)	6 (54.5)	11 (1.4)
Total	314 (39.4)	482 (60.6)	796 (100)

\*Kidney, spleen

\*\*Liver / lung and liver /other organs

Table 3. Site of hydatid cysts and age distribution of patients

Age (year)	Liver No. (%)	Lung No. (%)	Other organs No. (%)	Multi-organs No. (%)	Total No. (%)
<10	27 (40.3)	33 (49.3)	4 (6.0)	3 (4.5)	67 (8.4)
10-	89 (53.0)	49 (29.2)	27 (16.1)	3 (1.8)	168 (21.1)
20-	135 (62.5)	49 (22.7)	31 (14.4)	1 (5.0)	216 (27.1)
30-	62 (56.9)	29 (26.6)	16 (14.7)	2 (1.8)	109 (13.7)
40-	68 (76.4)	16 (18.0)	5 (5.6)	0 (0.0)	89 (11.2)
50-	59 (72.0)	13 (15.9)	8 (9.8)	2 (2.4)	82 (10.3)
60+	44 (67.7)	8 (12.3)	13 (20.0)	0 (0.0)	65 (8.2)
Total	484 (60.8)	197 (24.7)	104 (13.1)	11 (1.4)	796 (100.0)

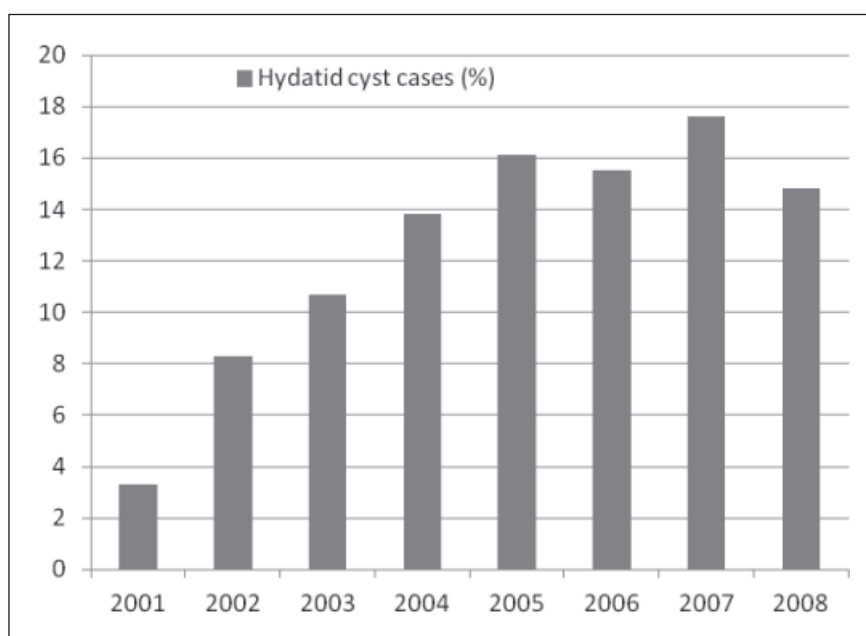


Figure 1. Frequency of hydatid cyst cases during the period 2001 – 2008 in 5 hospitals in Sana'a city

hydatid cyst (60.6%) than males (39.4%). The predominance of hydatidosis in females found in this study is also found in most reports from Yemen (AL-Hureibi *et al.*, 1992; Saif, 2001; Alghoury *et al.*, 2010), and also reported from other endemic countries such as Iraq (Molan *et al.*, 1990), Morocco (El-idrissi *et al.*, 1997), Libya (Shambesh *et al.*, 1999), Iran (Rohani *et al.*, 2004; Rostami *et al.*, 2007; Rokni, 2009). On the contrary, Fallah *et al.* (2004) stated

that the predominance of hydatid cyst in males were higher than in females. Another study conducted in central Tunisia did not find differences between the sexes (Bchir *et al.*, 1989). The proportion of males to females infected with hydatidosis in any given group is determined by local customs involving the housing, contact with contaminated vegetables and handling of dog's faeces in contaminated soil. Alghoury *et al.* (2010)

stated that in the Yemeni community a considerable proportion of females continue to have some activities related to animal breeding and/or agriculture. The transmission of this illness by means of water and the likelihood of inadequate washing of raw vegetables cannot be ruled out, since zoonotic parasites have been reported to be found in vegetables for human consumption (Slifko *et al.*, 2000). Hydatid disease is generally considered to be a rural disease because of the characteristics of its transmission cycle, which involves domestic herbivorous animals (e.g. cattle, sheep) and dogs (McManus *et al.*, 2003).

The distribution of hydatid cyst according to age showed that the highest infection rate was found in both male and female patients aged 20 to less than 30 years. A similar finding was recorded by Dopchiz *et al.* (2007). The pattern of gradual increase in prevalence of hydatid disease with age is very general and has been observed in many endemic countries (Carmona *et al.*, 1998; Shambesh *et al.*, 1999; Pawlowski *et al.*, 2001; Wang *et al.*, 2001). Rokni (2009) stated that hydatidosis is a disease of long incubation period (probably 20 to 30 yrs) and accordingly, a wide range of different ages is obvious in infected patients. In his database searches which were restricted from 1996 to 2008, the overall deduction shows the range of 20-40 years old as the age group with the highest cases.

Although different organs of the body were involved with hydatid cyst, liver is the most affected organ (60.8 %) followed by the lungs (24.7%). The predominance of liver and lung localization of hydatid cyst found in the present study also matches findings in other studies (Shir Yazdi *et al.*, 2000; Larrieu & Frider, 2001; Pezeshki *et al.*, 2007; Ahmadi & Hamidi, 2008). Lung is the second most common involved organ, but in children it is the commonest site (Ghaemi & Soltani, 2009). In the present study, the lung was recorded infected more commonly in cases younger than 10 years of age. The involvement of the lung being common in children has also been reported in other studies carried out in other endemic regions (Anadol *et al.*, 1998; Topçu *et al.*, 2000; Talaiezhadeh & Maraghi, 2006).

Multi organs affected by hydatid cyst in this study represented 1.4% and most of them were hepato-pulmonary. Dopchiz *et al.* (2007) found that the liver-lung relationship was 2.4:1 which is close to what Larrieu & Frider (2001) reported in a bibliographic review on 9,770 people with hydatidosis from Uruguay, Argentina, Tanzania, New Zealand, Israel, Jordan, Australia, Bulgaria, Turkey and Iran with values ranging from 0.89:1 to 12:1 and a general ratio of 2.5:1.

In this study the increase of the recorded cases during the years shows the significance of the disease, however, this could be due to the improved documentation of referred cases from 2001-2008. Therefore we cannot conclude that the increase was due to increased incidence of the disease during these years.

In conclusion, the risk of hydatidosis is still high in Yemen where street or stray dogs move freely. The community should be aware about the role of dogs in the transmission of this disease. The cases recorded in this study may not represent the true picture of hydatidosis in Sana'a city because many cysts remain asymptomatic and some of the patients never seek medical advice. Furthermore, some data are not available in the files. However, despite such limitations, hospital records provide a useful indication of the infection expressed as annual rate of hospital cases. Finally, the collaboration of Public Health Authorities, the Veterinary Medical Authorities and the Environmental Affairs Authorities is a must to control this disease.

*Acknowledgments.* We would like to express our special thanks to Dr. Zaid Atef for his kind assistance. Our gratefulness to all archive staff of the five hospitals for their cooperation.

## REFERENCES

- Ahmadi, N.A. & Hamidi, M. (2008). A retrospective analysis of human cystic echinococcosis in Hamedan province, an endemic region of Iran. *Annals of Tropical Medicine and Parasitology* **102**: 603-609.

- Alghoury, A., El-Hamshary, E., Azazy, A., Hussein, E. & Rayan, H. Z. (2010). Hydatid disease in Yemeni patients attending public and private hospitals in Sana'a City, Yemen. *Oman Medical Journal* **25**: 88-90.
- AL-Hureibi, A.A., Amer, A., Al-Hureibi, M.A. & Sharawee, Z. (1992). Hepatic hydatid cysts: Presentation surgical management in Yemen. *Journal of the Royal College Surgeons of Edinburgh* **37**: 229-321.
- Anadol, D., Göçmen, A., Kiper, N. & Özçelik, U. (1998). Hydatid disease in childhood: A retrospective analysis of 376 cases. *Pediatric Pulmonology* **26**: 190-196.
- Bchir, A., Larouze, B., Hamdi, A., Bouden, L., Letaiff, R. & Parazuck, T. (1989). Distribution of surgical hydatidosis in central Tunisia (1982-1985). *Acta Tropica* **46**: 47-53.
- Carmona, C., Perdomo, R., Carbo, A., Alvarez, C., Monti, J., Grauert, R., Stern, D., Perera, G., Lloyd, S., Bazini, R., Gemmell, M.A. & Yarzabal, L. (1998). Risk factors associated with human cystic echinococcosis in Florida, Uruguay: Results of a mass screening study using ultrasound and serology. *American Journal of Tropical Medicine and Hygiene* **58**: 599-605.
- Dhaifalah, I. (2001). Hydatid cyst of the uterine cervix. *Biomedical Papers of the Medical Faculty of the University of Palacky Olomouc Czech Repub* **145**: 77-78.
- Dopchiz, M.C., Elissondo, M.C., Rossin, M.A. & Denegri, G. (2007). Hydatidosis cases in one of Mar del Plata City hospitals, Buenos Aires, Argentina. *Revista da Sociedade Brasileira de Medicina Tropical* **40**(6): 635-639.
- El-idrissi, L.A., Mahjour, J., Ayoujil, M. & Barkia, A. (1997). Retrospective survey for surgical cases of cystic Echinococcosis in Morocco (1980-1992). In: Andersen FL, Ouhelli H, Kachani M, editors. Compendium on cystic Echinococcosis Brigham Young University, print Services. Provo, USA. 194-206.
- Ellaban, A., Elzayat, S., Elmuzaien, M., Nasher, A., Homesh, N. & Alabsi, M. (1994). The effect of preoperative albendazole in the treatment of liver hydatid cysts. *Egyptian Journal of Medical Laboratory Sciences* **15**: 309-319.
- El Malki, H.O., El Mejdoubi, Y., Souadka, A., Mohsine, R., Ifrine, L. & Abouqal, R. (2010). Predictive model of biliocystic communication in liver hydatid cysts using classification and regression tree analysis. *BMC Surgery* **10**: 1-10.
- Eroglu, A., Kurkuoglu, C., Karaoglanoglu, N., Tekinbas, C., Kaynar, H. & Onbas, O. (2002). Primary hydatid cysts of the mediastinum. *European Journal of Cardio-Thoracic Surgery* **22**: 599-601.
- Fallah, E., Nazer, M. & Mehdipourzare, N. (2004). Study of hydatidosis during 1995 and 2002 in East-Azarbaijan province. *5th National Iranian Congress of Parasitology Tehran, Iran*. 15-17 Nov. 480.
- Ghaemi, M. & Soltani, E. (2009). Bilateral pulmonary hydatidosis after traumatic rupture of lung hydatid cyst in a child: report of a case. *The Internet Journal of Surgery* **20**(2): 1528-8242.
- Ghallab, N.H. & Alsabahi, A.A. (2008). Giant viable hydatid cyst of the lung: a case report. *Journal of Medical Case Reports* **2**: 359.
- Larrieu, E.J. & Frider, B. (2001). Human cystic echinococcosis: contributions to the natural history of the disease. *Annals of Tropical Medicine and Parasitology* **95**: 679-687.
- Matossian, R.M., Richard, M.K. & Smyth, J.D. (1977). Hydatidosis: a global problem of increasing importance. *Bulletin of the World Health Organization* **55**: 499-507.
- McManus, D.P., Zhang, W., Li, J. & Bartley, P.B. (2003). Echinococcosis. *Lancet* **362**: 1295-1304.
- Molan, A.L., Saeed, I.S. & Baban, M.R. (1990). Prevalence of human hydatidosis in the autonomous area, northern Iraq. *Journal of Islamic Medical Association* **22**: 60-62.



- Pawlowski, Z.S., Eckert, J., Vuitton, D.A., Ammann, R.W., Kern, P., Craig, P.S., Dar, K.F., De Rosa, F., Filice, C., Gottstein, B., Grimm, F., Macpherson, C.N.L., Sato, N., Todorov, T., Uchino, J., von Sinner, W. & Wen, H. (2001). Echinococcosis in humans: Clinical aspects, diagnosis and treatment. In: Eckert, J., Gemmell, M.A., Meslin, F.X. & Pawlowski, Z.S., editors. Manual on Echinococcus in humans and animals: a public health problem of global concern. WHO. Paris, France 20-66.
- Pezeshki, A., Kia, E.B., Gholizadeh, A. & Koohzare, A. (2007). An analysis of hydatid cyst surgeries in Tehran Milad Hospital, Iran, during 2001-2004. *Pakistan Journal of Medical Sciences* **23**(1): 138-140.
- Rohani, S., Hatami, M. & Jafari, B. (2004). Study of hydatid cyst isolated from surgery patient in Taleghani hospital of Tehran during 1994 and 2003. *5th National Iranian Congress of Parasitology Tehran, Iran. 15-17 Nov.* 506.
- Rokni, M.B. (2009). Echinococcosis / hydatidosis in Iran. *Iranian Journal of Parasitology* **4**(2): 1-16.
- Rostami Nejad, M., Hoseinkhan, N., Nazemalhosseini, E., Cheraghipour, K., Abdinia, E. & Zali, M.R. (2007). An analysis of hydatid cyst surgeries in patients referred to hospitals in Khorram-Abad, Lorestan during 2002-06. *Iranian Journal of Parasitology* **2**(3): 29-33.
- Saif, W.N. (2001). Survey of the endoparasites of stray dogs in Sana'a- republic of Yemen. *Sana'a University, Faculty of Science, MSc Thesis.*
- Shambesh, M.A., Craig, P.S., Macpherson, C.N., Rogan, M.T., Gusbi, A.M. & Echuish, E.F. (1999). An extensive ultrasound and serologic study to investigate the prevalence of human cystic echinococcosis in northern Libya. *American Journal of Tropical Medicine and Hygiene* **60**(3): 462-468.
- Shir Yazdi, S.M., Mir Shamsi, M.H., Hosseini, B. & Ebadi, M. (2000). Cases of the hydatid cyst that were operated upon in Yazd. *Journal of Shahid Sadoughi University of Medical Sciences and Health Services* **1**(8): 25-30.
- Slifko, T.R., Smith, H.V. & Rose, J.B. (2000). Emerging parasite zoonoses associated with water and food. *International Journal for Parasitology* **30**: 1379-1393.
- Talaiezadeh, A. & Maraghi, S. (2006). Hydatid disease in children. A different pattern than adults. *Pakistan Journal of Medical Sciences* **22**(3): 329-332.
- Topçu, S., Kurul, I. C., Tastepe, I., Bozkurt, D., Gülhan, E. & Çetin, G. (2000). Surgical treatment of pulmonary hydatid cysts in children. *Journal of Thoracic Cardiovascular Surgery* **120**:1097-1101.
- Wang, Y.H., Rogan, M.T., Vuitton, D.A., Wen, H., Bartholomot, B., Macpherson, C.N., Zou, P.F., Ding, Z.X., Zhou, H.X., Zhang, X.F., Luo, J., Xiong, H.B., Fu, Y., McVie, A., Giraudoux, P., Yang, W.G. & Craia, P.S. (2001). Cystic echinococcosis in semi-nomadic astoral communities in North-West China. *Transactions of the Royal Society of Tropical Medicine and Hygiene* **95**(2): 153-158.