

# CASE REPORT

## A fatal case of staphylococcal scalded skin syndrome associated with iatrogenic Cushing syndrome due to potent topical steroid application in a 3-month-old female: A case report

Joanne Kate T. Milana – Martinez, MD<sup>1</sup>, Elisa Rae L. Coo, MD<sup>1</sup>, Diandra Aurora R. Zabala, MD<sup>1</sup>, Jennifer Aileen A. Tangtatco, MD, DPDS<sup>2</sup>, Maricarr Pamela M. Lacuesta – Gutierrez, MD, FPDS<sup>2</sup>

**Introduction:** Cushing syndrome caused by application of topical corticosteroids is rarely reported. Systemic side effects like suppression of hypothalamic-pituitary-adrenal axis, growth retardation in children and iatrogenic Cushing syndrome can occur even in small doses of potent topical steroids.<sup>1</sup>

**Case Summary:** This is a case of a 3-month old female who was referred to our department due to generalized erythema with desquamation. History revealed that the patient had recurrent eczema and the mother applied an over-the-counter medication containing Ketoconazole+Clobetasol 10mg/500mcg per 7-gram cream thrice daily for ten weeks. The estimated topical steroid applied weekly was around 8.5 grams and at time of admission, the patient had been exposed to approximately 50 grams of a potent topical corticosteroid. The patient presented with fever, irritability, and had positive Nikolsky sign thus managed as a case of staphylococcal scalded skin syndrome associated with topical steroid – induced iatrogenic Cushing syndrome. Unfortunately, patient's condition worsened and with progressive pneumonia, she expired on the 23<sup>rd</sup> hospital day. The fatal outcome was due to SSSS which was complicated by progressive pneumonia and topical steroid – induced iatrogenic Cushing syndrome. The complex interplay of these features eventually led to sepsis and death.

**Conclusion:** This case highlights the risks related to abuse of potent steroid-containing preparations and the importance of education to prevent severe and catastrophic outcomes of injudicious steroid use.

*Keywords: Iatrogenic Cushing syndrome, Staphylococcal Scalded Skin Syndrome, potent topical corticosteroid, adverse effects*

### INTRODUCTION

Cushing syndrome, coined by Harvey in 1912, pertains to clinical manifestations caused by excessive levels of glucocorticoids.<sup>1</sup> Iatrogenic Cushing syndrome (ICS) due to prolonged application of topical steroids is uncommonly reported and there are few published cases on pediatric iatrogenic Cushing syndrome particularly in the infantile group. In the last 35 years,

there are 22 published cases of iatrogenic Cushing syndrome due to potent topical steroid use in children, mostly infants with diaper dermatitis.<sup>2</sup> There are two reported cases wherein steroid application was started at a very early age; one of the patients died of disseminated CMV infection while the other recovered completely.<sup>3</sup> In the Philippines, there is poor and incomplete reporting of adverse drug reactions to regulatory agencies despite the legal duty to do so, hence, data are limited.

Staphylococcal scalded skin syndrome (SSSS) often presents with extensive skin surface exfoliation followed by acute erythematous cellulitis. It is a rare condition with an incidence between 0.09 and 0.56 cases / million.<sup>4</sup> Neonates and children less than 5 years are generally at high risk of SSSS due to: 1) underdeveloped immune system which is unable to produce antibodies against the exfoliative toxins and 2) immature renal clearance ability to excrete the pathologic toxins.<sup>5</sup> Clinical

<sup>1</sup> Resident, Department of Dermatology, Southern Philippines Medical Center, Davao City, Philippines

<sup>2</sup> Consultant, Department of Dermatology, Southern Philippines Medical Center, Davao City, Philippines

Source of funding: none

Conflict of interest: none

Corresponding author: Joanne Kate T. Milana - Martinez, MD

Email : katemartinez620@yahoo.com

manifestations include general malaise, fever, irritability and skin tenderness. Mucous membranes are spared, although dehydration may be present and significant.<sup>6</sup> The standard of care for patients with SSSS is directed towards the eradication of the causative agent. This requires hospitalization with intravenous anti-staphylococcal antibiotics combined with fluid correction as well as supportive skin care.<sup>7</sup>

Other bacterial infections may serve as the initial nidus for SSSS.<sup>7</sup> In this particular case, the patient had pneumonia and topical steroid – induced iatrogenic Cushing syndrome could have contributed to SSSS and progression to immunocompromised state of the patient.

This report highlights the risks related to abuse of steroid containing preparations and the importance of education to avoid preventable death and morbidity from injudicious steroid use.

### CASE REPORT

A 3-month-old female was referred to our department for generalized erythema with desquamation and scaling.

Ten weeks prior to admission, the patient developed an erythematous plaque on the neck and diaper area for which the mother applied Ketoconazole + Clobetasol 10mg/500mcg per 7-gram cream, an over-the-counter medication, thrice a day with resolution of lesions. The amount of steroid applied was approximately 8.5 grams per week. Since then, the patient's mother would apply the cream on any erythematous or scaly lesion that would appear on the patient's skin.

Four weeks prior to admission, there was

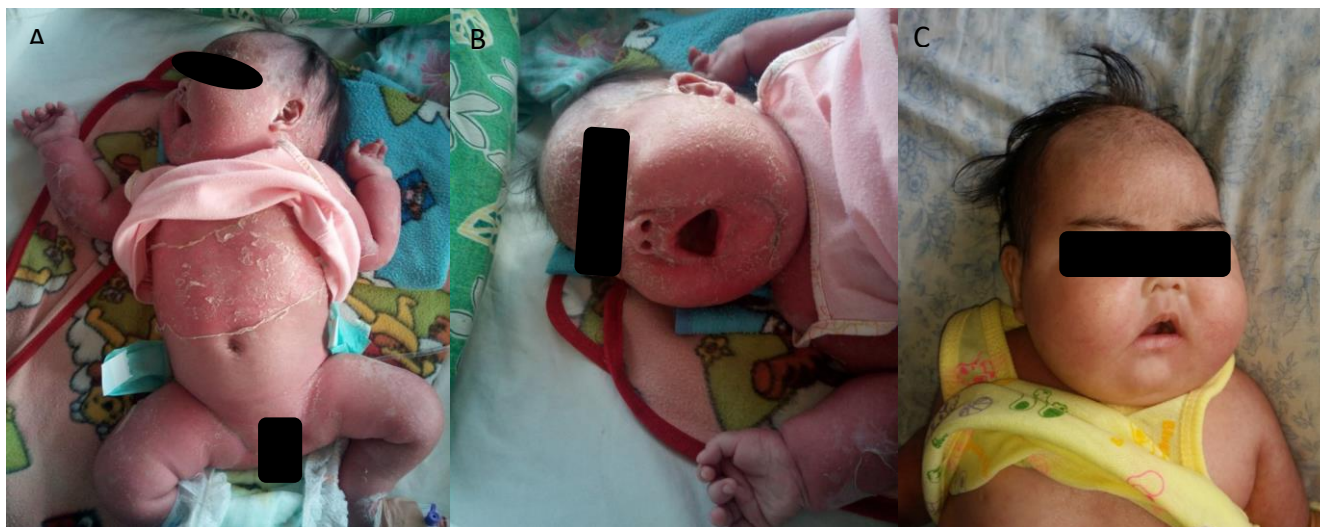coalescence of some papules into crusted plaques on the centropalpebral area which then spread to the chest, back, upper and lower extremities. The mother continued to apply Ketoconazole + Clobetasol cream in the hopes of achieving clinical resolution. At this time, approximately 50 grams of the said cream have been applied.

One week prior to admission, the lesions persisted with noted desquamation. The patient was irritable with associated fever and productive cough. They sought consult with a private physician who then referred the patient to our institution.

Birth history and family history were unremarkable. On general physical examination, the patient was irritable, febrile, tachycardic and tachypneic. Generalized anasarca was also noted. The patient was within normal weight range at 4.9 kg. Chest examination revealed intercostal and subcostal retractions, dullness upon percussion and rales on both lung fields.

Dermatologic examination (Fig.1) revealed generalized erythema and scaling with few vesicles and fragile blisters noted on the lower extremities. Nikolsky sign was positive. The oral and anogenital mucosae were not affected. Both conjunctivae did not show any signs of inflammation. We also noted cushingoid appearance, patchy hair loss on the scalp, increased hair on the face as well as easy bruising. Dermatologic working impression was SSSS associated with topical steroid-induced iatrogenic Cushing syndrome.

Laboratory results included a complete blood count which showed anemia, leukocytosis and thrombocytosis. A chest radiograph showed progressive bilateral pneumonia, and arterial blood gas indicated a fully compensated metabolic acidosis. C-reactive protein was elevated while alkaline phosphatase was normal. Urine, stool and wound



**Figure 1.** On dermatologic examination, there was noted generalized erythema with scaling (A,B) together with moon facies with visible telangiectasia over the cheeks, patchy hair loss and hirsutism (C)

cultures were unremarkable. Skin punch biopsy (Fig.2) revealed a subcorneal blister containing neutrophils and focal acantholytic cells, confirming the diagnosis of SSSS. Serum cortisol level was elevated to four times the normal value for patient's age. The patient was referred to a pediatric endocrinologist who confirmed the diagnosis of Cushing syndrome. The patient was managed with fluid replacement and intravenous antibiotics.

On the 16<sup>th</sup> hospital day, SSSS improved and the patient no longer had productive cough. She was active and had good suck. The patient was apparently well when her condition suddenly deteriorated. There was note of bruising, skin fragility, enlarging abdomen and sunken fontanels. Despite assertive therapeutic measures, the patient expired on the 23<sup>rd</sup> hospital day with final diagnosis of sepsis secondary to health care associated pneumonia, acute kidney injury, electrolyte imbalance and Cushing syndrome.

## DISCUSSION

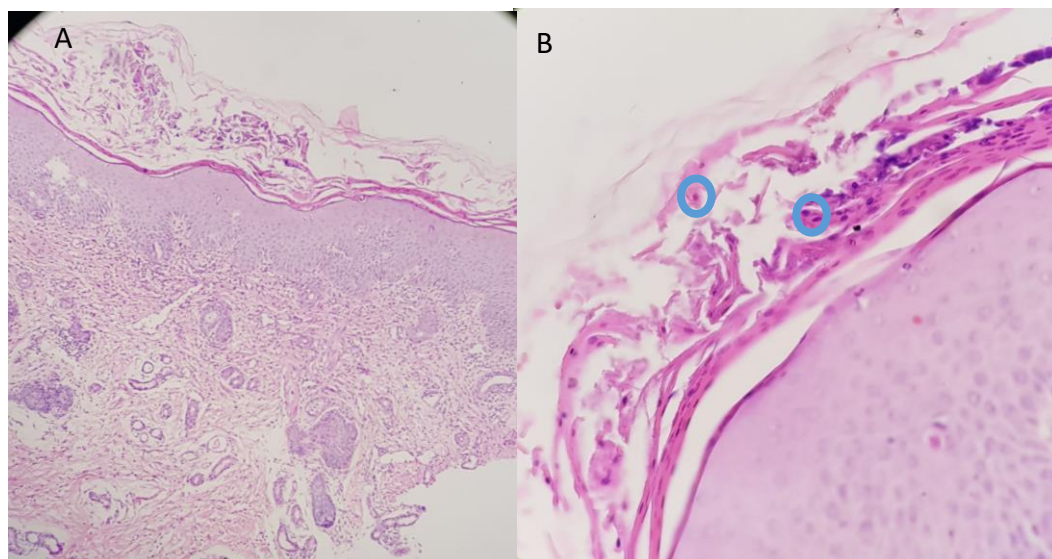
Topical steroids were introduced in the medical world in 1952 and was considered a significant breakthrough in the field of dermatology.<sup>8</sup>The same mechanism of action of steroid responsible for its improvement can also cause serious complications.<sup>9</sup> Although corticosteroids can suppress inflammation, the resultant immunosuppression may favor bacterial growth. Pediatric patients particularly infants are highly at risk of absorbing topical glucocorticoids due to a higher ratio of

skin surface area to body weight and infants are less able to metabolize potent steroids at a faster rate.<sup>10</sup>In an article by Hengge and colleagues, they recommended that topical corticosteroids be avoided in children, or if necessary, used with great care for shorter periods of time.<sup>11</sup>

Cushing syndrome is characterized by elevated cortisol levels caused by the administration of exogenous corticosteroids or by increased endogenous cortisol production. Multi-systemic organ involvement is common. Our patient also exhibited the rounded face with prominent cheeks and flushed appearance (moon facies), hirsutism and skin fragility consistent with other case reports of Cushing syndrome. This state is characterized by an impaired cell-mediated immunity with deficient neutrophil and macrophage functions predisposing to increased susceptibility to infection and sepsis.<sup>12</sup>

Staphylococcal scalded skin syndrome is a critical and potentially fatal condition that can present with fever, irritability, generalized erythema and superficial fragile blisters that progress to extensive exfoliation.<sup>4</sup> The main diagnostic features of SSSS present in our patient include all of the above mentioned clinical features, sparing of mucosae, positive Nikolsky sign as well as and histopathological evidence of a subcorneal blister with acantholytic cells. Most of the pediatric cases of SSSS have a good prognosis with a very low mortality rate of 1-5%.<sup>6</sup>

However, this condition can become critical and fatal due to superinfection, dehydration, electrolyte imbalance and sepsis.



**Figure 2.** Skin biopsy taken from a vesicle on the right leg shows basket woven stratum corneum with focal parakeratosis overlying an acanthotic and spongiotic epidermis, while the dermis reveals moderately dense perivascular inflammatory infiltrates composed of lymphocytes, numerous neutrophils and few eosinophils; a subcorneal blister containing neutrophils, bacterial debris and focal acantholytic cells is noted (A)(H & E x100) Figure 2B highlights the acantholytic cells (H & E x 400).



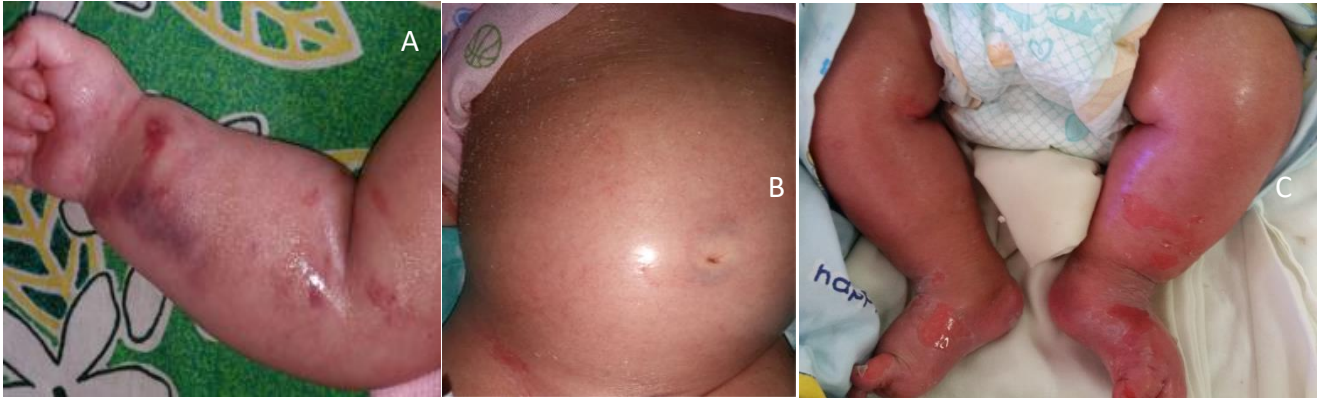

Figure 3. On the 16<sup>th</sup> hospital day, noted bruising (A), enlarging abdomen (B) and areas of erosion after removal of plaster demonstrating skin fragility (C).

In this particular case, the topical steroid - induced Cushing syndrome due to improper use of Ketoconazole + Clobetasol cream could have been the predisposing factor to the development of pneumonia and SSSS. The catastrophic outcome was a result of the complex interplay of the compounded problems due to these three disease conditions.

Ketoconazole + Clobetasol 10mg/500mcg per 7-gram cream is readily available in pharmacies within the region. The cost of a 7-gram jar can range from 29 to 42 Philippine pesos. Being readily available and inexpensive, it is common for patients or parents of pediatric patients to have little or no reservation to buy and use these medications, without prescription, from pharmacies or guided only by recommendations from relatives and friends.

## CONCLUSION

In developing countries such as the Philippines, there may be inadequate guidelines for dispensing over-

the-counter steroids.<sup>11</sup>The alarming lack of awareness regarding the serious side effects of topical steroids and the underestimation of the severity of adverse effects can result in severe and even catastrophic outcomes. Physicians should undergo continuing medical education programs which emphasizes on the harmful effects of steroid abuse and misuse. The government as well as local health committees can enact stringent laws for restricting over the counter dispensing of medications by untrained professionals. Patients and their parents should be educated on the correct time of application, quantity and duration of the medication as well as prescription obligation.

The fatal case of this 3-month-old female can only signify the tip of the iceberg since a large number of pediatric patients subjected to injudicious use of topical steroids can go undetected. ■

## REFERENCES

1. Nguyen HCT. Iatrogenic Cushing Syndrome. Medscape. 2017 March 23 [cited 2018 July 22]. Available from: <https://emedicine.medscape.com/article/117365-overview>.
2. Tempark T, Phatarakijirund V, Chatproedprai S, Watcharasindhu S, Supornsilchai V, Wanankul S. Exogenous Cushing's syndrome due to topical corticosteroid application: case report and review literature. *Endocrine*. 2010 Dec;38(3):328-34.
3. Semiz S, Balci YI, Ergin S, Candemir M, Polat A. Two cases of Cushing's syndrome due to overuse of topical steroid in the diaper area. *Pediatr Dermatol*. 2008 Sep-Oct;25(5):544-7.
4. Meshram GG, Kaur N, Hura KS. Staphylococcal scalded skin syndrome: A pediatric dermatology case report. *SAGE Open Med Case Rep*. 2018; 6: 2050313X17750890.
5. Mishra AK, Yadav P, Mishra A. A Systemic Review on Staphylococcal Scalded Skin Syndrome (SSSS): A Rare and Critical Disease of Neonates. *Open Microbiol J*. 2016; 10: 150-159.
6. Grama A, Marginean OC, Melit LE, Georgescu AM. Staphylococcal Scalded Skin Syndrome in Child. A Case Report and a Review from Literature. *J Crit Care Med (TarguMures)*. 2016 Oct; 2(4): 192-197.
7. Goldsmith LA, Katz SI, Gilchrist BA, Paller AS, Leffell DJ, Wolff K. *Fitzpatrick's Dermatology in General Medicine*. 8th ed. New York: McGraw-Hill Professional; 2012.
8. Nieman LK, Biller BM, Findling JW, Newell-Price J, Savage MO, Stewart PM, Montori VM. The Diagnosis of Cushing's Syndrome: An Endocrine Society Clinical Practice Guideline. *J Clin Endocrinol Metab*. 2008 May; 93(5):1526-40.
9. Stratakis CA., Cushing Syndrome in Pediatrics. *Endocrinol Metab Clin North Am*. 2012 December ; 41(4): 793-803.
10. Scheffel RS, Dora JM, Weinert LS, Aquino V, Maia al, Canani LH, Goldani LZ. Invasive fungal infections in endogenous Cushing's syndrome. *Infect Dis Rep*. 2010 Feb 3; 2(1): e4.
11. Hengge UR, Ruzicka T, Schwartz RA, Cork MJ. Adverse effects of topical glucocorticosteroids. *J Am Acad Dermatol*. 2006 Jan;54(1):1-15; quiz 16-8.
12. Tiwari A, Gowel M, Pal P. Topical steroid-induced iatrogenic Cushing Syndrome in the pediatric age group: A rare case report. *Indian J Endocrinol Metab*. 2013 October 17 (Suppl11): S257- S258.