

WHAT LIES BENEATH

A case of disseminated granuloma annulare successfully treated with acitretin and narrowband UV-B phototherapy

Marie Claudine Francesca B. Perlas, MD¹, Elisabeth Ryan, MD¹,
Johannes F. Dayrit, MD, FPDS², Maria Teresita G. Gabriel, MD, FPDS²

Introduction: Granuloma annulare (GA) is a benign, inflammatory skin condition characterized by asymptomatic, flesh colored or erythematous papules. The disseminated variant of granuloma annulare is uncommon, usually affecting women older than 40 years.

Case Summary: We report a case of a 52-year-old female, who presented with a 4-year history of skin colored to erythematous papules and annular plaques covering the entire skin surface. Correlation of the clinical presentation, histopathology and dermoscopy findings established the diagnosis of disseminated granuloma annulare. The patient was treated with 25 sessions of narrowband ultraviolet-B (NB-UVB) phototherapy and acitretin 20mg/day for 5 months.

Conclusion: Both histopathology and dermoscopy were noted to be valuable tools in the diagnosis of disseminated GA, as well as in monitoring response to the combined therapy.

Keywords: *Granuloma annulare, dermoscopy, acitretin, narrowband UV-B phototherapy*

INTRODUCTION

Granuloma annulare (GA) is a benign cutaneous inflammatory disease of unknown etiology. It commonly presents on the hands and feet and consisting of asymptomatic to mildly pruritic, flesh-colored to erythematous annular plaques. Granuloma annulare can be categorized as localized, generalized or disseminated, perforating, subcutaneous and patch type.¹ The most common clinical form is localized granuloma annulare. Patients with disseminated granuloma annulare have more widespread involvement, usually with 10 or more lesions. It accounts for 15% of all cases and is seen in older patients. Spontaneous resolution is less common in these patients than in patients with localized granuloma annulare.² Various treatment modalities for generalized granuloma annulare include antimalarials, phototherapy, fumaric acid esters, biologics, antimicrobials, and systemic retinoids.³ Dermoscopy is

traditionally used for diagnosis of cutaneous tumors and malignancies, but it has gained importance in the diagnosis of inflammatory skin diseases such as GA. Dermoscopic examination of this dermatosis has been reported to show heterogeneous findings, and the use of such a technique may come in handy to support the distinction from its main differential diagnoses, as well as to monitor response to therapy.⁴

CASE REPORT

A 52-year-old female presented with a 4-year history of few, skin colored to erythematous pruritic papules on the right arm. Lesions increased in number to involve the trunk and upper extremities. Diagnosis at that time was undisclosed and patient was treated with acitretin 25mg/day for 2 years, with improvement. Two years prior to consult, lesions recurred and were disseminated.

Dermatologic examination revealed generalized skin-colored to erythematous papules and scaly annular plaques on the ears, trunk, upper and lower extremities (Figure 1a-c). Initial histopathological diagnosis was Hansen's disease.

Dermoscopy revealed peripheral, structureless yellow-orange borders with whitish scaling and branching or linear vessels (Figure 2).

¹ Resident, Department of Dermatology, Research Institute of Tropical Medicine, Muntinlupa, Philippines

² Consultant, Department of Dermatology, Research Institute of Tropical Medicine, Muntinlupa, Philippines

Source of funding: none

Conflict of interest: none

Corresponding author: Marie Claudine Francesca B. Perlas, MD

Email : mcfbperlas@gmail.com

A 4-mm skin punch biopsy of the lesion revealed a foci of altered (necrobiotic) collagen surrounded by histiocytes, multinucleated giant cells and lymphocytes. There is mild fibrosis and thickening of collagen bundles in the mid-dermis, consistent with granuloma annulare (Figure 3a). Alcian blue stain highlighted the abundant mucin in the center of the necrobiotic focus (Figure 3b).

Laboratory investigation revealed normal complete blood count, fasting blood sugar, lipid profile, urinalysis, erythrocyte sedimentation rate, thyroid function test and non-reactive hepatitis profile. A chest x-ray did not reveal any abnormality.

The patient was started on acitretin 20mg/day, with concurrent narrowband ultraviolet-B (NB-UVB) phototherapy 2 times per week for 3 months. Patient underwent 25 sessions with a cumulative dose of 2321.580 J/cm². Liver enzymes and lipid profile were monitored every month for the first 2 months, then every 3 months,

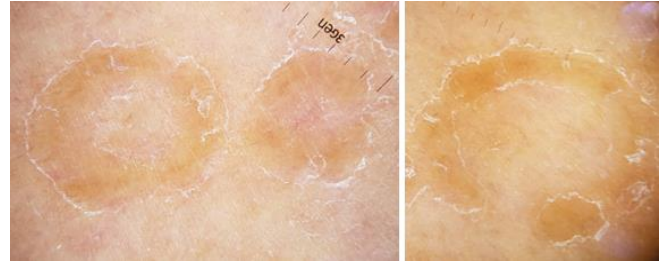

Figure 2. Dermoscopy revealed peripheral, structureless yellow-orange borders with whitish scaling and branching or linear vessels.

which all revealed normal results. During this period, there was noted decrease in the number of lesions and flattening of plaques (Figure 4). Dermoscopy of resolved lesions show lightening of yellowish-orange areas, clearing of irregular borders and scales and disappearance of the linear blood vessels (Figure 5). Patient was followed up

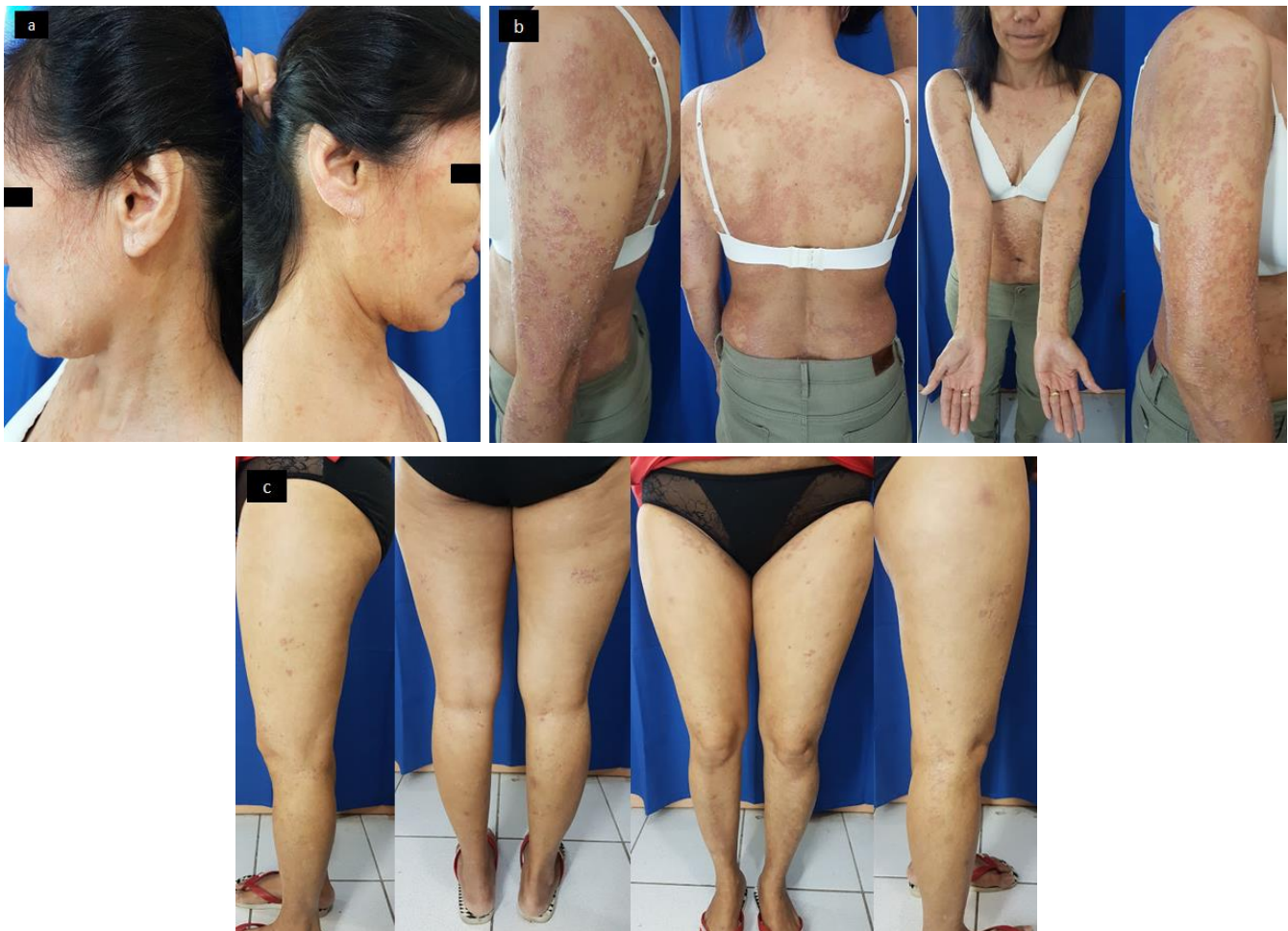

Figure 1a-c. Multiple skin colored to erythematous papules and scaly annular plaques on the face, trunk and extremities.

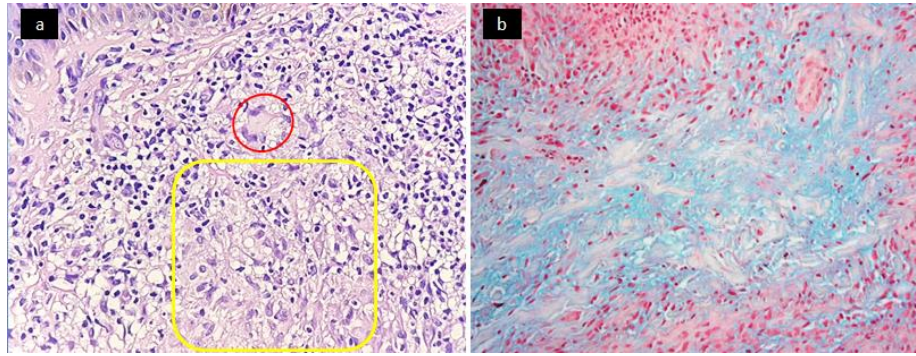


Figure 3. a) The dermis reveals foci of necrobiosis (yellow square) surrounded by multinucleated giant cells (red circle), histiocytes and lymphocytes (H & E, x100) **b)** Alcian blue stain highlights the abundant mucin at the zone of necrobiosis (x100).

every month and is presently on remission for 1 year already.

DISCUSSION

Granuloma annulare is an idiopathic, self-limited cutaneous condition that is common in adults and children.² The condition is a benign inflammatory disease associated with many conditions such as malignancy, trauma, thyroid disease, diabetes mellitus, and HIV infection.³ The skin manifestations of GA are polymorphic owing to the many variants of the disease, including localized, generalized, subcutaneous, perforating and patch type. The localized GA is the most common form, accounting to 75% for all cases of GA common in patients under 30 years old, with female predominance. It most commonly occurs on the dorsal hands and feet.⁴ The disseminated or generalized GA is widespread, having 10 or more lesions, which occurs in 8-15% of patients with GA.^{4,5} It is more likely to occur in middle age or older patients.⁴ Subcutaneous GA is diagnosed primarily in

children 2 to 5 years of age. They are seen on the scalp, buttocks and extremities.⁵ The perforating GA is a distinct and rare form, characterized by its central umbilication. It is common in children and young adults.^{4,5} The patch type is also a rare form, characterized by erythematous, red-brown or violaceous patches without an annular rim.¹

The etiology of GA is unknown, although its histological findings support a delayed-type T-helper 1 (Th1) cell-mediated hypersensitivity reaction and cell-mediated immune response.^{2,3}

GA on histology is characterized by necrobiosis or mucinous degradation of collagen with either palisading or interstitial granulomatous infiltration.³ The presence of mucin is the key histological feature to distinguish GA from other non-infectious granulomatous diseases such as sarcoidosis and necrobiosis lipoidica.⁴ The histiocytes in GA have been described in four patterns: (1) interstitial pattern, (2) surrounding the palisading granulomas, (3) nodules that resemble sarcoidosis, and (4) a mixed pattern.^{4,6}

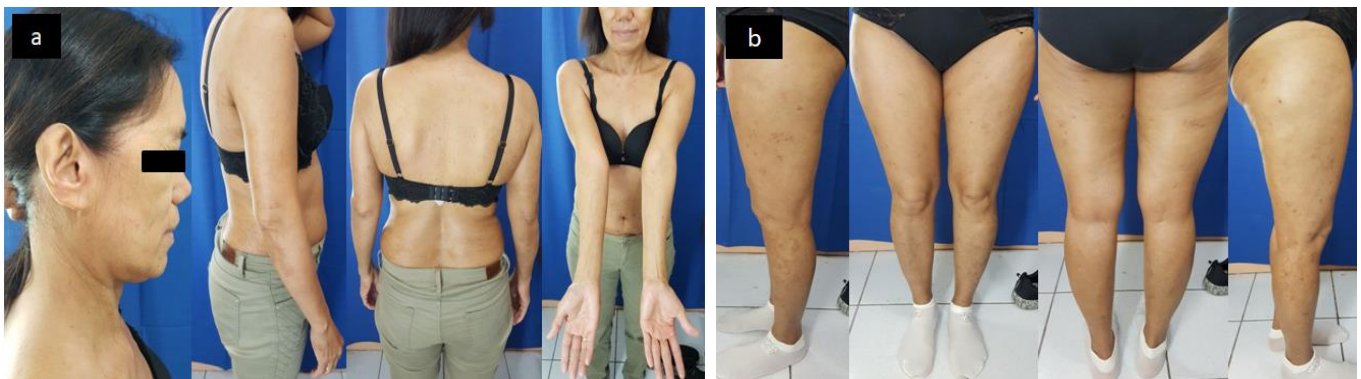

Figure 4a-b. There is decreased number and flattening of lesions after 5 months of acitretin 20mg/day, combined with NB-UVB phototherapy with a cumulative dose of 2321.580 J/cm².

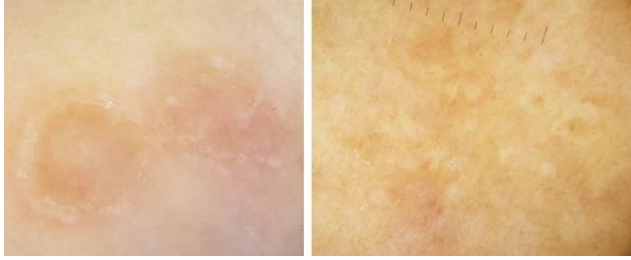

Figure 5. Dermoscopy at baseline (a) and (b) resolved lesions which show lightening of yellowish-orange areas, clearing of irregular borders and scales and disappearance of the linear blood vessels after 5 months of treatment.

Aside from biopsy, dermoscopy is a non-invasive diagnostic tool that aids in the diagnosis of GA. According to the study of Errichetti et al, the presence of blurry vessels having variable morphology (dotted, linear-irregular, and branching) over a more or less evident pinkish reddish background is a nearly constant dermoscopic feature of GA. Whitish (irregular or globular) and yellowish-orange (focally or diffusely distributed) areas represent the most common non-vascular findings. Additional dermoscopic findings include pigmented structures and crystalline leaf venations (whitish, parallel, secondary striae branching from a central vein). By analyzing dermoscopy of GA according to histological subtypes, Errichetti and colleagues observed a strict association between yellowish-orange structureless areas, especially those having diffuse distribution, and a palisading granuloma histological pattern, thereby confirming the well-known dermoscopic-pathological correlation between such a color and dermal granulomatous inflammatory infiltrate. On the other hand, although quite uncommonly (less than one fifth of cases), focally distributed yellowish-orange structureless areas were also detected in lesions displaying an interstitial histological pattern.⁷

Treatment options vary depending on the type of GA. Topical or targeted therapies may be effective in treating localized GA, generalized GA follows a more chronic course and commonly requires phototherapy or systemic drug therapy.

Phototherapy remains the most promising and reliable treatment modality for generalized GA. It suppresses lymphocyte proliferation and cytokine production. In a study by Cunningham and Pavlovsky et al, there was a complete or partial remission in 54–70% of patients with GA, with a median number of 35 treatments and a cumulative dosage of 47.7 J/cm².^{8,9} In a study by Solano-Lopez, a total of 27 sessions were performed on his patient; a cumulative dose of 26.155 J/cm². The patient

showed good tolerance and an excellent response, with the affected body surface area decreasing from 28 to almost 0.¹⁰

Acitretin, a potent second-generation retinoid, acts at the intranuclear level to alter the expression of epidermal growth factor genes. Its immunomodulatory effects inhibit both neutrophil migration and dermal microvascular endothelial cells. The resulting anti-keratinizing, anti-inflammatory properties of acitretin help to normalize epidermal proliferation, differentiation and cornification.¹¹

Two case reports of generalized GA treated with combined therapy of NB UVB and acitretin reported complete clearance. The first case is a 68-year-old man who presented with a 2-month history of generalized GA over the trunk and legs. Acitretin was introduced at 10 mg daily, with concurrent NB UVB therapy (cumulative total of 15.5 J/cm²) over 31 sessions for 10 months. The combination therapy led to a total clearance of the GA. On review, 6 months post-cessation of therapy, mild GA was observed. The patient was restarted on acitretin 10 mg daily as monotherapy and the GA rash responded with an almost complete clearance at the 5-month review.

The second case is a 62-year-old woman presented with a 2-year history of generalized GA involving her flank, abdomen and legs. Acitretin 10 mg daily was initiated for 11 months, with NB UVB therapy twice weekly (cumulative dose of 13.9 J/cm²) for 32 sessions over 4 months. During this period the generalized GA had cleared entirely. Six months post-cessation of acitretin the patient presented with a mild recurrence of GA on the trunk. Acitretin 10 mg daily and NB UVB was restarted and an almost complete clearance of the rash was noted after 2 months.¹²

CONCLUSION

The disseminated variant of GA is rare. The clinical and histopathological features may resemble other inflammatory and infectious granulomatous diseases. The dermoscopic features may aid in the diagnosis and may be utilized to monitor response to therapy. The management of disseminated GA is challenging to the dermatologist. Several treatment options are offered, however, efficacy and safety studies are limited due to the rarity of this variant of this disease. In our case, the combination therapy of acitretin and NB UVB phototherapy has been observed to clear up all lesions in a 5-month period and the patient still remains in remission after 1 year of cessation of therapy. ■

REFERENCES

1. Goldsmith L, Katz S, Gilchrist B, Paller A, Leffel D, Wolff K. 18th ed. New York:McGraw-Hill. 2012; 467-72.
2. Gopal MG, Gupta D, Kumar S, Nandini R. Granuloma annulare mimicking sarcoidosis and treated with acitretin: a case report. *J Evol Med Dent Sci*. 2013; 2(48): 9297-301.
3. Wang J, Kachemoune A. Granuloma annulare: A focused review of therapeutic options. *Am J Clin Dermatol*. 2017. doi.org/10.1007/s40257-017-0334-5.
4. Thornsberry LA, English JC 3rd. Etiology, diagnosis, and therapeutic management of granuloma annulare: an update. *Am J Clin Dermatol*. 2013;14(4):279–90.
5. Cyr PR. Diagnosis and management of granuloma annulare. *Am Fam Physician*. 2006; 74(10):1729–34.
6. Gunes P, Goktay F, Mansur AT, et al. Collagen-elastic tissue changes and vascular involvement in granuloma annulare: a review of 35 cases. *J Cutan Pathol*. 2009;36(8):838–44.
7. Erichetti E, Lallas A, Apalla Z, Di Stefani A, Stinco G. Dermoscopy of granuloma annulare: A clinical and histological correlation study. *Dermatology*. 2017;233:74-79.
8. Cunningham L, Kirby B, Lally A, Collins P. The efficacy of PUVA and narrowband UVB phototherapy in the management of generalised granuloma annulare. *J Dermatolog Treat*. 2016;27(2):136–9.
9. Pavlovsky M, Samuelov L, Sprecher E, Matz H. NB-UVB phototherapy for generalized granuloma annulare. *Dermatol Ther*. 2016;29(3):152–4.
10. Solano-Lopez G, Concha-Garzon MJ, de Argila D, Dauden E. Successful treatment of disseminated granuloma annulare with narrowband UV-B phototherapy. *Actas Dermosifilogr*. 2015;106:240-241.
11. Ormerod AD, Campalani E, Goodfield MJ. British association of dermatologists guidelines on the efficacy and use of acitretin in dermatology. *Br. J. Dermatol*. 2010; 162: 952–63.
12. Bala HR, Khan S, Chong A. Two cases of generalised granuloma annulare successfully treated with acitretin and NB UVB therapy. *J Am Acad Dermatol*. 2005. doi:10.1016/j.jaad.2005.02.022..