

Hugs for keeps: A case report of pessary insertion in preterm twin gestation in the Philippines*

BY KOLEEN C. PASAMBA, MD AND REGINA ROSARIO M. PANLILIO VITRIOLO, MD, FPOGS, FPSUOG
Department of Obstetrics and Gynecology, Philippine General Hospital, University of the Philippines-Manila

ABSTRACT

Preterm birth accounts to 35 % of deaths in a year. Twin gestation, around 7.2 per 1000 births in the Philippines, is a known risk factor that increases likelihood of preterm birth compared to singletons. Most studies that addresses preterm births are focused on singleton pregnancies. There have been no established recommendations to control preterm labor in twin pregnancies. Pessary insertion is among these recommendations. There are no reported cases of pessary insertion to control preterm birth among twins in the Philippines. This study presents a case of twin gestation in preterm labor and no functional cervix on transvaginal ultrasound. Hodge pessary was inserted at 28 weeks age of gestation. She delivered at 36 weeks to live baby girls, both 2,200 grams and were directly roomed-in. Further studies are recommended to establish stronger evidence supporting pessary use in multiple gestation to improve outcome of neonates.

Keywords: Pessary, preterm birth, preterm labor, twin pregnancy

INTRODUCTION

Preterm birth, delivery prior to 37 weeks age of gestation, accounts for 35 % of 3.1 million total deaths in a year.¹ It can lead to respiratory distress and poor development due to underdeveloped lungs and brain resulting to increased neonatal intensive care unit admissions. More than 75 % of these deaths can be prevented by treating preterm labor.¹

Multiple gestation has a 6 fold risk for preterm birth as compared to singleton.¹ The rate of twin pregnancies in the Philippines is at 7.2 births per 1,000 births with an increasing trend of 0.03 every year.² About 50 % of twin pregnancies deliver before 37 weeks.¹ Because of the restricted fetal growth of multiple pregnancies, there is a high rate of low birth weight among multiple gestation pregnancies.

Several studies to control preterm labor have been done to help improve the outcome and prevent complications secondary to prematurity. Progesterone, cervical cerclage, and pessary are among the modalities suggested to prolong gestation to improve perinatal outcome. Among singletons, progesterone was observed to prevent preterm labor by decreasing concentration

of myometrial oxytocin receptors; decreasing the risk of preterm birth from 55 % to 36 %.¹ Cochrane collaboration published a systematic review on cerclage confirming a reduced risk of 20 % for singleton.¹ Pessary insertion decreased risk of preterm birth from 59 % to 27 % in a multicenter randomized control trial among singleton.¹

Pessaries were first used to treat pelvic organ prolapse. It is a prosthetic devise, mostly made of non-absorbable silicon, inserted to the vagina to support organs from prolapsing. Later, it was suggested for treatment of preterm labor.

According to the Philippine clinical practice guidelines, pessary, progesterone and cerclage are not recommended for preterm labor among multiple gestation due to the conflicting and few evidences on their benefits.¹ Literature search showed no written reports yet on use of pessary to extend age of gestation in twin gestation in the Philippines.

We report a case of a 26 year old Gravida 3 para 2 (2002), with twin gestation who presented with preterm labor at 27 weeks and 2 days age of gestation. A pessary was inserted at 28 weeks to optimize the maturity of the babies.

CASE REPORT

A 26-year-old gravida 3 para 2 (2002) was admitted for preterm labor. She has no previous history or family history of any medical condition. She has no previous

*Finalist, Philippine Obstetrical and Gynecological Society (Foundation), Inc. (POGS) Interesting Case Paper Contest, September 12, 2019, 3rd Floor Assembly Hall, POGS Building, Malakas Street, Diliman, Quezon City

surgeries. Her husband has cousins who are twins. She has no vices. Her first two pregnancies were carried to term, delivered by spontaneous vaginal delivery at a lying-in center with no complications.

At the time of consult, her last normal menstrual period was October 20, 2019 giving her 28 weeks and 6 days age of gestation by amenorrhea. Her earliest ultrasound was done at 10 weeks and 4 days age of gestation last January 13, 2019 giving her 27 weeks and 2 days age of gestation by early ultrasound.

She had her prenatal consults at a local health center 4 times. She was seen at the same local health center 1 day prior to consult for irregular uterine contractions, no watery or vaginal discharge but was referred to a tertiary hospital for management where she was seen at the emergency room.

She has stable vital signs and essentially normal systemic physical examination. (Table 1) Pertinent physical examination findings were cephalic presentations of both babies with good heart tones and normal estimated fetal weights for age. On internal examination, the cervix was 1 cm dilated, beginning effacement, midposition, and medium in consistency. The admitting diagnosis was pregnancy uterine 27 weeks and 2 days age of gestation by early ultrasound, cephalic-cephalic in preterm labor, twin gestation; vulvovaginal candidiasis; gravida 3 para 2 (2002).

Targeted imaging for fetal anomalies, congenital anomaly scan, biophysical profile, cervical length and doppler velocimetry studies were done at baseline during the admission. The results showed no gross fetal structural abnormalities with biophysical profile of 10/10 for both twins, and normal doppler flow studies. She has no functional cervix on measurement of her cervical length by transvaginal ultrasound. Urine culture was also sent to diagnose for asymptomatic bacteriuria which showed no growth for 2 days. The rest of her laboratory results were unremarkable (Table 2).

She was given dexamethasone 6 mgs 4 doses intramuscular every 12 hours for fetal lung maturity, miconazole 1.2 g vaginal suppository once for treatment of the vulvovaginal candidiasis, micronized progesterone 200 mg capsule orally twice a day as part of the treatment for prevention of preterm labor and prenatal supplements.

Due to the diagnosis of absence of a functional cervix through ultrasound, a 1 centimeter cervical dilatation on internal examination and an advance age of gestation for cerclage, the team opted to have a pessary inserted for the patient. At day 4 of admission, after the resolution of the vulvovaginal candidiasis and release of results of urine culture, the patient was evaluated for pessary insertion.

On the 5th hospital day, at 28 weeks age of gestation, a Hodge pessary was inserted. (Figure 1)

Table 1. Physical findings of index patient during first admission

Vital signs	<ul style="list-style-type: none"> • Blood pressure: 110/70 mmHg • Heart rate: 80 beats per minute • Temperature: 36.5 degrees Celsius • Respiratory rate: 20 breaths per minute • Weight: 68.5 kg • Height of 156 cm • Body mass index: 28.4.
Head and neck examination	<ul style="list-style-type: none"> • Pink conjunctivae • No cervical lymph adenopathies • No anterior neck masses
Chest examination	<ul style="list-style-type: none"> • Clear breath sounds • Equal chest expansion • Distinct heart sounds • Normal, regular rhythm • No heart murmurs
Abdominal examination	<ul style="list-style-type: none"> • Fundic height: 28 centimeters • Combined estimated fetal weight: 2 – 2.2 kg • Cephalic-cephalic presentation • Good heart tones at the bilateral lower quadrants
Speculum and internal examination	<ul style="list-style-type: none"> • Normal external genitalia • Smooth parous vagina • Whitish curd-like discharge on her vulva and vaginal area • Cervix: smooth, dilated to 1 centimeter, beginning effacement, midposition, medium consistency, with intact bag of waters, and head at station – 3
Extremities	<ul style="list-style-type: none"> • No edema • Full and equal pulses



Figure 1. Actual Hodge pessary inserted in the patient. The arrow head is the part anchored to the posterior border of the symphysis pubis.

Table 2. Laboratory results of index patient taken during first admission

	Results
Targeted imaging for fetal anomalies, congenital anomaly scan	No gross structural abnormalities
Biophysical profile	<ul style="list-style-type: none"> • Twin A: cephalic presentation, 26 weeks and 6 days age of gestation by composite sonar aging, Biophysical profile score - 10/10 with adequate amniotic fluid, estimated fetal weight - appropriate for gestational age (944 grams) • Twin B: cephalic presentation, 27 weeks and 1 day age of gestation by composite sonar aging, biophysical profile score - 10/10 with adequate amniotic fluid, estimated fetal weight is appropriate for gestational age (998 grams) • Placenta was anterior, high-lying, grade II, monochorionic, diamnionic.
Doppler velocimetry studies	<ul style="list-style-type: none"> • Uterine arteries show normal values for both uterine arteries • Doppler studies of the umbilical artery show normal values • Doppler studies of the umbilical artery show normal values
Cervical length	No functional cervix
HbsAg	Nonreactive
VDRL/RPR	Nonreactive
ICC Elisa	Nonreactive
Urine culture	No growth for 2 days
Vaginal swab culture	No growth for 2 days
Hemoglobin	125 g/L
Hematocrit	0.35
platelet	174 x10 ⁹ /L

She was monitored post insertion for contractions as well as for watery and bloody vaginal discharge. Repeat cervical length determination was done on the same day after insertion of the pessary. The scan showed cervical length of 2.38 cm with no funneling. (Figure 2)

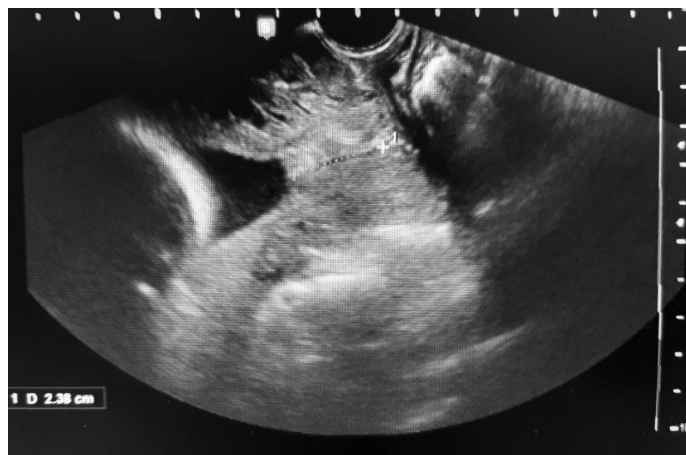

Figure 2. Cervical length post insertion of pessary

She was discharged on the 7th Hospital day with stable vital signs with no uterine contractions and pessary in place. She was sent home with micronized progesterone 200 mg twice a day orally and was advised to continue taking her prenatal medications.

Follow-up ultrasound done at 29 weeks and 2 days showed a cervical length of 2.3 cm with no funneling. Fetal well-being studies showed a biophysical profile score of 8/8. Mild uterine contractions every 8 minutes were however observed for which she was advised further monitoring and management at the emergency room. However, the patient opted to go home and rest where she noted resolution of the uterine contractions

She was lost to follow-up and returned to the institution at 35 weeks and 6 days age of gestation for yellowish vaginal discharge and irregular uterine contractions but with good fetal movements. She had stable vital signs. On abdominal exam, her fundic height was 36 cm. The presentation of the twins were both cephalic with good fetal heart tones at the bilateral lower quadrants. On speculum exam, she had normal external genitalia, smooth parous vagina and yellowish vaginal discharge. On internal examination, pessary was in place. After removal of pessary, the cervix was dilated to 3 centimeters, 50 % effaced, and soft consistency at mid-position. The bag of waters was intact.

She delivered by spontaneous vaginal delivery after 7 hours of labor to live baby girls, both with Apgar scores of 9 remaining 9, 36 weeks by pediatric aging and appropriate for gestational age. Both babies were roomed in.

The mother and both babies were discharged with stable vital signs.

CASE DISCUSSION

Preterm labor can lead to preterm birth which can eventually lead to low birth weight, poor Apgar score, neonatal intensive unit admission, use of ventilators due to respiratory distress and poor development due to immature brain. Learning disabilities, behavioral problems and higher risk for heart disease, hypertension and diabetes are some of long term effects of preterm birth.^{1,2} Prevention and treatment of preterm labor, thus, can lead to better outcome.

Preterm labor happens when there is dilatation or effacement of cervix brought about by uterine contractions. It can be diagnosed clinically and with support of transvaginal ultrasonography. Cervical assessment by ultrasound is used as adjunct to the clinical findings. A short cervical length of less than 2.5 cm on ultrasound is suggestive of preterm labor.¹ The cervical length in the absence of uterine contraction can also be a predictor of preterm birth. According to Zuo et al, they saw an increase preterm birth before 32 weeks with cervical length of < 17.5 mm and < 18.5 mm measured at 28 to 32 weeks age of gestation in singletons.³ Fortunately, our patient was able to have a longer age of gestation despite the high probability of her delivering at an earlier due to the presence of twins.

Based on the findings of uterine contractions and a dilated cervix with no functional cervix on transvaginal ultrasound, our index case was diagnosed to be in preterm labor.

Compared to singleton gestation, the mechanism causing preterm labor in multiple gestation is different. In multiple gestation, there is over distention of the uterus that causes stretching of myometrium and increases the response of oxytocin receptor. This activates prostaglandin that can lead to cervical dilatation and uterine contractions.² Inflammation, infection, decidual hemorrhage, and activation of maternal or fetal hypothalamic-pituitary-adrenal axis are other processes that cause preterm labor. In our patient, she has uterine over distention from her twin pregnancy and infection. The patient had vulvovaginal candidiasis which contributed to her having preterm labor, which we also treated with miconazole.

Treating preterm labor in twin gestation is a challenge because the current modalities to prevent preterm labor in general are not yet proven to be effective among twin pregnancies. Among singleton, modalities recommended that have exhibited benefits are progesterone and cervical cerclage. Cerclage is done during 12 to 14 weeks up to 23 weeks age of gestation by doing a pursestring stitch

under anesthesia at the cervix for reinforcement. Its complications are preterm labor, infections, and rupture of cervix or bag of waters.⁴ Pessary has shown benefits but there are not enough statistically significant studies. Tocolytic agents are recommended only to delay labor to facilitate administration of steroids for fetal lung maturity.

Pessary may be used for cases with later gestational age wherein cervical cerclage cannot be placed anymore.^{1,4} We decided to use pessary because of the age of gestation of the pregnancy. The patient is already almost 28 weeks age of gestation, thus cerclage will not be possible.

There are two general types of pessary, the supporting type and the space occupying types. Both are used in pelvic organ prolapse depending on the degree of prolapse. The supporting type of pessaries are the one used to control preterm labor. Examples of the supporting type are the ring pessaries, Arabin and Hodge. The Arabin pessary is a circular ring with a smaller inner circle.⁵ (Figure 3) The smaller inner circle acts as the constrictor of the cervix. The Hodge pessary is an angulated ring. (Figure 1) These angles allow the displacement of the cervix towards the posterior.⁵

The contraindications for pessary insertion include an ongoing pelvic infections, pelvic inflammatory disease, genitourinary tract infections, endometriosis, or uterine contractions. The pessary may worsen present infections since it is a foreign body. The pessary will not stop contractions and patient will still progress into labor if there are contractions.⁵

Proper size is chosen using sample rings by trial and error. Once the proper size is chosen and a new piece is manufactured, the pessary can be inserted. Aseptic




Figure 3. Arabin pessary

technique was strictly observed with proper hadwashing and use of sterile gloves. The pessary is coated with lubricant first. Next, perineum is pressed down and the pessary is compressed and directed towards the posterior fornix making sure that the pessary surrounds the cervix. The pessary will assume its form once inserted. The pessary can be turned using the examining finger to place properly. The indications that show a wrong fit are not being able to stand and bear down without dislodging the pessary, discomfort when sitting down, and difficulty in urination. Easily dislodged pessaries indicate small size. Discomfort and difficulty in urination may indicate tight fit or wrong position. Tight fit pessaries can lead to tissue damage.⁵

Pessaries are ideally washed every other day with mild soap and warm water. It is removed by gently moving it forward towards introitus. The pessary should be checked at least weekly for proper placement. The patients are also advised to consult for water or purulent vaginal discharge, discomfort, urinary or bowel changes. Our patient was advised properly however, due to the distance of travel to the institution, the patient opted to consult when she noted contractions.⁵ Ideally, pessary is removed at 37 weeks or earlier if with labor progression and worsening discharge.

Randomized control trials in different countries in the recent years showed contradicting results on pessary use for preterm twin pregnancies. No significant difference was observed among twin pregnancies who had Arabin pessary inserted compared to the control group in a study done in USA.⁷ In a trial in Spain, there was a significant decrease in preterm delivery less than 34 weeks and neonates weighing less than 2,500 grams among those with Arabin pessary inserted.⁷ The major concern of the reliability of these trials was the small sample sizes.

The ProTWIN, a multicenter trial conducted for multiple pregnancy and pessary insertion, showed a 60 % reduction in perinatal outcome among treatment group extending the age of gestation to 10 days. The follow-up of this study further supports the benefit of pessary by a significant difference in the survival rate and neurodevelopment among pregnancies managed with pessary.⁸

The proposed mechanisms in which the pessary work to control preterm labor are by changing the angle of the cervix wherein there is less pressure inserted into the cervix, and diminishing the Ferguson reflex which is a loop producing oxytocin from pressure on the cervix communicating to the hypothalamus and pituitary glands.^{6,8,9} The mechanism on displacing the cervix is illustrated in Figure 4. On follow-up transvaginal scans post pessary insertion of our patient, the noted significance was a longer cervical length from no functional cervix to a 2.38 cm cervical length. No functional cervix happens when there is no more cervical length that

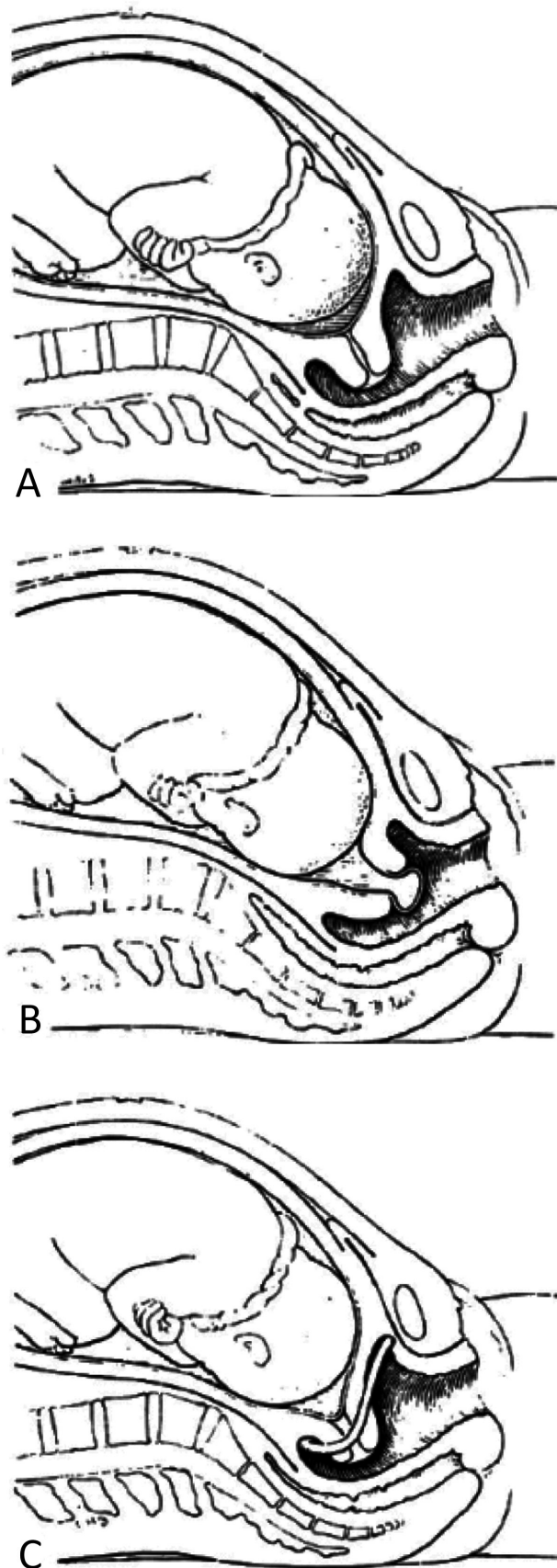


Figure 4. Image 4. A. Normal cervix B. A shortened or incompetent cervix C. The pessary displaces the cervix posteriorly.⁹ (Javert CT: Further follow-up on habitual abortion patients. *Am J Obstet Gynecol.* 1962; 84:1149.)

can be measured on ultrasound.

The studies reviewed and this case illustrate promising benefits of pessary in preventing preterm labor in twin gestation to improve pregnancy outcome. It is prudent to do more trials, reviews, and meta-analysis with good follow-up and protocol to provide stronger evidence of the benefits of pessary insertion.

SUMMARY

Preterm births are heart-breaking situations for both parents and the attending obstetrician. Preterm birth of twins doubles the anxiety. The novel use of a known

device is encouraging. Pessary use in multiple pregnancies may be new in our country but this index case may hold promise for better outcomes for twin gestations at risk of preterm births. More studies should be done to see its real benefits. Pessary may be the hug that keeps the twins towards maturity and a better future.

ACKNOWLEDGEMENTS

Thank you to perinatology service and urogynecology service, composed of Dr. Macarubio, Dr. Espra, and Dr. Manalastas, and to my co-residents helped our team. Thank you to God and my family for all the support. ■

REFERENCES

1. Fontana L, Gentilin B, Fedele L, Gervasini C, Mlozz M. Genetics of Mayer-Rokitansky-Kuster-Hauser (MRKH) Syndrome. *Clin Genet*. 2017; 91:233-46.
2. ACOG Committee Opinion No. 728: Müllerian Agenesis: Diagnosis, Management, And Treatment. *Obstetrics and Gynecology*. Vol 131. No. 1, January 2018.
3. Abbott JA. Adenomyosis and Abnormal Uterine Bleeding (AUB-A)-Pathogenesis, diagnosis, and management. *Best Practice Research. Clin Obstet Gynaecol*. 2017; 40:68. Epub 2016 Sep 30.
4. Enatsu A, Harada T, Yoshida S, Iwabe T and Terakawa N. Adenomyosis in a patient with the Rokitansky-Kuster-Hauser Syndrome. *Fertility and Sterility*, vol 73, no 4, pp 862-863, 2000.
5. Lamarca M, Navarro R, Ballesteros M, Aguirre S, Conte M, Duque J. Leiomyomas in both uterine remnants in a woman with the Mayer-Rokitansky-Kuster-Hauser Syndrome. *Fertility and Sterility*. Vol 91, No.3, March 2009.
6. Amaratunga T, Kirkpatrick I, Yan Y, Karlicki F. Ectopic Pelvic Fibroid in a Woman with Uterine Agenesis and Mayer-Rokitansky-Kuster-Hauser Syndrome. *Ultrasound Quarterly*. Vol 33. No. 3. September 2017.
7. Hoo PS, Norhaslinda AR, Reza JN. Case Report. Rare Case of Leiomyoma and Adenomyosis in Mayer-Rokitansky-Kuster-Hauser Syndrome. *Case Reports in Obstetrics and Gynecology*. Volume 2016.
8. Chun S, Jeon H, Cho J, Kim M, and Ji I. Endometrial Hyperplasia in Myometrium of Woman with uterine adenomyosis: a case report. *Reproductive Biology and Endocrinology*. Vol. 4, No. 1 pp 56-60. 2012.
9. Meera D, Rani GU, Syamala O. Adenomyosis in a Rudimentary Horn of a Mayer-Rokitansky-Kuster-Hauser Syndrome. 10.505/jp-journals-10032-1055.
10. M.Y. Choi and M. M. Ka. Uterine fibroids and adenomyosis in a woman with Rokitansky-Kuster-Hauser syndrome. *Journal of Obstetrics and Gynaecology*, Vol. 22, no. 5, pp. 561-562, 2002.
11. Kil Kicheol, Chung Jae-Eun, Pak Ho Jeong, et.al. Usefulness of CA 125 in the the differential diagnosis of uterine adenomyosis and myoma. *European Journal of Obstetrics and Gynecology and Reproductive Biology*. 2015 (185)131-135.