

The Use of Tropical Fruits for Skills Training in a Neurosurgical Boot Camp

Juan Silvestre G. Pascual, MD; Kevin Ivan P. Chan, MD; Mary Angeline U. Hernandez, MD; Edroico B. Brillante, MD; Edmund John B. Cayanong, MD; Llex C. Soriano, MD; Gerardo D. Legaspi, MD, FPCS and Kathleen Joy O. Khu, MD

Division of Neurosurgery, Department of Neurosciences, Philippine General Hospital, University of the Philippines Manila

Objective: Neurosurgical boot camps allow trainees to hone practical skills in a risk-free environment, but the models and simulators used are relatively costly. In developing countries like the Philippines, low-cost alternatives have to be devised. The authors aimed to demonstrate the feasibility of using local, readily available, and inexpensive tropical fruits as surrogate models for basic neurosurgical skills training during a neurosurgical boot camp.

Methods: Locally available tropical fruits were used to teach basic neurosurgical skills to trainees. Coconut, pomelo, and watermelon were used as models for head clamp application, scalp and dural suturing, and ventriculostomy, respectively. Feedback was obtained from the participants after the boot camp.

Results: All eight residents thought that the boot camp was useful in learning new skills, and that the fruit models served their purpose. The trainees favored the fruit models that catered to the skill sets required according to level of training. The use of tropical fruits in the boot camp also provided an informal atmosphere that was conducive to learning.

Conclusion: The novel use of tropical fruits as surrogate models in basic neurosurgical skills training was a feasible and affordable alternative in resource-limited settings, although the activity was perceived to be more useful to junior than to senior residents. The informal atmosphere generated by the use of the fruits contributed to an improved learning experience for the trainee.

Key words: Teaching, simulation training, surgical skills, low-cost

Neurosurgical boot camps have been used to hone practical skills among neurosurgical trainees.¹ These have been conducted mainly in high income countries like the United States² and Canada³ due to the cost of the mannequins, models, and simulators that were

used, as well as the cost involved in the organization of the events. Recently, boot camps have also been successfully implemented in lower income countries through partnership and collaboration.^{4,5} However, these activities involved the international transport of manpower, models, and equipment, which in themselves have substantial cost.⁴ The travel restrictions and transport difficulties caused by the coronavirus-19 (COVID-19) pandemic have presented additional hurdles in conducting collaborative boot camps.⁶

In the absence of models for neurosurgical skills training, some innovative investigators made use of appropriate surrogates in the form of inexpensive, readily available materials such as modeling clay, gelatin, and fruits.⁷⁻⁹ Due to their availability and lower cost, fruits have often been utilized as substitutes for 3D models and cadavers.¹⁰ Citrus fruits, in particular, have proven to be the most versatile, having been used as models for tumor excision, microvascular anastomosis, and microdissection,^{9,10} skills that are taught to more senior neurosurgical trainees. For junior trainees, useful practical skills include head clamp application, suturing, and ventriculostomy. Being presented is the feasibility of using tropical fruits as models for basic neurosurgical skills training for the junior trainee as a “proof of concept” study, and as part of a local neurosurgical boot camp conducted in the Philippines. The use of fruits in an organized neurosurgical boot camp with faculty supervision has not yet been described in the literature, with most papers describing individual skills training during the trainees’ own time.

Methods

The first basic neurosurgical skills boot camp in the Philippines was held at a local neurosurgical training institution with 8 resident participants and 5 faculty neurosurgeons serving as instructors. The curriculum included practical skills such as patient positioning, incision planning, head clamp application, scalp and dural suturing, and ventriculostomy. A male resident was used as a model for patient positioning, and a skull from the anatomy laboratory was used to teach incision planning. Different tropical fruits were used as models for head clamp application, scalp and dural suturing, and ventriculostomy. The practical skills and fruit models developed for use in the boot camp were conceptualized by 2 faculty neurosurgeons and the chief resident, and the models were tested by 2 other faculty and a senior resident one week prior to the activity.

The coconut was used as a surrogate for the skull during head clamping. Eyes, ears, and a nose were drawn on each coconut with a marking pen to simulate the areas to avoid while applying the head clamp. (Figure 1) The pomelo, a local citrus fruit, was used as a model for scalp and dural suturing. Its thick rind simulated the scalp while its inner membrane simulated the dura. (Figure 2) Meanwhile, the watermelon was used for modeling the trajectory of a frontal ventriculostomy tract. This fruit has varying sizes but we selected the ones that are

about the same size as an adult head. A nose, eyes, and ears were drawn on each watermelon using the midline on the sagittal plane as a marker for the nose and eyes (medial canthi), and a point along the axial plane in line with the eyes and located midway between the front and middle of the fruit in the sagittal plane to mark the ear (external auditory canal). The intersection between the ipsilateral medial canthus and external auditory meatus was approximated using thin wooden sticks inserted through these points. The watermelon was then cut axially along this plane, and the intersection point marked with a coin. The sliced watermelon was reassembled, and a “burr hole” was made in the frontal area simulating Kocher’s point. Participants inserted a thin wooden stick with the same diameter as a ventriculostomy tube into the burr hole to simulate ventriculostomy, with the goal of touching the coin. Real-time feedback on the trajectory was possible by reviewing the axial cut through the watermelon. (Figure 3)

After the boot camp, the chief resident conducted a brief interview with all the residents regarding their feedback for the boot camp in general and the fruit models in particular. The questions dealt with assessing the usefulness of the bootcamp, identifying the strengths and weaknesses of the activity, and comparing the similarities of the skills exercises with the actual procedures. A follow-up interview was done with the same questions 6 months after the boot camp, by which time the junior




Figure 1. (A) Diagram of a coconut showing the hard outer shell and thick husk; (B) Head clamp applied to a coconut; (C) Faculty demonstrating head clamp application on a coconut to a junior trainee.

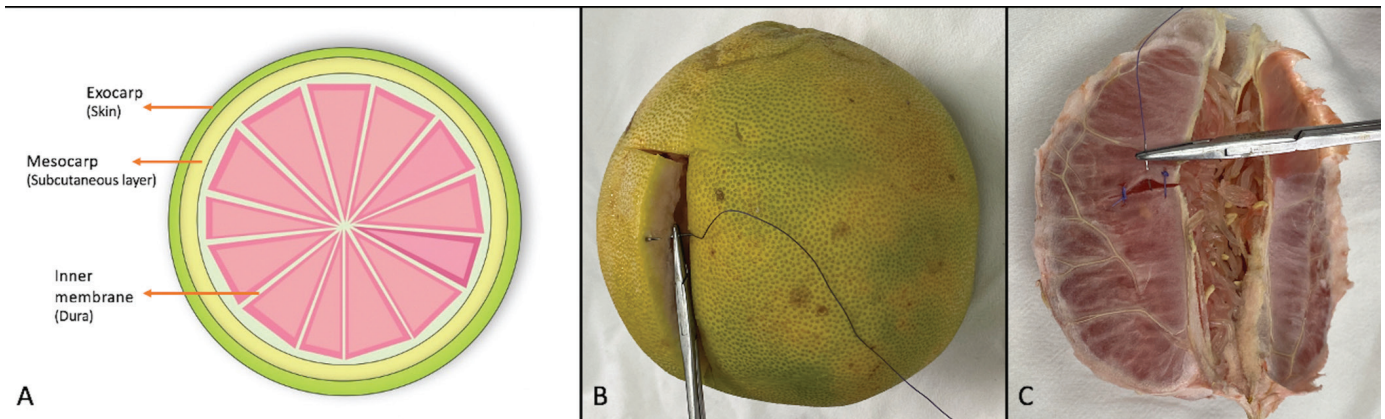


Figure 2. (A) Diagram of a pomelo showing the exocarp and mesocarp as surrogates for scalp and subcutaneous tissue suturing, and the inner membrane for dural suturing; (B) Demonstration of scalp and subcutaneous tissue suturing across the layers of the pomelo rind; (C) Demonstration of inner membrane suturing, noting its dura-like consistency and its proximity to the juicy pulp.

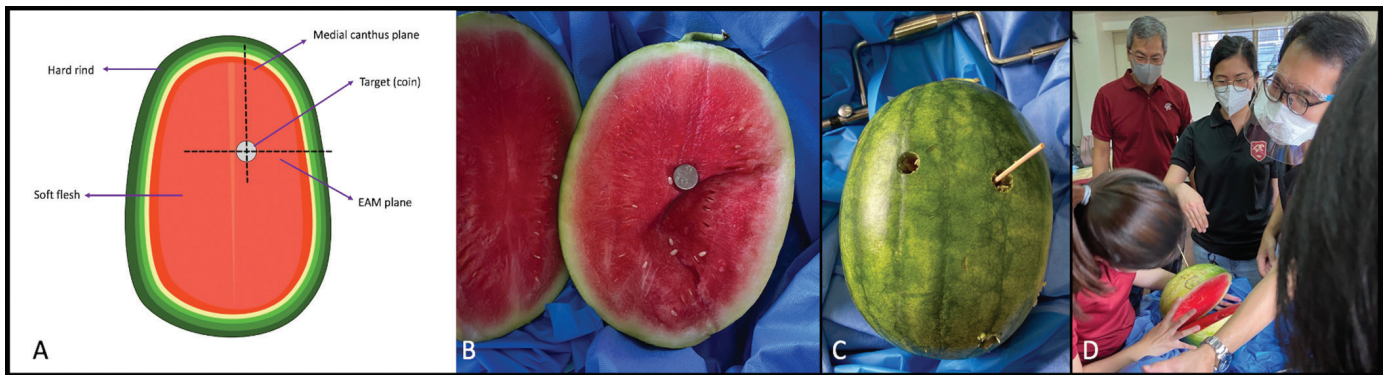


Figure 3. (A) Diagram of a watermelon, with the axes of the medial canthus and external auditory meatus (EAM) marked with a dashed and solid line, respectively, and with the target at the intersection of the two lines; (B) Demonstration of the tangible target (coin) on an axially cut watermelon; (C) Burr holes created on the outer surface of the watermelon; (D) Real-time inspection of the trajectory was made possible by the axially cut watermelon, as demonstrated here.

residents have already performed more procedures and gained more practical experience in the operating room. (Table 1)

Results

Eight neurosurgical residents participated in the boot camp and tested the tropical fruits as models for skills training. There were 3 senior and 5 junior residents.

All junior residents thought that the boot camp was useful in learning new skills and that they would like to participate again in the future. For senior residents, they found that the skills being taught were ones that they have already gained. The strengths of the boot camp included the availability of faculty, the informal and stress-free environment that made it conducive to learning and asking questions, and the ability to practice maneuvers repeatedly without any consequences.

Table 1. Summarized resident interview results immediately after the boot camp and 6 months after.

	Immediately after	6 months after
How useful was the boot camp to your neurosurgical training?	<p>JR: Very helpful in familiarizing with the hand movements; new skills and concepts learned</p> <p>SR: Not that helpful; skills have already been learned</p>	<p>JR: It gave us confidence in suturing the skin and clamping the head; we have not tried ventriculostomy</p> <p>SR: Not that helpful</p>
What were the strengths of the boot camp?	<p>JR: The fruits were able to convey a general sense of the skill needed; coconut made it possible to try clamping; no consequence if you make a mistake; consultant staff was readily available and helpful; atmosphere was light; easy to ask questions</p> <p>SR: Atmosphere was light; fruits were somewhat able to mimic the skill being practiced, particularly the pomelo; watermelon provided real-time feedback for a “blind” procedure</p>	<p>JR: Good beginning to learning more skills</p> <p>SR: Good bonding activity</p>
What were the weaknesses of the boot camp?	<p>JR: The fruits kept on rolling</p> <p>SR: The fruits were not the real thing; more useful for junior residents; no exercises for senior residents</p>	<p>JR: The exercises were not that similar to the real thing</p> <p>SR: Fruits are not the real thing</p>
How similar were the exercises to the actual operative skills?	<p>JR: Pomelo was the most similar to suturing dura and soft tissues</p> <p>SR: Not very similar, but they provided a general guide on how to conduct the procedure</p>	<p>JR: Not that similar; pomelo was the most similar</p> <p>SR: Not very similar</p>
Would you recommend holding the boot camp again in the future?	<p>JR: Yes, it helped us learn new skills and knowledge</p> <p>SR: Yes, it provided a good bonding activity for the team</p>	<p>JR: Yes, at the start of the year would be the best time</p> <p>SR: Yes, they are helpful to the juniors, they seem more confident after the boot camp</p>

*JR - Junior residents; SR - Senior residents

With regard to the fruit models, the coconut was felt to be very similar to a human head, and the exercise of clamping the coconut allowed the junior residents to gauge the strength needed and provided valuable tactile feedback. The pomelo was a good model for suturing because the rind was sturdy enough to be sutured and the membrane resembled dura mater. Meanwhile, the watermelon ventriculostomy model provided real-time feedback in terms of the trajectory. One disadvantage was that the fruits were round and had a tendency to roll, so they had to be held in place. In general, the junior residents found the fruit models to be more useful as teaching material, compared to the senior residents.

In the interview conducted 6 months after the boot camp, junior residents reported that their boot camp experience gave them more confidence in performing the skills needed in the operating room. For senior residents, the boot camp was lauded more as a bonding activity for the team rather than skill building, since they were already familiar with these skills. Both junior and senior residents agreed that the fruit exercises were not that similar to real world practice, but they served as a good place to begin skills training. Thus, all residents recommended continuing the activity, particularly at the start of the academic year. A summary of the questions and interview responses are in Table 1.

Discussion

Neurosurgical boot camps allow trainees to practice useful skills in a risk-free environment, but skills training does not have to be costly or require sophisticated technology. During the boot camp, the authors have demonstrated the novel use of various tropical fruits as readily available, low-cost surrogate models for basic skills training for junior neurosurgical trainees.

Coconut as a model for head clamp application

The coconut (*Cocos nucifera*) was used as a surrogate for the head or skull during head clamping, since the mature fruit has about the same size and shape as an adult head. It consists of a tough outer shell (exocarp)

and a fibrous husk (mesocarp and endocarp) with a hollow center lined by soft meat (endosperm) and coconut water,¹¹ and approximates the calvarium which encases the brain and cerebrospinal fluid. The coconut husk fibers are densely packed, and together with the tough outer shell, creates a hard, compact layer that is more than 3 cm thick,¹¹ which should be able to withstand the pressure applied by the head pins and head clamp. The pins of the head clamp are meant to be embedded in the exocarp-mesocarp layer, and not the deeper endocarp layer encasing the coconut meat. The coconuts were able to tolerate the application of 60 pounds of force without fracturing the outer shell, which is the amount of force usually needed to clamp an adult skull.¹² The tactile experience of applying a head clamp is very important for junior trainees in order to avoid the morbidities associated with it, such as pin-site epidural hematomas.¹²

Other researchers have also used the coconut as a model for simulating a craniotomy, as the relationship and texture difference between the tough shell and soft meat were analogous to bone and dura, and the coconut water simulated cerebrospinal fluid.¹³

Pomelo as a model for scalp and dural suturing

The pomelo (*Citrus grandis*) was used as a model for scalp and dural suturing. The rind is usually 1-2 cm thick and has distinct layers, the outer yellow exocarp and inner white mesocarp.¹⁴ These are analogous to the skin (exocarp), subcutaneous layer (white mesocarp), and galea aponeurotica (inner mesocarp). The juicy pulp is encased and separated by membranes that have a consistency and thickness similar to dura mater.

Citrus fruits such as oranges and grapefruit have been widely used in neurosurgical skills training, particularly in the acquisition of microsurgical skills.^{9,10,15} The pomelo, a large, locally grown citrus fruit, was used as a model for practicing gross suturing skills for junior trainees. The rind served as the “scalp,” the membranes served as the “dura,” and the juicy pulp served as the “brain”. The pomelo rind was sturdy enough to withstand suturing using a round needle, but not a cutting needle, so the former was used. Meanwhile, a small round needle was used to suture the inner membrane (“dura”), taking care

not to lacerate the membrane and to avoid injuring the fruit pulp underneath (“brain”), which would manifest as pomelo juice flowing out. Similar to dura, the inner membrane also became dry when it was exposed to air without being irrigated.

The importance of these suturing skills cannot be overemphasized, since unskillful suturing of the skin and soft tissues may lead to wound dehiscence and soft tissue hematomas, while poor dural suturing may lead to inadvertent parenchymal laceration or cerebrospinal fluid leak.^{16,17}

Watermelon as a model for ventriculostomy trajectory

The watermelon (*Citrullus lanatus*) was used for modeling the trajectory of a frontal ventriculostomy tract. It has a thick, hard rind encasing the soft, juicy flesh whose composition is 92% water.¹⁸ The consistency of the watermelon flesh may not be similar to brain parenchyma, but the shape of the fruit resembles the head, and the contrast between the hard rind and the soft flesh mimics the contrast between the bony skull and the soft depths of the brain parenchyma through which the ventriculostomy tube passes through.

Although ventriculostomy may be performed using other points, the frontal Kocher’s point is the one that affords the greatest degree of freedom; hence, it was deemed the most useful for a junior trainee to learn.¹⁹ The target is described as the intersection of the ipsilateral medial canthus and external auditory meatus,²⁰ and this was simulated by using a coin as a tangible target. The main advantage of this model was the ability to provide real-time feedback to the trainee -- both the tactile feedback from the metal coin and the visual feedback from the axially sliced watermelon when checking the tract where the stick went through. In the real world, cranial imaging would be needed to confirm the track of the catheter and accuracy of placement.^{19,20} Although the tactile sensation was not similar to the “pop” of cannulating a ventricle, the importance of this exercise lies in practicing hand movements and acquired knowledge of the trajectory.¹⁹ Greater familiarity with ventriculostomy may lead to increased accuracy and decreased risk of damage to adjacent structures such as the caudate and thalamus.²⁰

The advantages of tropical fruits as models

Neurosurgical trainees in a resource-limited setting have to find alternative ways to develop their skills, and one of the options is the use of tropical fruits. There are several advantages, of which first and foremost is the price. A coconut costs approximately PHP 40 (USD 0.80);²¹ a pomelo, PHP 150 (USD 3);²¹ and a watermelon, PHP 200 (USD 4);²¹ making these surrogate models very affordable. In comparison, the cost of conducting a boot camp in Myanmar in 2018 was USD 40,000.⁴ Local fruits are also available year-round, since the climate in a tropical country like the Philippines varies very little throughout the year. The fruits were portable, especially the pomelo, allowing the trainees to perform the exercises in their own place and time. Furthermore, the use of tropical fruits for skills training is readily reproducible, especially in other low- and middle-income countries (LMICs) that have similar climate and vegetation as the Philippines. Using local produce is also a sustainable practice.

An unexpected advantage of using tropical fruits during the boot camp was the fun and lighthearted atmosphere it created. The light atmosphere allowed the junior residents to interact with the faculty in a less formal manner, which was different from the usual work-related interactions.²² An informal learning environment encourages trainees to ask more questions, which leads to improved retention of learning points.²³

Limitations and areas for improvement

This study has several limitations and areas for improvement. First, the fruits were not exact replicas of their surrogates, and were simply used as models on which to practice the desired skills. Second, they were not reusable and had to be discarded after use, contributing to food waste. Third, the selected fruits were round, so there was difficulty in stabilizing them during the exercises. The authors would have to find ways to immobilize them during use. Fourth, they have missed the opportunity to use a coconut for burrhole and craniotome practice as described by Drummond-Braga and colleagues,¹³ because their institution does not have a skills laboratory with an outlet for a pneumatic

craniotome. Furthermore, they have a limited number of Hudson Brace drills and craniotomes, and they are reserved for patient use, not for research or skills practice. Fifth, additional skills exercises can be added to address the needs of the senior trainees. What could have been improved was the segregation of activities according to year level, as well as the addition of skills exercises designed for senior trainees since they were already familiar with the ones that were taught during the boot camp. Sixth, our method of checking for face validity was crude. Lastly, this activity was a “proof of concept” feasibility study, and the authors did not investigate whether it would translate into better neurosurgical skills in the operating room setting.

Conclusion

The use of tropical fruits as surrogate models in basic neurosurgical skills training was a feasible and affordable alternative in LMICs like the Philippines, although the activity was perceived to be more useful to junior than to senior residents. An additional advantage was the informal atmosphere generated by the use of the fruits, contributing to an improved learning experience for the trainee.

Acknowledgements

The authors would like to thank Drs. Kenny Seng, Ronnie Baticulon, Alaric Salonga, Miriam Dy, and Diana Sanchez for their help in conducting the neurosurgical boot camp.

Conflict of Interest

None of the authors have any conflicts of interest to disclose

Funding Sources

None

References

1. Selden NR, Origitano TC, Burchiel KJ, et al. A national fundamentals curriculum for neurosurgery PGY1 residents: The 2010 Society of Neurological Surgeons boot camp courses. *Neurosurg* 2012;70(4):971-81. doi:10.1227/NEU.0b013e31823d7a45
2. Selden NR, Anderson VC, McCartney S, Origitano TC, Burchiel KJ, Barbaro NM. Society of Neurological Surgeons boot camp courses: Knowledge retention and relevance of hands-on learning after 6 months of postgraduate year 1 training. *J Neurosurg* 2013;119(3):796-802. doi:10.3171/2013.3.JNS122114
3. Haji FA, Clarke DB, Matte MC, et al. Teaching for the transition: The Canadian PGY-1 neurosurgery “rookie camp.” *Can J Neurol Sci* 2015; 42(1): 25-33. doi:10.1017/cjn.2014.124
4. Rock J, Glick R, Germano IM, et al. The First Neurosurgery Boot Camp in Southeast Asia: Evaluating impact on knowledge and regional collaboration in Yangon, Myanmar. *World Neurosurg* 2018; 113:e239-46. doi:10.1016/j.wneu.2018.02.001
5. Ament JD, Kim T, Gold-Markel J, et al. Planning and executing the Neurosurgery Boot Camp: The Bolivia experience. *World Neurosurg* 2017;104: 407-10. doi:10.1016/j.wneu.2017.05.046
6. Kanmounye US, Ammar A, Esene I, El Ouahabi A, Park K. Letter to the Editor: COVID-19 & neurosurgical training in low- and middle-income countries. *World Neurosurg* 2020; 142: 566-8. doi:10.1016/j.wneu.2020.07.018
7. Eftekhari B, Ghodsi M, Ketabchi E, Ghazvini AR. Play dough as an educational tool for visualization of complicated cerebral aneurysm anatomy. *BMC Med Educ* 2005; 5: 1-4. doi:10.1186/1472-6920-5-15
8. Mashiko T, Oguma H, Konno T, et al. Training of intra-axial brain tumor resection using a self-made simple device with agar and gelatin. *World Neurosurg* 2018;109:e298-e304. doi:10.1016/j.wneu.2017.09.162
9. Doron O, Paldor I, Moscovisci S, et al. Acquisition of basic microsurgical skills using low-cost, readily available models: The orange model. *World Neurosurg* 2021; 146: 189-96. doi:10.1016/j.wneu.2020.11.060
10. Cikla U, Rowley P, Jennings Simoes EL, et al. Grapefruit training model for distal anterior cerebral artery side-to-side bypass. *World Neurosurg* 2020; 138: 39-51. doi:10.1016/j.wneu.2020.02.107
11. DebMandal M, Mandal S. Coconut (*Cocos nucifera* L. Arecaceae): In health promotion and disease prevention. *Asian Pac J Trop Med* 2011; 4(3): 241-7. doi:10.1016/S1995-7645(11)60078-3
12. Thijs D, Menovsky T. The Mayfield skull clamp: A literature review of its complications and technical nuances for application. *World Neurosurg* 2021;(May):1-8. doi:10.1016/j.wneu.2021.04.081
13. Drummond-Braga B, Peleja SB, Macedo G, et al. Coconut model for learning first steps of craniotomy techniques and cerebrospinal fluid leak avoidance. *World Neurosurg* 2016; 96: 191-4. doi:10.1016/j.wneu.2016.08.118

14. Tocmo R, Pena-Fronteras J, Calumba KF, Mendoza M, Johnson JJ. Valorization of pomelo (*Citrus grandis* Osbeck) peel: A review of current utilization, phytochemistry, bioactivities, and mechanisms of action. *Compr Rev Food Sci Food Saf* 2020;19(4):1969-2012. doi:10.1111/1541-4337.12561
15. Kumaresan R, Karthikeyan P. An inexpensive suturing training model. *J Maxillofac Oral Surg* 2014; 13(4): 609-11. doi:10.1007/s12663-013-0546-z
16. Ogunbo BI, Nath FP. A technique for dural repair following retromastoid suboccipital craniectomy. *Br J Neurosurg* 1998; 12(1): 45-6. doi:10.1080/02688699845519
17. Chughtai KA, Nemer OP, Kessler AT, Bhatt AA. Post-operative complications of craniotomy and craniectomy. *Emerg Radiol* 2019; 26(1): 99-107. doi:10.1007/s10140-018-1647-2
18. Manivannan A, Lee ES, Han K, Lee HE, Kim DS. Versatile nutraceutical potentials of watermelon-A modest fruit loaded with pharmaceutically valuable phytochemicals. *Molecules* 2020; 25(22): 1-15. doi:10.3390/molecules25225258
19. Fichtner J, Raabe A, Gralla J, Beck J, Raabe C. Revisiting the rules for freehand ventriculostomy: a virtual reality analysis. *J Neurosurg* 2017: 1250-7. doi:10.3171/2016.11.jns161765
20. Robertson FC, Abd-El-Barr MM, Mukundan S, Gormley WB. Ventriculostomy-associated hemorrhage: a risk assessment by radiographic simulation. *J Neurosurg* 2017; 127(3): 532-6. doi:10.3171/2016.8.JNS16538
21. World Bank. World Development Indicators: Exchange rates and prices. <http://wdi.worldbank.org/table/4.16>. Published 2021. Accessed May 19, 2021.
22. Majmundar N, Graffeo CS, Johnson JN. Generation Y. Neurosurgery and the millennial moment. *World Neurosurg* 2021; 149: 8-10. doi:10.1016/j.wneu.2021.02.070
23. Louie M, Moulder JK, Wright K, Siedhoff M. Mentoring millennials in surgical education. *Curr Opin Obstet Gynecol* 2019; 31(4): 279-84. doi:10.1097/GCO.0000000000000546