

# Retained Placenta Accreta: An Unusual Cause of Abnormal Uterine Bleeding in a Non-gravid Woman

Angela Francesca S. Sese, MD and Ina S. Irabon, MD, FPOGS, FPSRM, FPSGE

Department of Obstetrics and Gynecology, University of Perpetual Help Delta Medical Center Las Pinas

Placenta accreta is one of the most feared complications among gravid women, as it is associated with massive and potentially life-threatening intrapartum and postpartum hemorrhage. Due to its natural history, placenta accreta is only naturally seen or expected as a cause of bleeding only among obstetric patients. This case report describes a rare manifestation of profuse abnormal uterine bleeding secondary to a placenta accreta in a non-gravid patient. The non-pregnant state was evidenced by the absence of history of amenorrhea and pregnancy signs and symptoms, a negative urine pregnancy test and normal serum  $\beta$ hcg results. A diagnosis of placenta accreta was mainly based on a post-hysterectomy histopathological examination. Theoretical explanations to explain this phenomenon is discussed in this case report.

**Keywords:** placenta accreta, abnormal uterine bleeding, non-gravid

## Introduction

In clinical practice, the general term “placenta accreta” is used to describe all 3 grades of abnormal placental attachment. It is basically subclassified into placenta accrete, placenta increta, and placenta percreta based on the depth of penetration of the placental tissue into the uterine wall.<sup>1,2,3</sup> This is a life-threatening obstetric complication and causes 33–50% of all emergency peripartum hysterectomies. Complication of placenta accreta that comes after a remote spontaneous vaginal delivery is extremely rare; however, retained placental tissue and a hematoma can possibly become entrapped in the myometrium.<sup>3</sup> This condition is clinically significant because it can cause not only heavy menstrual bleeding, but can also mimic an unusual uterine mass, as seen in this case report.

This case report describes a very rare case of a multigravid non-pregnant patient who presented with heavy menstrual bleeding and uterine mass, and was diagnosed with placenta accreta after undergoing a hysterectomy. Theoretical explanations on this

phenomenon and possible treatment options are discussed.

## The Case

This is a case of a 33 year old G4P4 (4004), who consulted at the emergency room due to profuse vaginal bleeding. She is a known asthmatic, with irregular intake of maintenance medications. She has a family history of Hypertension, Diabetes Mellitus and Leukemia on maternal side. She is a college undergraduate and works as a salon manager. She is married for 15 years to a 34 year old bartender. She was a previous smoker (3.5 pack years) and occasional alcohol beverage drinker. All her past pregnancies were delivered vaginally with no complications, with her last pregnancy (G4) delivered 2 years prior to this present consult. She reported no episodes of amenorrhea nor missed menses after her last pregnancy.

Twelve days prior to consult, patient noted heavy menstrual bleeding using up 5 fully soaked

pads per day associated with passage of blood clots and mild hypogastric pain radiating to the lower back, occasionally relieved by intake of mefenamic acid. Urine home pregnancy test revealed negative results. No consult done, no medications taken. On the day of consult, patient reported persistence of heavy menstrual bleeding now associated with passage of foul smelling blood clots and dizziness. No passage of meaty materials noted.

At the ER, vital signs were stable. Patient was pale looking and complained of hypogastric pain. Abdomen was soft, flat and nontender. Speculum exam showed a pink and smooth cervix with a 6cm x 3cm violaceous, soft, friable, fleshy mass protruding from the cervical os, with moderate vaginal bleeding (Figure 1).



**Figure 1.** Speculum exam showed pink and smooth cervix with a 6cm x 3cm violaceous, mass protruding from the cervical os, with moderate vaginal bleeding.

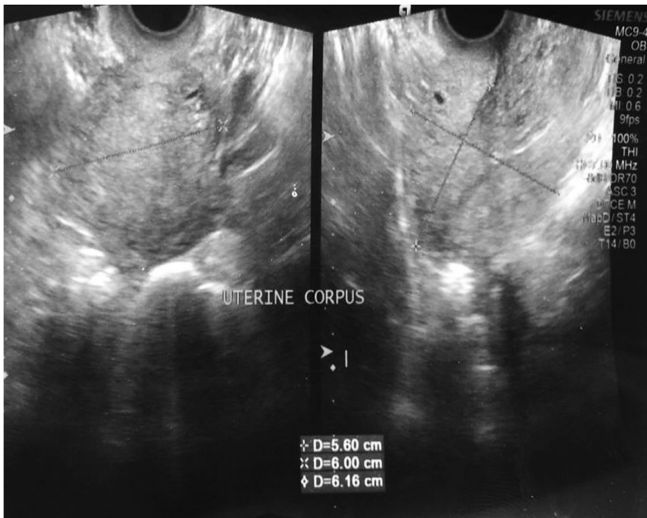
On internal examination, the cervix was dilated by a 6cm x 3cm fleshy mass protruding from the cervical os, broad-based, and attached to the anterior midcorpus. uterus not enlarged, no cervical motion tenderness, no adnexal mass nor tenderness.

Urine pregnancy test revealed a negative result. CBC showed moderate anemia (Hgb 77 mg/dl, Hct 0.26). After doing speculum exam, brisk vaginal bleeding ensued and patient became hypotensive

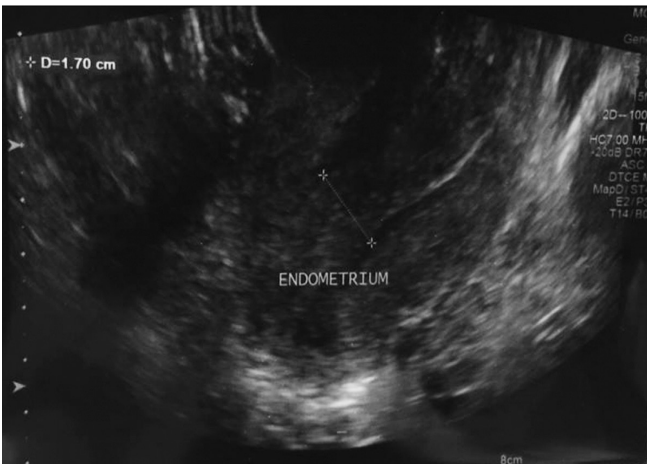
and tachycardic with weak pulses. Venoclysis was started, 200 ml of PNSS was infused as fast drip and the remaining was to run for 6 hours. Voluven was started to provide temporary compensation for the hypotension and decreased hemoglobin level. Impression at this time was Abnormal Uterine Bleeding probably secondary to Endocervical polyp versus prolapsed submucous myoma. Blood transfusion was started with 5 units of packed RBC. When patient was stabilized, transvaginal ultrasound was done which revealed a smooth walled heterogenous mass dilating the endocervical cavity and extending into the endometrial cavity, approximately measuring 7.5cm x 3.1cm x 3.1cm. There was a broad-based stalk which measured approximately 1.5 cm and was attached to the anterior midcorpus. The endocervical mass was avascular on color flow. The endometrium was thickened (1.70cm). The uterine corpus measured 3.60cm x 6.0cm x 6.16cm. The cervix and ovaries were all normal. Sonographic impression at this time was an endocervical – endometrial mass, consider prolapsed submucous myoma (Figures 2-4)

Patient underwent exploratory laparotomy, total hysterectomy with bilateral salpingectomy. Upon exploration, uterus was grossly normal, smooth-walled and pink measuring 7cm x 7cm x 3cm (Figure 5). On cut section, the stalk of the mass was noted at the midcorpus with a base measuring 1.5 cm adherent to the myometrium. The anterior myometrium measures 2.5cm (Figure 6). The right and left fallopian tubes appeared normal and was not dilated measuring 7cm x 1cm and 5cm x 1cm, respectively (Figure 7,8). The mass protruding from the cervical os measured 7cm x 3cm x 2.5 cm, soft, violaceous, necrotic, non-foul smelling (Figure 9) was extracted from the vagina. The specimen was sent for histopathology. Procedure was tolerated well by the patient. Patient was then discharged 3 days post-op.

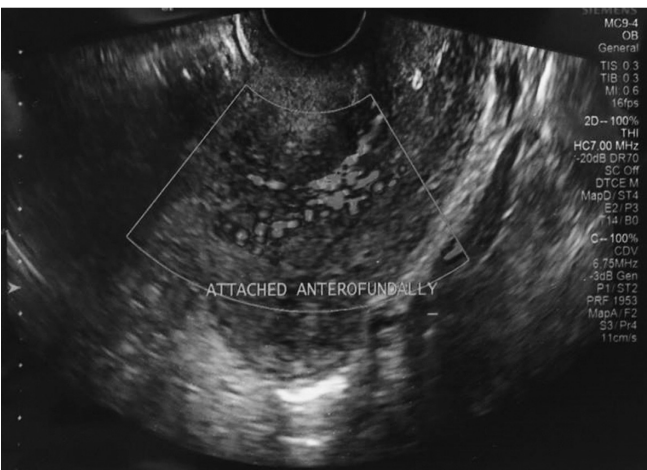
The histopathology result (Figure 10) revealed the following: Degenerated immature placental tissues and hemorrhages (Placenta Accreta). Chronic cervicitis. Secretory endometrium. No diagnostic abnormality recognized on both fallopian tubes. The medical team then decided to do a serum  $\beta$ -hcg on post-operative day 3 to confirm pregnancy of the patient. However, serum  $\beta$ -hcg revealed normal results (<2 mIU/ml).



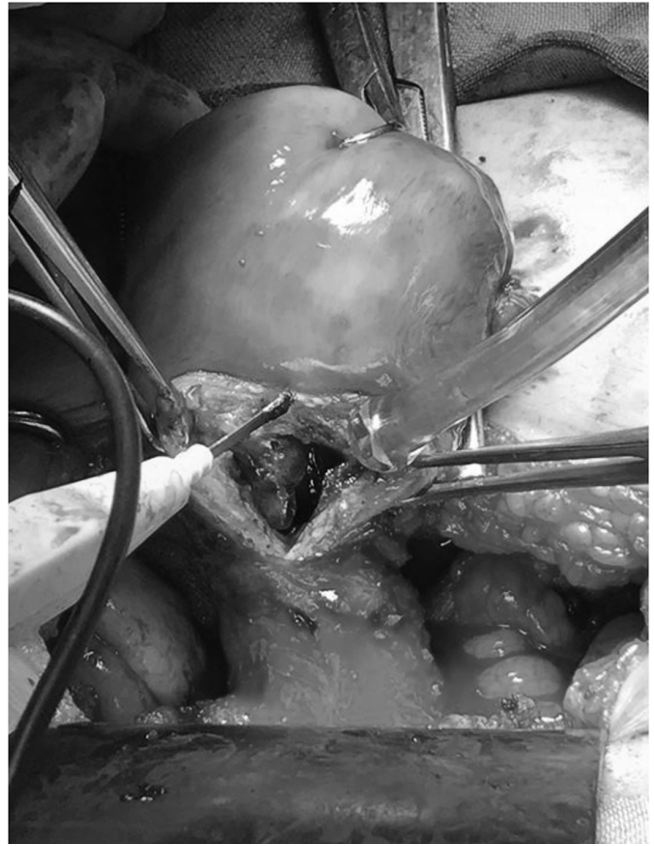**Figure 2.** The uterine corpus measured 3.60cm x 6.0cm x 6.16cm. The cervix and ovaries were all normal.



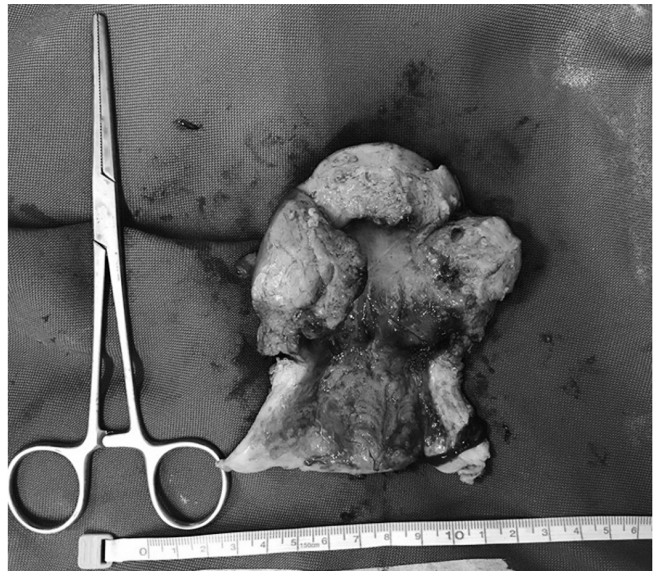**Figure 3.** The endometrium was thickened (1.70cm).



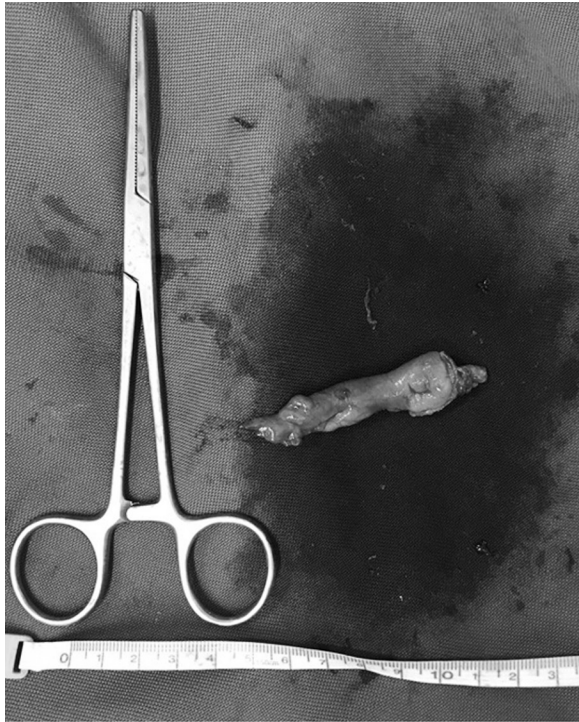**Figure 4.** The endocervical mass was avascular on color flow.



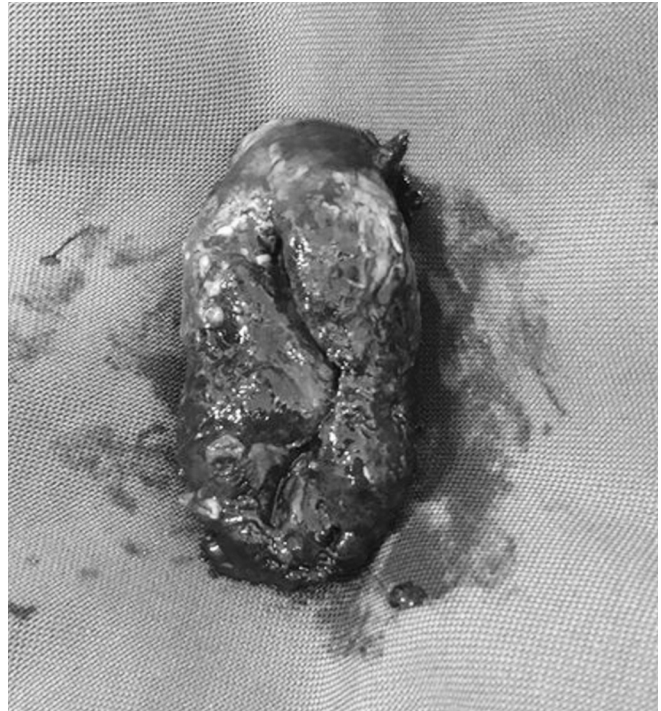**Figure 5.** On exploration, the uterus was grossly normal, smooth – walled and pink measuring 7cm x 7cm x 3cm. Incision was made on the anterior midcorpus.



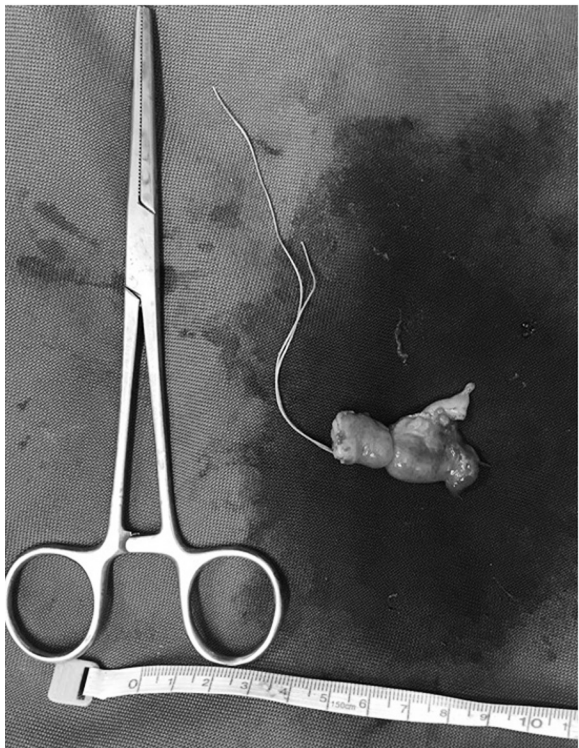**Figure 6.** On cut section, the stalk of the mass was noted at the right upper anterior endocervical canal with a base measuring 1.5 cm.



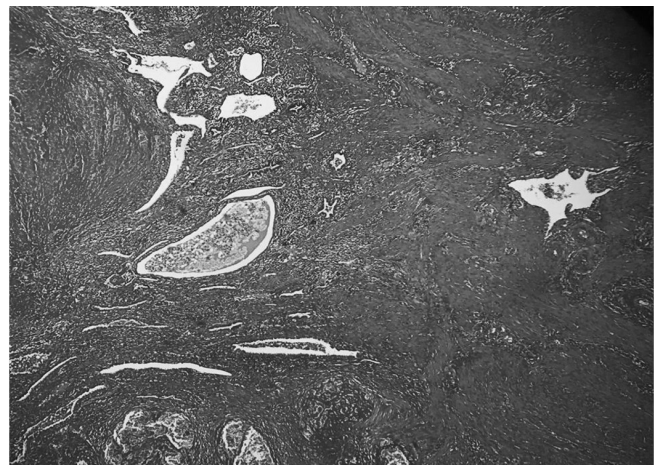**Figure 7.** The left fallopian tube was non – dilated, measuring 5cm x 1cm.



**Figure 9.** The mass protruding from the cervical os measured 7cm x3cm x 2.5cm, soft, violaceous, necrotic.



**Figure 8.** The right fallopian tube was non – dilated, measuring 7cm x 1cm.



**Figure 10.** On the right area is the myometrial layer of the uterus. On the left area is the placental tissues

## Discussion

Placenta accreta is one of the most feared complications among gravid women, as it is associated with massive and potentially life-threatening intrapartum and postpartum

hemorrhage. It primarily occurs when the placenta is abnormally adherent to the uterus, and is thought to be due to the partial or total absence of the decidua basalis and imperfect development of the fibrinoid or Nitabuch layer and the histology correspondingly shows the trophoblast invasion into the myometrium without intervening decidua.<sup>4</sup>

Due to its natural history, placenta accreta is naturally only seen or expected as a cause of bleeding only among obstetric patients. Clinically, patients with risk factors (especially both previous cesarean sections and placenta previa) are usually suspected for diagnosis antenatally. High maternal age, multiparity, myometrial damage (myomectomy, curettage, Asherman's syndrome, and endometrial ablation), and uterine artery embolization constitute as the other risk factors for placenta accreta. Most placenta accretas show clinical manifestations, such as bleeding, uterine rupture, invasion of the bladder, and uterine inversion. Placenta accreta usually presents with vaginal bleeding during difficult placental removal in the third trimester.<sup>3</sup>

This case however, is a rare manifestation of abnormal uterine bleeding secondary to a placenta accreta in a non-gravid patient. The non-pregnant state was evidenced by the absence of history of amenorrhea, pregnancy signs and symptoms, a negative urine pregnancy test and normal serum  $\beta$ hcg results. A diagnosis of placenta accrete was mainly based on a post-hysterectomy histopathological examination. Logically, placenta accreta was never a consideration as a differential diagnosis for this case.

So how do we now explain this phenomenon of abnormal uterine bleeding secondary to a placenta accreta in a non-gravid patient? Several theoretical explanations may help explain this occurrence:

One theory that may explain this phenomenon is retained abnormally adherent placental fragments from her last pregnancy in 2016. Another possible explanation would be retained abnormally adherent placental accessory lobe or placental polyps. These placental structures may have possibly underwent spontaneous involution and necrosis over time. What is interesting to note is that these "retained placental tissues" never manifested as abnormal uterine bleeding immediately, or even remotely, postpartum. It was only after 2 long years, presumably after it has

involved and necrosed, that it revealed its presence as acute profuse vaginal bleeding.

Three similar case reports<sup>4,5,6</sup> described a case of placenta increta that caused prolonged bleeding after a remote first trimester abortion, and was identified by imaging studies as a heterogenous mass in the myometrium. The major difference with this report's index patient however, is that these were cases of persistent hemorrhage following a first trimester abortion. The index patient on the other hand was asymptomatic from her last pregnancy, and had no episodes of heavy menstrual bleeding between her last pregnancy and the time her symptoms started.

Were there any risk factors in the patient to suspect placenta accreta? The only documented risk factor would be multiparity (G3P3). The patient had no classic risk factors such as a history of uterine surgery (previous cesarean section or dilatation and curettage) or advanced maternal age.

The patient underwent total hysterectomy mainly because of the preoperative gynecologic diagnosis of a prolapsed submucous myoma causing heavy menstrual bleeding. Since she presented with a first-episode of acute profuse vaginal bleeding associated with a 6cm prolapsed uterine mass, a uterine myoma with degeneration was the initial impression. It was largely astonishing for the surgeons to be informed of the post-operative histopathologic diagnosis of accreta, given the history and laboratory results of the patient.

Had this case been preoperatively assessed as a case of placenta accreta on ultrasound, then we may have contemplated various methods of managing placenta accreta, ranging from conservative methods to extirpative management, depending on the patient's preference, and desire for future reproduction.

There has been a paradigm shift in terms of treatment, from the historical cesarean hysterectomy to more conservative methods of management involving surgical methods for uterine conservation and leaving the remaining placenta in situ with adjuvant treatment of methotrexate in some cases, or simply awaiting spontaneous resorption of the remaining embedded placental tissues.<sup>7</sup> The paradigm shift is facilitated by the development of methods of controlling blood loss during surgery, such as embolization, ligation or balloon occlusion of the arterial supplies, as well as the enhanced

availability and safety of blood transfusions, either from autologous or donor sources, and good modern intensive care support.<sup>8</sup>

## References

1. Wu S, Kocherginsky M and Hibbard JU. Abnormal placentation: twenty-year analysis. *Am J Obstet Gynecol* 2005; 192(5): 1458–61.
2. Miller DA, Chollet JA and Goodwin TM. Clinical risk factors for placenta previa-placenta accreta. *Am J Obstet Gynecol* 1997; 177(1): 210–4.
3. Lim S, Ha SY, Lee KB, Lee JS. Retained placenta accreta after a first-trimester abortion manifesting as an uterine mass. *Obstet Gynecol Sci* 2013; 56(3): 205-7.
4. Ju W, Kim SC. Placenta increta after first-trimester dilatation and curettage manifesting as an unusual uterine mass: magnetic resonance findings. *Acta Radiol* 2007; 48(8): 938-40.
5. Ju W, Kim SC. Placenta increta after first-trimester dilatation and curettage manifesting as an unusual uterine mass: magnetic resonance findings. *Acta Radiol* 2007; 48(8): 938-40.
6. Harden MA, Walters MD, Valente PT. Postabortal hemorrhage due to placenta increta: a case report. *Obstet Gynecol* 1990; 75(3 Pt 2): 523-6.
7. Hudon L, Belfort MA and Broome DR. Diagnosis and management of placenta percreta: a review. *Obstet Gynecol Surv* 1998; 53(8): 509–17.
8. O'Brien JM, Barton JR and Donaldson ES. The management of placenta percreta: conservative and operative strategies. *Am J Obstet Gynecol* 1996; 175(6): 1632–8.