

Abdominal Wall Reconstruction Using an Anterolateral Thigh Free Flap for a Large Abdominal Wall Defect

Alexandra Monica L. Tan, MD¹; Eric Perpetuo E. Arcilla, MD, FPAPRAS, FPCS¹ and Richard D.L. Quing, MD²

¹Division of Plastic Surgery, Department of Surgery, Philippine General Hospital, University of the Philippines Manila

²Microsurgery Section, Plastic and Reconstructive Surgery, Batangas Medical Center

Objective: To present a complicated case of abdominal wall reconstruction after tumor extirpation using an anterolateral thigh free flap.

Methods: This is a report of a case managed at the Philippine General Hospital last September 2016.

Results: A 25 year-old male, diagnosed case of recurrent colon adenocarcinoma, underwent wide excision of recurrent abdominal wall tumor with fistula, resulting to 15cm x 30cm full thickness soft tissue abdominal wall defect with exposed bowels. A free anterolateral thigh fasciocutaneous flap was designed and elevated to cover the abdominal wall defect. Recipient vessels (contralateral deep inferior epigastric artery and veins) were anastomosed with donor vessels (descending branch of lateral circumflex femoral artery and veins). The donor site was closed with split thickness skin grafting.

Conclusion: The free anterolateral thigh flap allows for coverage of complicated recurrent abdominal wall malignancies, allowing for a single-stage surgery, with little donor site morbidity and shorter hospital stay.

Key words: free tissue transfer flap, microsurgical free flap

The Case

The patient is a 25 year-old male, who presented with a 6-month history of occasional abdominal pain and decreasing stool caliber. Work-up done at a private hospital revealed a well-differentiated adenocarcinoma of the descending colon. He subsequently underwent left hemicolectomy at a local hospital and advised chemotherapy and radiotherapy but this was initially

deferred due to financial constraints. The patient had a recurrence and again underwent excision of the abdominal wall tumor, adhesiolysis, abdominal wall fascia reconstruction using composite mesh. Despite undergoing chemotherapy (oral capecitabine) and radiotherapy as advised, the patient had multiple recurrences, and subsequently had several excisions done.

The patient again returned to the Philippine General Hospital, that time for a slowly enlarging left lower abdominal wall tumor which eventually developed into a fungating mass. Repeat work-up showed a left lower abdominal wall mass measuring 7.9cm x 6.8cm x 4.0cm, involving the lower rectus abdominis, transverse and oblique muscles, with extension to the right rectus muscle. A fistulous tract was likewise seen on CT-scan, traversing the said mass (Figure 1). The working impression at that time was colon carcinoma with abdominal wall tumor recurrence and an enterocutaneous fistula. An upbuilding diet was initiated and patient was prepared for surgery. The plan of the general surgery service was to do excision of the mass with its fistulous tract. He was then referred to the plastic surgery service for abdominal wall reconstruction post excision.

On physical examination, the patient was generally unremarkable, except for the abdominal exam which showed a 10cm x 12cm left lower quadrant fungating, foul-smelling abdominal wall mass with surrounding erythema and hyperpigmentation, extending to the periumbilical area and flank (Figure 2).

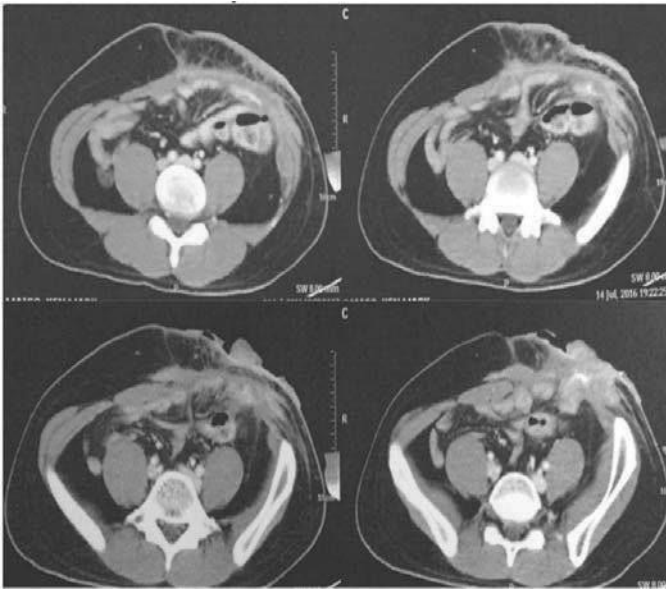


Figure 1. CT scan. Left lower abdominal wall mass (7.9cm x 6.8cm x 4.0cm) involving the lower rectus abdominis, transverse and oblique muscles, with extension to the right rectus muscle; (+) fistulous tract traversing the mass.

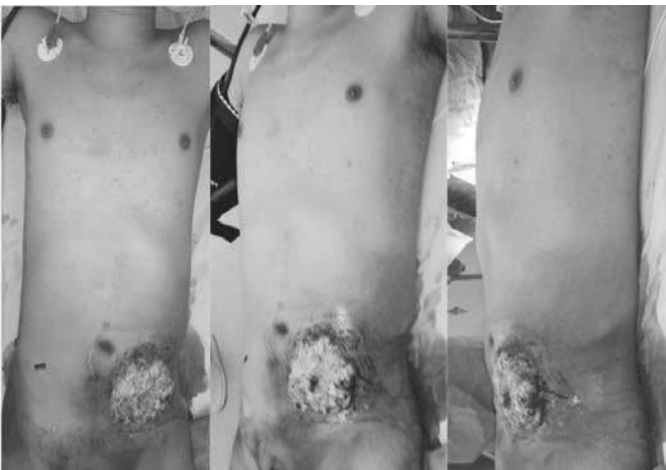

Figure 2. Pre-op. A 10 cm x 12 cm left lower quadrant fungating, foul-smelling abdominal wall mass with surrounding erythema and hyperpigmentation, extending to the periumbilical area and flank.

Operation done last August 2016 was exploratory laparotomy, adhesiolysis, wide excision of recurrent abdominal wall tumor with fistula, stapled segmental jejunal resection-anastomosis, repair of serosal tears, care of the colorectal service. Intra-operatively, there

was note of a bulky abdominal wall tumor adherent to the jejunum at two points with fistula formation. Adhesions were noted at the small bowel, transverse colon and posterior bladder. There were no enlarged nodes, ascites or carcinomatosis. Post-excision, there was note of a 15cm x 30cm anterior rectus fascia defect at the left abdominal wall, with exposed bowels (Figure 3).

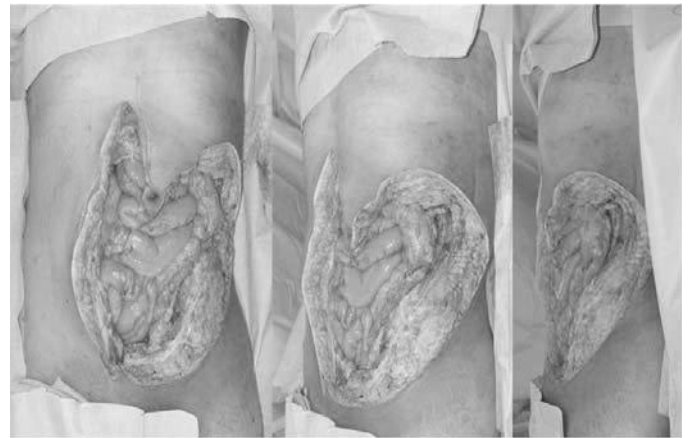

Figure 3. Intra-op. Post-excision, a 15 cm x 30 cm anterior rectus fascia defect at the left abdominal wall, with exposed bowels.

An anterolateral thigh (ALT) free flap measuring 15cm x 30cm was designed and marked on the left thigh (Figure 4). A line joining the anterior superior iliac spine and the upper outer border of the patella corresponds to the intermuscular septum between the rectus femoris and vastus lateralis muscles. At the area of the midpoint of this line lies a perforator / skin vessels that supply the flap.¹ Doppler ultrasound was used to locate the perforators during marking. Musculocutaneous perforators were dissected carefully and preserved (Figure 5). The flap pedicle, from the descending branch of the lateral circumflex, had 1 artery and 2 veins; vessel diameter was 2mm with a pedicle length of 10cm (Figure 6).

The free ALT was anastomosed to the recipient vessels - the deep inferior epigastric artery and veins, using microsurgical technique (Figure 7). A right pedicled rectus abdominis flap swing flap was used to close the epigastric defect, while the ALT fascia was inset and

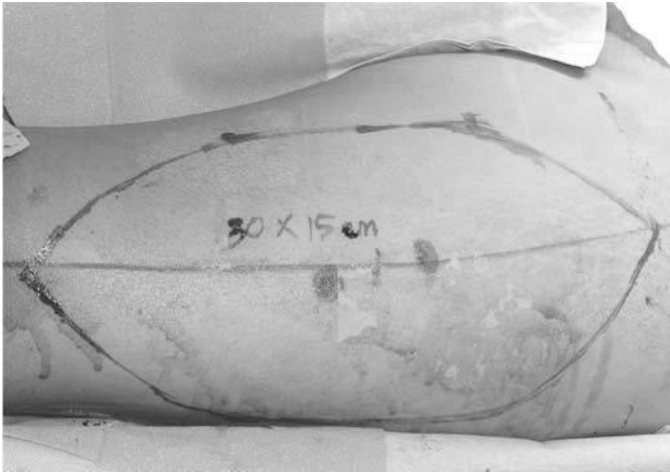

Figure 4. Flap Design. A 15 cm x 30 cm ALT flap design on the left thigh. Blue and red dots signify perforators identified using Doppler ultrasound.

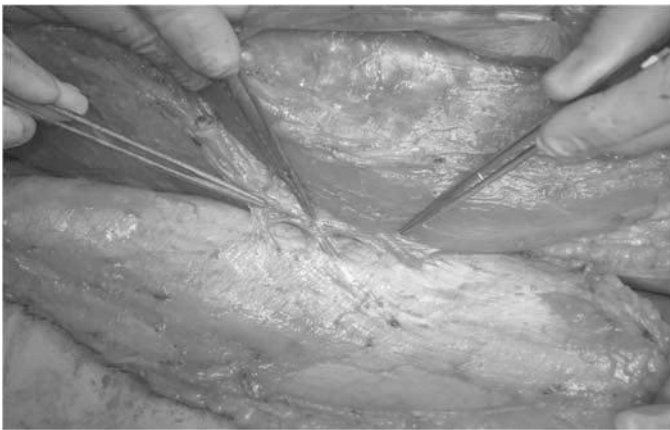


Figure 5. Musculocutaneous perforators identified and preserved (pointed using forceps).

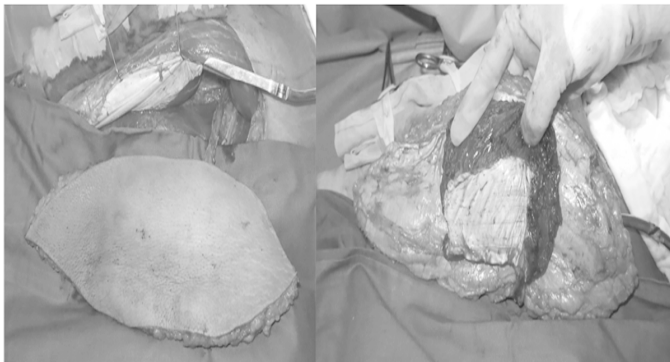


Figure 6. ALT flap and pedicle. A part of the vastus lateralis was harvested to preserve the musculocutaneous perforators.

apposed to the remaining rectus sheath to obtain a water-tight closure (Figure 8). The donor site (right thigh) and part of the left flank and inguinal defect were closed using split thickness skin grafts (Figure 9).




Figure 7. Anastomosis. Recipient vessels (contralateral deep inferior epigastric artery and veins) were anastomosed with donor vessels (descending branch of lateral circumflex femoral artery and veins) using microsurgical technique.

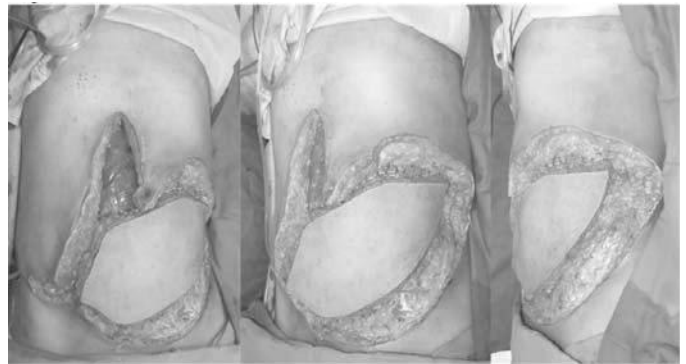

Figure 8. Inset.

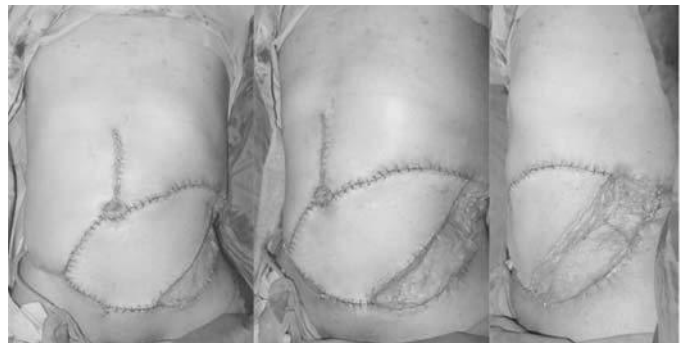


Figure 9. Immediately post-op.

The immediate post-op period was unremarkable, with the patient having acceptable drain and urine outputs. Initially, the patient was kept flat on bed, to avoid kinking of the anastomotic area located near the right hypogastric area. First graft site opening revealed good graft take for both recipient and donor sites (Figure 10). The patient was able to sit up after the second graft site opening. Subsequent wound inspections revealed partial graft loss for the left flank area due to dessication; this was amenable to wound care and the wound eventually closed. (Figure 11).

large full-thickness defect of abdominal wall resection and consequent exposed viscera, there is a need for immediate repair to cover the defect. Abdominal wall reconstruction would entail not only simple wound closure, but would also include returning wall strength to avoid hernia, while concurrently preventing post-operative intra-peritoneal complications.³

Reconstruction of complex anterior abdominal wall defects presents a unique reconstructive challenge to the plastic surgeon. With the various techniques in the plastic surgeon's arsenal, it is possible to reconstruct the entire abdomen safely. The goals for abdominal reconstruction are the restoration of function and integrity of the musculofascial abdominal wall prevention of visceral evisceration and provision of dynamic muscle support. Careful assessment of the defect combined with sound preoperative planning and meticulous surgical execution allows the reconstructive surgeon the ability to close complex abdominal wall defects confidently.^{4,5}

Discussion

Management of tumor lesions in the abdominal wall involves en-bloc resection of the primary neoplasm along with adequate margins, to achieve optimal treatment and minimize tumor recurrence. Due to the resulting

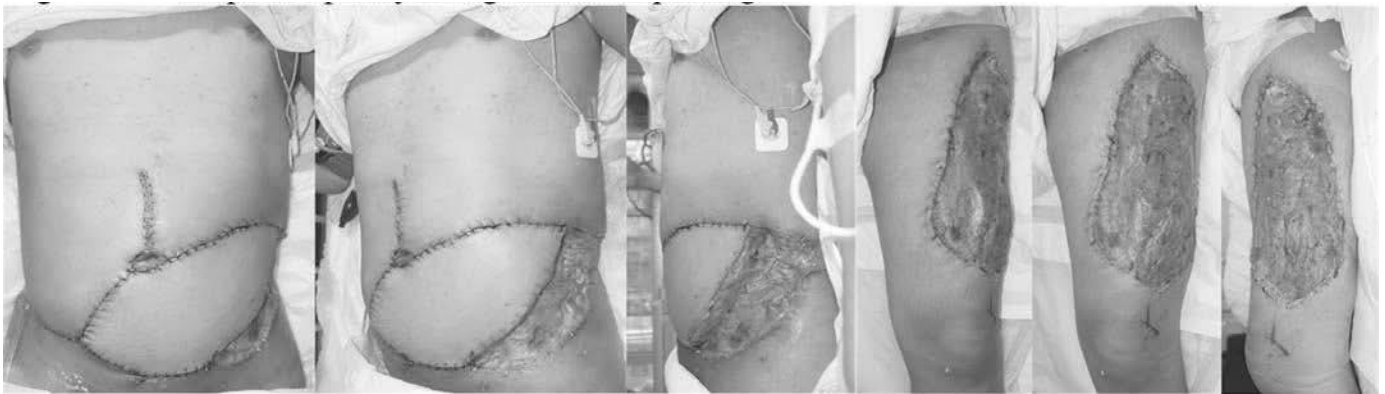


Figure 10. 4th post-op day, 1st graft site opening.

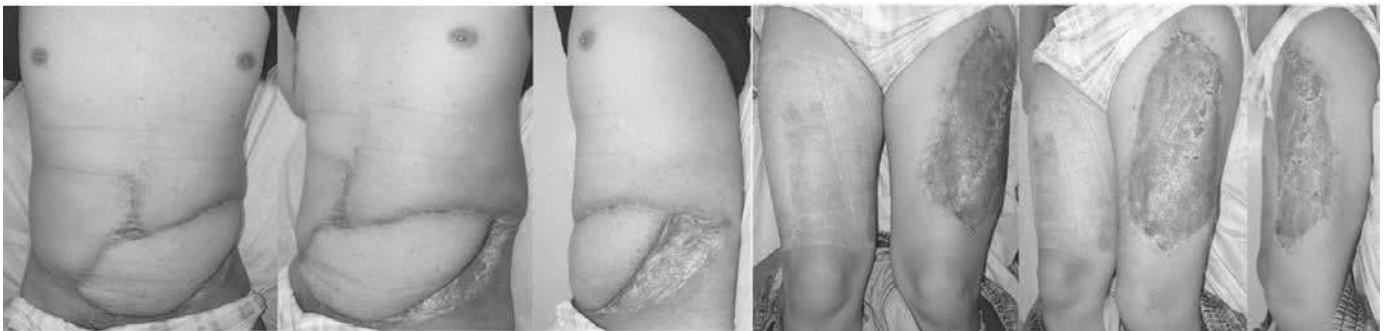

Figure 11. 14th post op day.

Issues that would be relevant to surgical planning would include: pre-operative care and assessment, wound bed evaluation, immediate vs. delayed reconstruction, and incision placement.⁶ Pre-operative assessment necessitates adequate medical and social history such as medication lists (steroid use), tobacco and alcohol abuse. Poor nutritional status contributes to delayed wound healing. The wound bed evaluation is vital to planning; infection, inflammation, previous surgeries, previous chemotherapy and radiation all impede wound healing through different mechanisms. Depending on the clinical situation, an immediate versus a delayed reconstruction is proposed. While immediate coverage is more cost-effective and less time consuming in a medically stable patient with clean a clean wound bed and reliable reconstructive options, a delayed coverage is utilized for patients with contaminated wounds and limited or risky reconstructive options. Incision placement always prioritizes preservation of neurovascular and muscular structures for present and future reconstructive options.

An algorithm by Rohrich, et al.⁶ summarizes the clinical pathway used to arrive to the final plan for the patient's case (Figures 12 & 13). The reconstructive dilemma was that the investigators were presented a case of an oncologic recurrence with previous laparotomy incision and prosthetic mesh use, in an immunocompromised (post-chemotherapy) patient with an irradiated, contaminated wound bed, left with a complete, large abdominal wall defect. Using the algorithm, the patient's defect was complete, full thickness, with inadequate skin (>15 cm). Immediate reconstruction was ideal since the patient was medically stable, had exposed bowels and had reliable reconstructive options.

Free tissue transfer and microsurgery are indicated when local and regional tissue is unavailable to cover any defect or replace missing structures or complex tissue. A free flap is necessary in the conditions: unacceptable donor morbidity in that location, inflammation, infection, insufficient volume or surface area of local and regional tissue, insufficient pedicle length of local and regional potential flaps, poor vascularization of the recipient site as a result of prior radiation, long standing chronic wound, and localized vascular problem.^{7,8}

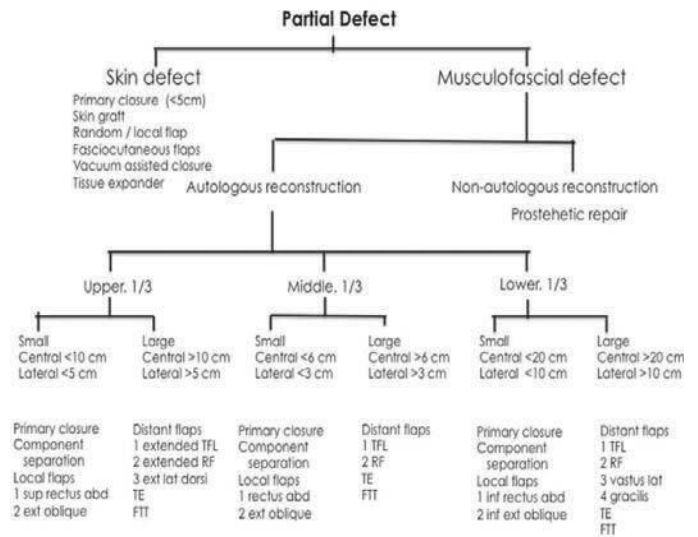


Figure 12. Algorithm for repair of partial abdominal wall defects. TFL, tensor fasciae latae; RF, rectus femoris; FTT, free tissue transfer; TE, tissue expansion. (from R Rohrich, J Lowe, D Hackney, et al. Algorithm for abdominal wall reconstruction. *Plast Reconstr Surg* 2000; 105: 207.

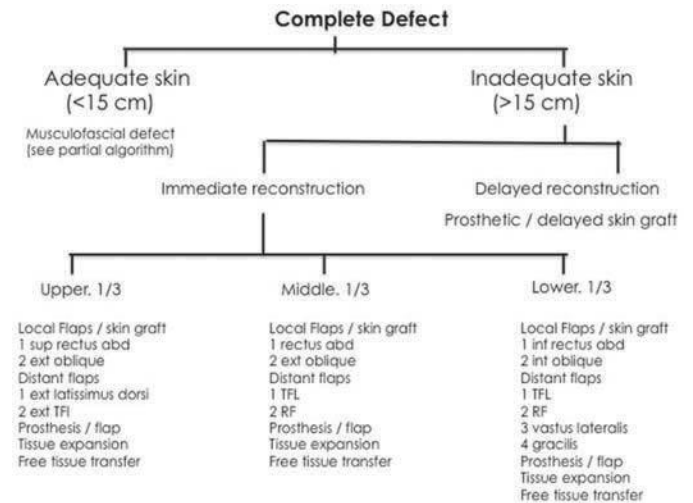


Figure 13. Algorithm for repair of complete abdominal wall defects. TFL, tensor fasciae latae; RF, rectus femoris. (from R Rohrich, J Lowe, D Hackney, et al. Algorithm for abdominal wall reconstruction. *Plast Reconstr Surg* 2000; 105: 208.

The indications for the use of free flaps in abdominal wall reconstruction fit the description of Wong, et al.⁹ : 1) immunocompromised patient, with 2) previous failed

reconstruction with alloplastic material (Prolene mesh), with a 3) contaminated wound (in which the use of totally autologous tissue is preferred), with a 4) large midline and soft tissue defect precluding the use of component separation, local and distant myocutaneous flaps.

The lateral thigh is a reliable versatile donor site for a variety of reconstructive needs in abdominal wall reconstruction, with an advantage of the presence of strong deep fascia in the lateral thigh that can be used to reconstruct the musculofascial layer of the abdominal wall.⁹ The lateral circumflex femoral system comprises of the anteromedial thigh flap, anterolateral thigh flap, tensor fascia lata flap.

It has been established that the versatility of the ALT flap is unparalleled; no other donor site provides such a large amount of soft tissue - skin, muscle and fascia - with little donor morbidity.^{1,10,11,12} It can be harvested as a cutaneous, fasciocutaneous, and myocutaneous flaps. The ALT flap was first described by Song, et al.¹³ in 1984 as a flap based on the descending branch of the lateral femoral circumflex artery; cutaneous branches immersed between rectus femoris muscle and vastus lateralis muscle. However, many variations of the anatomy, both in the musculo/septocutaneous perforators and vascular pedicle, have been documented.^{1,14} Despite the variations, a comprehensive understanding of thigh anatomy will allow the plastic surgeon to harvest the flap without trouble. For this case, perforators were noted to be musculocutaneous in origin, consistent with the review of Wei, et al. among 672 ALT cases, wherein the vessels that supply the anterolateral thigh skin was noted to be musculocutaneous in 87% and septocutaneous in 13%.¹ The pedicle length may reach averagely 11 cm (range, 7cm to 15cm)^{1,7}; 10cm was harvested in our patient. Microsurgical anastomosis between recipient vessels (deep inferior epigastric artery and veins) and donor vessels (descending branch of the lateral circumflex) was done. Part of the fascia from the tensor fascia lata was harvested, and this was inset to the remaining rectus sheath to ensure a water tight closure for the abdominal wall defect. The patient's post-operative course was unremarkable; extubation, removal of drains, ambulation and graft site openings were standard.

The donor site was covered with a split thickness skin grafting. Donor site morbidity is rare for the ALT,¹⁵ and the patient did not present with paresthesia, musculoskeletal dysfunction, hypertrophic scarring, wound dehiscence, pain, seroma, infection, hematoma, or muscle necrosis.

Conclusion

Plastic surgeons are often faced with exceptionally difficult and challenging problems of coverage after extirpative surgery. The free anterolateral thigh flap allows for coverage of complicated recurrent abdominal wall malignancies, allowing for a single-stage surgery, with little donor site morbidity and shorter hospital stay.

References

1. Wong C, Wei F. Clinical review: Anterolateral thigh flap. *J Sc Spec Head Neck* 2010; 32(4): 529-40.
2. Wei F, Jain V, Celik N, et al. Have we found an ideal soft-tissue flap? An experience with 672 anterolateral thigh flaps. *Plast Reconstr Surg* 2002; 109: 2219-26.
3. Yang L, Dongsheng C, Fangfang G, et al. Abdominal wall reconstruction using a combination of free tensor fasciae lata and anterolateral thigh myocutaneous flap: a prospective study in 16 patients. *Am J Surg* 2015; 210: 365-73.
4. Sacks J, Broyles J, Baumann D. Flap coverage of anterior abdominal wall defects. *Semin Plast Surg* 2012; 26: 36-9.
5. Khansa I, Janis J. Review: Modern reconstructive techniques for abdominal wall defects after oncologic resection. *J Surg Oncol* 2015; 111(5): 587-98.
6. Rohrich R, Lowe J, Hackney F, et al. An algorithm for abdominal wall reconstruction. *Plast Reconstr Surg* 2000; 105 (1): 202-16.
7. Baumann D, Butler C. Soft tissue coverage in abdominal wall reconstruction. *Surg Clin North Am* 2013; 93: 1199-209.
8. Prasetyono T. Advances in the practice of microsurgery: focusing on free anterolateral thigh perforator flap. *Med J Indonesia* 2007; 16(4): 245-51.
9. Wong C, Lin C, Fu B. Reconstruction of complex abdominal wall defects with free flaps: Indications and clinical outcome. *Plast Reconstr Surg J* 2009; 124 (2): 500-9.
10. Kuo Y, Kuo M, Lutz B. One-stage reconstruction of large midline abdominal wall defects using a composite free anterolateral thigh flap with vascularized fascia lata. *Ann Surg* 239(3): 352-8.
11. Wolff K, Holzle F. *Raising of Microvascular Flaps: A Systematic Approach*, 2nd edition. Springer, 2011.

12. Candia M Di , Lie K, Kumiponjera D, et al. Versatility of the anterolateral thigh free flap: The four seasons flap. *Eplasty* 2012; 16: 194-206.
13. Song YG, Chen GZ, Song YL. The free thigh flap: a new free flap concept based on the septocutaneous artery. *Br J Plast Surg* 1984; 37: 149-59.
14. Ehlesham-ul-Haq, Aslam A, Hameed S, et al. Free anterolateral thigh flap raised on musculocutaneous perforators of rectus femoris muscle. *J Coll Phys Surg Pakistan* 2011; 21(8): 511-2.
15. Collins J, Ayeni O, Thoma A. A systematic review of anterolateral thigh flap donor site morbidity. *Can J Plast Surg* 2012; 20(1): 17-23.