

Turner Syndrome Associated with Mayer-Rokitansky-Kuster-Hauser Syndrome: A Case Report and Review of Related Literature

Glaiza S. de Guzman, MD, FPOGS, FPSRM and Rosiebel C. Esguerra, MD, FPOGS, FPSRM, FPSGE
Division of Reproductive Endocrinology and Infertility, Department of Obstetrics and Gynecology, Philippine General Hospital, University of the Philippines Manila

Turner syndrome and Mayer-Rokitansky-Kuster-Hauser syndrome are the most common causes of primary amenorrhea. However, müllerian agenesis in patients with Turner syndrome is rare, with only 15 reported cases worldwide. Described in this report is an 18-year-old female who presented with primary amenorrhea, absent secondary sexual characteristics, short stature, webbed neck, and shield chest. Work up revealed hypergonadotropic hypogonadism, absence of normal ovaries and uterus, and hypothyroidism. She had a 45,X karyotype and was diagnosed with a very rare case of Turner syndrome with associated Mayer-Rokitansky-Kuster-Hauser syndrome. Early detection of the etiology of amenorrhea is critical for prompt management and initiation of hormonal replacement. She was counseled on the possible systemic problems associated with her condition. The importance of regular follow-up and continuous care were also emphasized. With the coexistence of these two conditions, adoption is the only option for having children in the Philippines, where oocyte donation and uterine transplantation are currently unavailable.

Key words: Mayer-Rokitansky-Kuster-Hauser syndrome, Turner syndrome

Introduction

Primary amenorrhea is defined as the absence of menses by age 14 years in the absence of growth or secondary sexual characteristics or the absence of menses by age 16 years in the presence of growth or secondary sexual characteristics.¹ The many causes of amenorrhea are categorized according to the level of the disorder and include the following: disorders of the genital outflow tract and uterus, disorders of the ovary, anterior pituitary, and hypothalamus or central nervous system.¹ A systematic evaluation is vital to yield an accurate diagnosis and subsequent referral to specialists.

Turner syndrome and Mayer-Rokitansky-Kuster-Hauser (MRKH) syndrome are the most common causes of primary amenorrhea.² Turner syndrome has an incidence of 1:2500 to 1:3000 female live births, while MRKH syndrome has an incidence

of 1:5000 female live births.^{3,4} The probability of co-existence of both syndromes is 1 in 15,000,000.³ Presented here is an 18-year-old female consulting for primary amenorrhea who was subsequently diagnosed and managed as a case of Turner syndrome with concomitant MRKH syndrome. To date, only 15 similar cases have been reported in literature.

The Case

An 18-year-old female consulted for the absence of menses and secondary sexual characteristics. She is the youngest of three children, born full-term via vaginal delivery to a 40-year-old mother. She had normal developmental milestones as a child. Her siblings did not exhibit similar complaints. She has no known illnesses or previous surgeries. She

is a high school graduate with no history of sexual intercourse.

Physical examination revealed a female phenotype with short stature. Height and weight were below the 5th percentile for age. She had a height of 142 cm, weight of 37 kg, and normal body mass index of 18.35 kg/m². She was responsive to questions and had normal intelligence. Vital signs were stable. She had a webbed neck and broad chest with widely spaced nipples (Figure 1). Breast and pubic hair development were Tanner stage I. The rest of her cardiovascular, pulmonary, and abdominal examinations revealed no abnormalities. On pelvic examination, her labia majora and minora were developed. A vaginal dimple was seen. No palpable structures were identified during rectal examination.

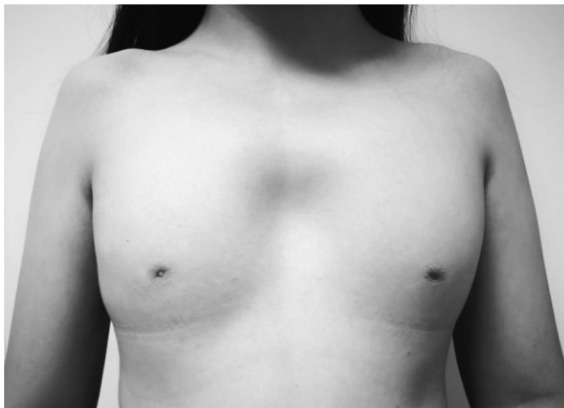

Figure 1. Physical examination showed webbed neck, shield chest with widely spaced nipples. There was no breast bud development.

Transrectal and transabdominal sonography revealed absence of normal ovaries and uterus (Figure 2). There were no adnexal masses seen. Bilateral kidneys were present. The renal pelvis and

calyces were not dilated. No cardiac or vascular abnormalities were noted on 2D echocardiography. Chromosomal analysis revealed an abnormal female chromosome complement in 50 cells, with a single X chromosome (45, X). These findings were consistent with a clinical diagnosis of Turner syndrome with mullerian agenesis.

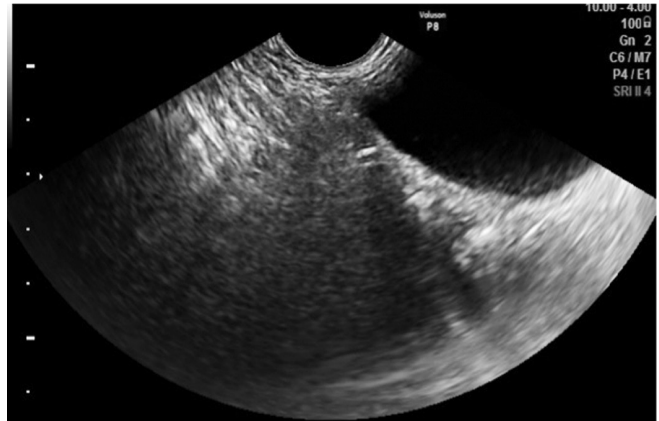

Figure 2. Transrectal examination showed absence of normal ovaries and uterus.

The patient had hypergonadotrophic hypogonadism. Her estradiol level was low at <10 pg/mL. FSH and LH were elevated to 91.75 mIU/mL and 12.56 mIU/mL, respectively. Her TSH was also elevated to 6.6208 uIU/mL (normal range: 0.35 – 4.94) suggesting hypothyroidism. She was started on levothyroxine. Estrogen therapy was initiated for the development of secondary sexual characteristics. After six months of estrogen therapy, the patient was able to undergo pelvic magnetic resonance imaging. No normal ovaries and uterus were seen (Figure 3). She was referred for psychosocial counselling and has been on regular follow up.

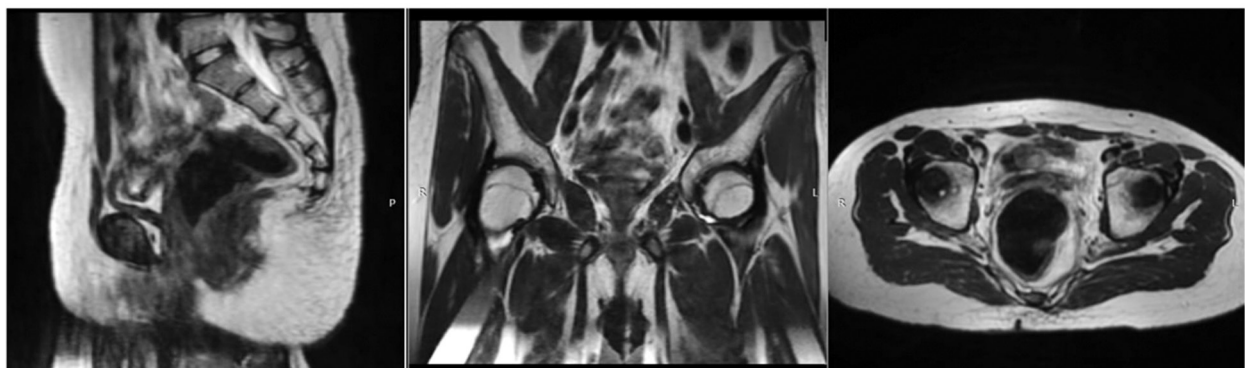


Figure 3. Pelvic magnetic resonance imaging findings were consistent with absence of normal ovaries and uterus on sagittal, coronal, and transverse cuts.

Discussion

Turner syndrome, first described in 1938 by Dr. Henry Turner, is a genetic disorder characterized by partial or complete absence of one X chromosome.¹ Patients present with primary amenorrhea, absent sexual development, webbed neck, short stature, and widely spaced nipples as seen in the index case. Additionally, the classical phenotypic features include low-set ears, posterior hairline, cubitus valgus and short fourth metacarpals. Patients normally present at or near the expected time for puberty with absent menses, growth, and secondary sexual development.¹

Primary amenorrhea is a common presentation of Turner syndrome. Gonadal dysgenesis presenting as streak or underdeveloped ovaries results from the progressive loss of primordial germ cells in the developing embryo.⁴ These hypoplastic ovaries are incapable of producing the estrogen necessary for secondary sexual characteristics and maintenance of puberty.

Diagnosis is primarily based on phenotypic characteristics and biochemical findings of hypergonadotropic hypogonadism. Karyotyping confirms the diagnosis and commonly reveals a single X chromosome (45, X). Paternal non-disjunction accounts for approximately 70% of cases with the 45,X karyotype. Other structural abnormalities of the X chromosome may be present in all or only in some of the somatic cells.^{1,5} Mosaicism for a cell line with a normal or abnormal Y chromosome is observed in 5% of cases presenting with 45,X/46,XY.¹ Karyotyping is essential not only for the diagnosis of Turner syndrome but also for the exclusion of a mosaic cell line with a Y chromosome at risk for developing gonadoblastoma.¹

Patients with Turner syndrome are at risk for a variety of medical problems. Approximately one-third present with a spectrum of cardiovascular anomalies such as bicuspid aortic valve, coarctation of the aorta, mitral valve prolapse, and aortic aneurysm. Renal anomalies are also common and include horseshoe kidney, renal agenesis, ectopic kidney, rotational abnormalities, and partial or complete duplication of the collecting systems. Autoimmune thyroiditis, thrombocytopenia, autoimmune hepatitis, type I diabetes mellitus,

celiac disease, and hearing loss are related illnesses that warrant further investigations.^{1,3} The index case was diagnosed with hypothyroidism and started on levothyroxine therapy. Hypothyroidism is common in patients with Turner syndrome.⁶ Fifteen to thirty percent of women were reported to have hypothyroidism.³ A causal relationship between aberrations of the X chromosome and the risk of autoimmune thyroiditis has been proposed following findings of a high incidence of Hashimoto's disease in patients with Turner syndrome.⁷

The therapeutic benefit of growth hormone (GH) in improving lean body mass and helping achieve normal adult height should be considered. Early initiation of treatment allows most patients to achieve a normal adult height. The maximal benefit is observed when GH is started as soon as the height falls below the 5th percentile for age.¹ Due to diagnosis at a late age, growth hormone administration is less likely to be effective in the patient of the current study.

Estrogen replacement therapy is instituted in patients with Turner syndrome to attain menarche, induce secondary sexual characteristics, help with bone maturation, and plan for subsequent pregnancy.^{1,8} It should be carefully timed to minimize adverse effects on growth and adult height. A low dose estrogen, 0.25 to 0.5 mg micronized estradiol or its equivalent, should be started no later than 15 years of age but not before 12 when growth is a priority. The dose is gradually adjusted every 3 to 6 months until sexual maturation is completed over a period of 2-3 years.¹

Normal development of the mullerian structures is observed in Turner syndrome.⁸ Oocyte donation helps achieve acceptable pregnancy rates in patients with Turner syndrome. The absence of the uterus in this patient led to the consideration of a co-existing cause of primary amenorrhea. Coexisting mullerian agenesis nulls her chance of future pregnancy without oocyte donation and uterine transplantation.

Mullerian agenesis or MRKH syndrome is characterized by aplasia or hypoplasia of the uterus, cervix, upper two-thirds of the vagina, and the fallopian tubes.^{1,4} This is caused by developmental defects of the mullerian duct and tubercle during embryogenesis. While most cases are sporadic, a few cases have been associated with chromosomal

translocation suggesting a possible genetic basis for the condition. MRKH syndrome has been linked to multiple gene mutations involving ESR1, OXTR, HNF1B, LHX1, HOXA7, HOXA 9-13, and HOXD9-13.⁴ Another proposed mechanism is a mutation in the gene encoding the antimullerian hormone in chromosome 12.^{1,8} Errors of fetal or maternal galactose metabolism are also theorized to adversely affect mullerian development.¹

Patients exhibit normal female phenotype, ovarian function, and breast and pubic hair development.^{1,8}

Clinical presentation is primary amenorrhea or hypomenorrhea depending on the degree of structural anomalies. Mullerian agenesis is associated with renal anomalies in one-third of cases. Imaging of the renal system is performed to exclude renal agenesis, ectopic kidneys, or malrotations. The patient in the present case had normal bilateral kidneys.

The primary goal of treatment in patients with MRKH syndrome is the creation of a functional vagina. This can be achieved either by progressive vaginal dilatation or surgical construction of a

Table 1. Cases of Turner syndrome associated with Mayer-Rokitansky-Kuster-Hauser syndrome reported in literature

	Authors (Year)	Age at Presentation	Karyotype	Uterus	Other Anomalies (short stature and absent or underdeveloped secondary sexual characteristics are common features)
1	Shahid (2020) ⁴	16	45,X	Absent	Micrognathia
2	Al-Issa <i>et al.</i> (2019) ⁵	14	45,X/47,XXX	Absent	Short fourth metacarpal bone Ptosis Cubitus valgus
3	Kiran and Jamil (2019) ¹⁰	18	45,X	Absent	No other morphologic malformations
4	Elamparidhi, <i>et al.</i> (2017) ¹¹	17	45,X	Absent	Horseshoe kidney Short 4 th metacarpal
5	Afendi, <i>et al.</i> (2017) ⁹	19	45,X	Absent	No other morphologic malformations
6	Bialka, <i>et al.</i> (2016) ¹²	17	46,X/X(q10)	Hypoplastic	Discrete dysmorphic facial features Convergent strabismus Cubitus valgus Pes planus and kyphoscoliosis of the thoracolumbar spine
7	Meena, <i>et al.</i> (2016) ²	15	45,X/46,XX	Absent	Short fourth metacarpal
8	De Chavez, <i>et al.</i> (2014) ³	18	45,X	Absent	Cubitus valgus
9	Vaddadi, <i>et al.</i> (2013) ⁸	35	45,X	Absent	Primary hypothyroidism
10	Güven, <i>et al.</i> (2008) ¹³	17	45,X/46,X delX(p11.21)	Absent	Bone age of 12 Cubitus valgus Short 4th metacarpals Hypertrophy of both second toes Grade 1 systolic murmur
11	Marcial and Oblepias (2008) ¹⁴	26	45,X[6](46,X,i(X)(q10)[9]	Absent	Shield chest Thoracic dextroscoliosis
12	Aydos, <i>et al.</i> (2003) ¹⁵	19	46,X delX(Pter>q,22)	Hypoplastic	Mild torticollis Cutis marmorata Hallux valgus
13	Ting and Chang (2002) ¹⁶	22	45,X/46,X, del(X)(p22.22)	Absent	Scoliosis of thoracic spine
14	Güitrón-Cantú, <i>et al.</i> (1995) ¹⁷	19	45,X/46,Xdic(X)	Absent	No other morphologic malformations

neovagina once sexual activity is considered by patients.¹ As of the time of writing, the patient has not expressed a desire for sexual contact.

Afendi, et al. (2017) suggested three theories explaining the coexistence of Turner syndrome and MRKH syndrome. The first suggests that genes governing the development and migration of germ cells and mullerian structures undergo inactivating mutations. X chromosome microdeletions have been proposed to cause aberrations in gonadal and mullerian development. The last hypothesis implicates the role of endocrine disruptors in the embryologic development of the germ cells and mullerian structures of these patients.⁹

Table 1 is a tabulation of the cases of Turner syndrome associated with Mayer-Rokitansky-Kuster-Hauser syndrome that are so far reported in literature. In the cases reported, all presented with primary amenorrhea and absence or underdevelopment of secondary sexual characteristics. Six of the 15 cases had the classic monosomy X karyotype^{3-4,8-11} while nine displayed mosaic cell lines.^{2,5,12-18} They were managed similarly with the administration of exogenous estrogen and long-term surveillance. A multi-disciplinary approach depending on coexisting conditions is critical. The need for referral to appropriate specialists including cardiologists, endocrinologists, gastroenterologists, pediatricians, psychiatrists, and urologists should be identified. Patient counseling is a cornerstone of management to improve the patient's overall health and quality of life and set realistic expectations. Strict adherence to hormone replacement therapy should be emphasized as well as long-term monitoring and follow-up. Selective impairments in the cognitive, behavioral, and social domains should be recognized. Low self-esteem and adjustment disorders are common in patients with congenital anomalies. Psychosocial support and behavioral interventions are vital components in the management of the patient.

Summary

Turner syndrome associated with Mullerian agenesis is an extremely rare association. Early recognition of the condition will allow appropriate initiation of hormonal therapy. In such cases, estrogen therapy is given for the development of secondary sexual characteristics and bone health. It is important to counsel the patients with this rare

association of the null chance of conception. While issues relating to the absence of the ovaries and mullerian derivatives are important, it is essential to monitor these individuals for the development of related cardiovascular, renal, endocrine, and immunologic conditions.

Written patient consent for publication has been obtained.

The authors declare no conflict of interest.

References

1. Taylor HS, Pal L, and Seli E (eds.) *Clinical Gynecologic Endocrinology and Infertility*, 9th edition. Philadelphia: Wolters Kluwer. 2020.
2. Meena A, Daga MK, Dixit R. Unusual association of Turner syndrome and Mayer-Rokitansky-Küster-Hauser syndrome. *Case Reports* 2016.
3. De Chavez MDE, Capco-Dichoso M, Opuencia MR. Double burden: a rare case of Turner syndrome with concomitant Mayer-Rokitansky-Küster-Hauser syndrome. *Philipp J Obstet Gynecol* 2014; 38: 31-7.
4. Shahid MM. MRKH syndrome and Turner syndrome co-existing in a patient with primary amenorrhea. *Sri Lanka J Diab Endocrinol Metabol* 2020;10(1): 30-3.
5. AL-Issa SD, AL-Sulimani LK, AL-Jurayyan RN, AL-Jurayyan NA. Ovarian failure with absent uterus is a rare mosaic Turner syndrome(45,X/47,XXX). *Biomed J Scient Techn Res* 2019; 16(5): 1-3.
6. El-Mansoury M, Bryman I, Berntorp K, Hanson C, Wilhelmsen L, Landin-Wilhelmsen K. Hypothyroidism is common in Turner syndrome: Results of a five-year follow-up. *J Clin Endocrinol Metabol* 2005; 90(4): 2131-5.
7. Elsheikh M, Wass JAH, Conway GS. Autoimmune thyroid syndrome in women with Turner syndrome—the association with karyotype. *Clin Endocrinol (Oxf)* 2001; 55: 223-6.
8. Vaddadi S, Murthy RS, Rahul CH, Kumar VL. A rare case of Turner syndrome presenting with Mullerian agenesis. *J Hum Reprod Sci* 2013; 6(4): 277-9.
9. Afendi NR, Hoo PS, Mahamooth MIJ, Ismail AA, Rahim RA, Omar AA, Ibrahim A. Coexistence of Mayer-Rokitansky-Küster-Hauser syndrome with Turner syndrome: A case report. *Edorium J Gynecol Obstet* 2017; 3: 5-8.
10. Kiran Z, Jamil T. Primary amenorrhoea secondary to two different syndromes: a case study. *BMJ Case Rep* 2019; 12(3): e228148.
11. Elamparidhi P, Kumar RR, Sivaranjini S, Sibhithran R. Mullerian agenesis associated with Turner syndrome. *J Clin Diag Res* 2017; 11(2): TD01-TD02.
12. Bialka A, Gawlik A, Drosdzol-Cop A, Wilk K, Malecka-Tendera E, Skrzypulec-Plinta V. Coexistence of Mayer-Rokitansky-Küster-Hauser syndrome and Turner syndrome: A case report. *J Pediatr Adolesc Gynecol* 2016;29(2):E35-E8.

13. Guven A, Kara N, Saglam Y, Gunes S and Okten G. The Mayer-Rokitansky-Kuster-Hauser and gonadal dysgenesis anomaly in a girl with 45,X/46,X,del(X)(p11.21). *Am J Med Genet A* 2008;146a(1):128-31.
14. Marcial SG and Oblepías EG. A Rare case of primary amenorrhea in a patient with Turner syndrome with concomitant Mayer-Rokitansky-Kuster-Hauser syndrome. *Phil J Obstet Gynecol* 2008; 14(3): 67-73.
15. Aydos S, Tukun A, Bokesoy I. Gonadal dysgenesis and the Mayer-Rokitansky-Kuster-Hauser syndrome in a girl with 46,X,del(X) (pter>q22). *Arch Gynecol Obstet* 2003; 267(3): 173-4.
16. Ting TC and Chang SP. Coexistence of gonadal dysgenesis and Mullerian agenesis with two mosaic cell lines 45,X/46,X,del(X)(p22.2). *Zhonghua Yi Xue Za Zhi* 2002; 65: 450-2.
17. Güitrón-Cantú A, López-Vera E, Forsbach-Sánchez G, et al. Gonadal dysgenesis and Rokitansky syndrome. A case report. *J Reprod Med* 1999; 44: 891-3.
18. De Leon FD, Hersch JD, Sanfilippo JS, Scikler KN and Yen FF. Gonadal and mullerian duct agenesis in a girl with 46,X,I(Xq). *Obstet Gynecol* 1984; 63(3 Suppl):81S-83S.