

CASE REPORT

Urethral Masson's Tumour: A Rare and Puzzling Entity

LIM PS¹, NG BK¹, TAN GC², ARUKU N³

¹Department of Obstetrics and Gynaecology, ²Department of Pathology, Faculty of Medicine, Universiti Kebangsaan Malaysia Medical Centre, Jalan Yaacob Latif, Bandar Tun Razak, 56000 Cheras, Kuala Lumpur, Malaysia.

³Department of Obstetric & Gynaecology, Hospital Raja Permaisuri Bainun, Jalan Raja Ashman, 30450, Ipoh, Perak, Malaysia.

ABSTRAK

Intravascular papillary endothelial hyperplasia (IPEH) atau Masson's tumor merupakan sejenis proliferasi vaskular yang berkelakuan lebih kurang sama dengan tumor vaskular malignan yang lain. Sehingga kini, laporan kes ini merupakan kes tumor Masson uretra yang keempat yang pernah dilaporkan. Seorang wanita yang berusia 65, para 2 datang dengan pendarahan dari vagina selepas menopause. Satu ketumbuhan bersaiz 4x3x3 cm dijumpai di uretra meatus sewaktu pemeriksaan fizikal. Pesakit telah menjalani pemeriksaan di bawah bius dan ketumbuhan tersebut telah dibedah siasat. Tumor Masson telah dikenalpasti melalui pemeriksaan histopatologi. Diagnosis dan pengendalian kes luar biasa ini akan dibincang dalam laporan kes ini.

Kata kunci: angiosarcoma, hiperplasia endothelia, tumor Masson, ketumbuhan uretra, ketumbuhan vaskular

ABSTRACT

Intravascular papillary endothelial hyperplasia (IPEH) or Masson's tumour is a benign vascular proliferation that mimics other malignant vascular tumour. To date, this is the fourth case of Masson's tumour at urethra being reported in the literature. A 65-year-old female Para 2, presented with post-menopausal bleeding. Examination revealed a 4x3x3 cm growth surrounding the urethral meatus. She underwent examination under anaesthesia and excision of the periurethral mass. Histopathological examination confirmed Masson's tumour. Diagnosis and management of this uncommon tumour at a rare location was discussed.

Address for correspondence and reprint requests: Lim Pei Shan, Department of Obstetrics & Gynaecology, Faculty of Medicine, Universiti Kebangsaan Malaysia Medical Centre, Jalan Yaacob Latif, Bandar Tun Razak, 56000 Cheras, Kuala Lumpur, Malaysia. Tel: +603-91455949 Fax: +603-91456672 E-mail: peishan9900@yahoo.com

Keywords: angiosarcoma, endothelial hyperplasia, Masson's tumour, urethral neoplasm, vascular neoplasm

INTRODUCTION

Intravascular papillary endothelial hyperplasia (IPEH) is a unique clinical entity i.e. a non-neoplastic intravascular lesion. This lesion was first described by Pierre Masson in 1923 (Masson 1923) then was termed IPEH (Clarkin & Enzinger 1976). So far, various researchers have struggled to define this unique condition with various terminologies such as Masson's tumour, vegetating hemangioendothelioma, intravascular angiomatosis etc. This lesion should be differentiated from other malignant vascular neoplasm like angiosarcoma. We report an extremely rare case of IPEH that occurred in female urethra.

CASE REPORT

A 65-year-old Para 2, post-menopausal for 10 yrs not on hormone replacement therapy, presented with vaginal bleeding for one-week duration. There was no abnormal vaginal discharge or urinary symptoms. Her last Pap smear was 10 yrs ago. She was diagnosed to have hypertension and dyslipidaemia on treatment. Her aunt suffered from breast carcinoma.

Upon presentation, her blood pressure was 126/64mm Hg with pulse rate of 86 beats/min. There was no mass palpable abdominally. Perineal inspection revealed an atrophic vulva and vagina. There was a 3.0 x 3.0 x 4.0 cm growth seen surrounding the

urethral meatus. Punch biopsy was taken and sent for histo-pathological examination (HPE).

HPE of the biopsy showed few segments of brownish tissue with aggregate diameter of 18 mm, macroscopically. Microscopically, there were few segments of haemorrhagic and oedematous fibrous stromal tissue. The stroma was hypocellular and oedematous, composed of multiple thrombosed vessels with some of them displayed intravascular papillary endothelial cells proliferation (Figure 1). The endothelial cells expressed CD34 (Figure 2). There was no dysplasia or evidence of malignancy. The HPE was consistent with intravascular papillary epithelial cell proliferation (Masson's tumour). She subsequently underwent examination under anaesthesia and full excision of the remaining lesion (Figure 3).

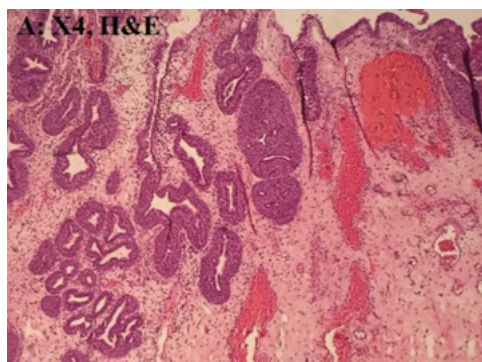


Figure 1: The lesion composed of a polypoidal mass that was lined by a hyperplastic urothelium, with rounded nests of urothelium forming glandular spaces in the stroma. The stroma contained many small blood vessels.

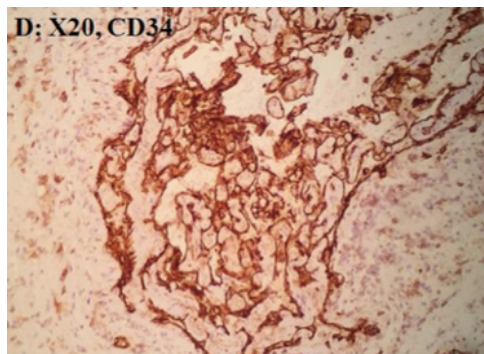


Figure 2: The endothelial cells expressed CD34

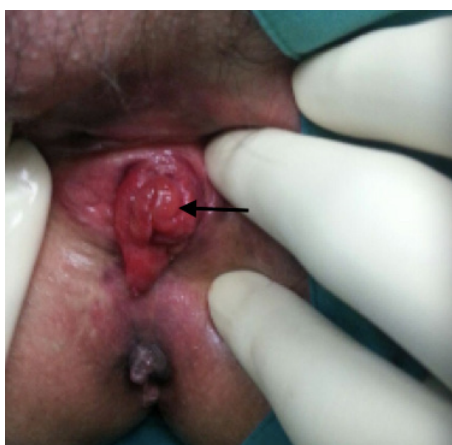

Figure 3: An oedematous polypoidal growth at the urethral meatus

DISCUSSION

To date, the pathogenesis of IPEH remained poorly understood. Possible mechanisms include papillary proliferation of endothelial cell that subsequently degenerates and necrosis in the vascular lumen. Hashimoto et al. (1983) classified IPEH into 3 types. Type I IPEH (primary or pure form) occurs within the vascular spaces, where as, Type II is mixed form that occurs at pre-existing vascular lesion such as haemangioma, arteriovenous malformation or pyogenic granuloma. Lastly, Type III, the least common type,

is found in extravascular space. All these lesions were closely associated with thrombus and thrombotic material (Pegado et al. 2015).

Most IPEH developed in head and neck, extremities and trunk (Hashimoto et al. 1983). It was rarely found in the genitourinary area especially urethra. Clinically, IPEH elsewhere usually presented as a firm tender mass overlying the skin or mucous membrane where as urethral IPEH presented with vaginal bleeding. To date, there are only four reports of urethral IPEH (Nevin et al. 2006; Barua & Munday 1983; Fernandes-Flores et al. 2003) (Table 1). All reported cases were post-menopausal women who were above 60 yrs.

Due to its non-specific clinical presentation; it poses a significant diagnostic challenge as malignant vascular neoplasm like angiosarcoma needs to be ruled out especially in elderly patient. Histopathologically, IPEH is associated with thrombi in an expanded vessel without evidence of mitotic activity, atypia or necrosis. The cells do not invade the perivascular spaces compared to angiosarcoma. Immunohistochemically, IPEH reacts with various substances such as MSA, SMA, CD31 and CD34. Fortunately, angiosarcoma can be differentiated with CD 105 staining as this molecule only overexpressed in angiosarcoma associated endothelial cells (Soares et al. 2008; Akdur et al. 2013).

The prognosis of IPEH is very good. Treatment includes local excision. Recurrence is extremely rare, though, it might occur at the site of previous vascular lesion or if the lesion is

Table 1: Summaries of IPEH infemale urethral

Case	Age	Post menopause	Presentation	Physical finding	Size (cm)
Nevin et al 2006	67	Yes	Vaginal bleeding	exophytic urethral mass	2.0 x 0.4 x 0.7
Barua and Munday 1983	60	Yes- 12 years	Vaginal bleeding	irregular black mass from anterior lip of urethral meatus	3.5 x 3.0 x 3.0
Fernandez et al 2003	72	-	Vaginal bleeding	mass in urethral meatus	1.0 x 1.0 x 0.5
Current case	65	Yes-10 years	Vaginal bleeding	mass in urethral meatus	3.0 x 3.0 x 4.0

incompletely excised (Inaioz et al. 2001). The present patient presented with post-menopausal bleeding secondary to urethral IPEH. There was no evidence of recurrence after one year of excision.

IPEH at female urethra is an extremely rare occurrence. The lesion must be differentiated from other malignant vascular neoplasm. Surgical excision is warranted for histopathological examination as incorrect diagnosis may lead to over aggressive treatment.

REFERENCES

- Akdur, N.C., Donmez, M., Gozel, S., Ustun, H., Hucumenoglu, S. 2013. Intravascular papillary endothelial hyperplasia: histomorphological and immunohistochemical features. *Diagn Pathol* **8**: 167.
- Barua, R., Munday, R.N. 1983. Intravascular angiomas in female urethral mass. Masson intravascular hemangioendothelioma. *Urology* **21**(2): 191-3.
- Clarkin, K.P., Enzinger, F.M. 1976. Intravascular papillary endothelial hyperplasia. *Arch Pathol Lab Med* **100**(8): 441-4.
- Fernandez-Flores, A., Merino-Sanchez, J.M., Del-Barrio, M., Bouso, M., Alonso-Ortiz, J. 2003. Intravascular papillary endothelial hyperplasia in a female urethral mass. *BJU Int* **92**(Suppl 3): e58-e59.
- Hashimoto, H., Daimaru, Y., Enjoji, M. 1983. Intravascular papillary endothelial hyperplasia. A clinicopathologic study of 91 cases. *Am J Dermatopathol* **5**(6): 539-46.
- Inaioz, H.S., Patel, G., Knight, AG. 2001. Recurrent intravascular papillary endothelial hyperplasia developing from a pyogenic granuloma. *J Eur Acad Dermatol Venereol* **15**(2): 156-8.
- Masson, P. 1923. Hemangioendothelioma vegetant intra-vasculae. *Bull Soc Anat* **93**: 517-23.
- Nevin, D.T., Palazzo, J., Petersen, R. 2006. A urethral mass in a 67-year-old woman. Papillary endothelial hyperplasia (Masson tumour). *Arch Pathol Lab Med* **130**(4): 561-2.
- Pegado, P.F., Ordi, Q.C., Roche, S., Rivas, A.G., Domiguez, R.O. 2015. Intravascular papillary endothelial hyperplasia (Masson tumour) mimicking a sarcoma and developing from an arteriovenous hemodialysis fistula. *Skeletal Radio* **44**(6): 859-62.
- Soares, A.B., Altemani, A., Furuse, C., Demasi, A.P., Gati, C., Nunes, N., de Araujo, V.C. 2008. Intravascular papillary endothelial hyperplasia: report of 2 cases and immunohistochemical study. *Oral Surg Oral Med Oral Pathol Oral Radio and Endod* **106**(5): 708-11.

Received: 4 November 2016

Accepted: 25 May 2017