

CASE REPORT

PATHOLOGICAL LAUGHTER ASSOCIATED WITH CEREBRAL LUPUS: A CASE REPORT

*Jasraj Singh**, *Chai Yee Chin***, *Norhashim Ahmad**

***Department of Psychiatry, Hospital Sultanah Aminah, Johor Bahru, Malaysia;**

****Department of Psychiatry, Universiti Kebangsaan Malaysia Medical Centre,
56000 Cheras, Kuala Lumpur, Malaysia.**

Abstract

Objective: Pathological laughter, pseudobulbar affect or a myriad of its other synonyms, is a condition common secondary to neurological injury, presenting with uncontrolled laughing or crying, appearing to be mood-incongruent and significantly debilitating. The objective of this case report is to highlight a rare case of pathological laughter associated with Cerebral Lupus. **Methods:** We report a case of a 27-year-old lady presenting with signs and symptoms of stroke with dysarthria progressing to aphasia and then pathological laughter, with an underlying poorly controlled Systemic Lupus Erythematosus, manifesting as Cerebral Lupus. **Results:** An improvement in affect congruency followed by decreased frequency of outbreaks among bouts of pathological laughter. **Conclusion:** The combination of Escitalopram and Topiramate is effective in the symptomatic treatment of Pathological Laughter. *ASEAN Journal of Psychiatry, Vol. 18 (1): January – June 2017: XX XX.*

Keywords: SLE, Pathological Laughter, Pseudobulbar Affect, Emotion, Topiramate

Introduction

Pathological laughter and crying (PLC), Pseudobulbar affect (PBA) or emotional lability, characterized by uncontrollable laughing and/or crying, that may be mood-incongruent, and out of proportion to the current emotional state [1,2]. It may occur as a common adversity of central nervous system disease like stroke, multiple sclerosis, even traumatic brain injury, but it is still poorly recognized and inadequately treated. We report on a rare case of a 27-year-old lady, whom has experienced PBA post Cerebral Lupus. Her pertinent presentation was a case of slurring of speech progressing to aphasia, along with upper and lower limb weakness and transient loss of gag reflex, culminating in uncontrollable laughing with or without being prompted.

Case report

A 27-year-old lady, married; with underlying SLE diagnosed in 2012 on regular oral prednisolone, was admitted to our general medical ward on the 1st of December 2015; presenting with complaints of slurring of speech for 2 weeks, progressing to aphasia 5 days prior to admission, associated with dysphagia and right-sided weakness. 3 weeks prior to admission, the patient's mother noted her to be laughing uncontrollably without any prompting, and her emotional affect was incongruent with present stimuli such as attempts to converse or simple close-ended questions, which was dismissed off as playfulness. Other examinations; noted general hyperreflexia, with up going babinski reflexes.

Blood investigations showed a positive ANA, titer of 1:160, positive Anti-dsDNA, positive Anti-Cardiolipin Antibody, Ig G. An MRI Brain done on the 4th day of admission, showed multiple cortical lesions in the right parietal lobe, also subcortical and white matter

lesion in the left fronto-temporo-parietal lobes. Multiple deep gray matter lesions seen in both basal ganglia, corona radiata and centrum semiovalae; representing multifocal infarctions, vasculitic changes secondary to systemic lupus erythematosus. (Fig 1.)

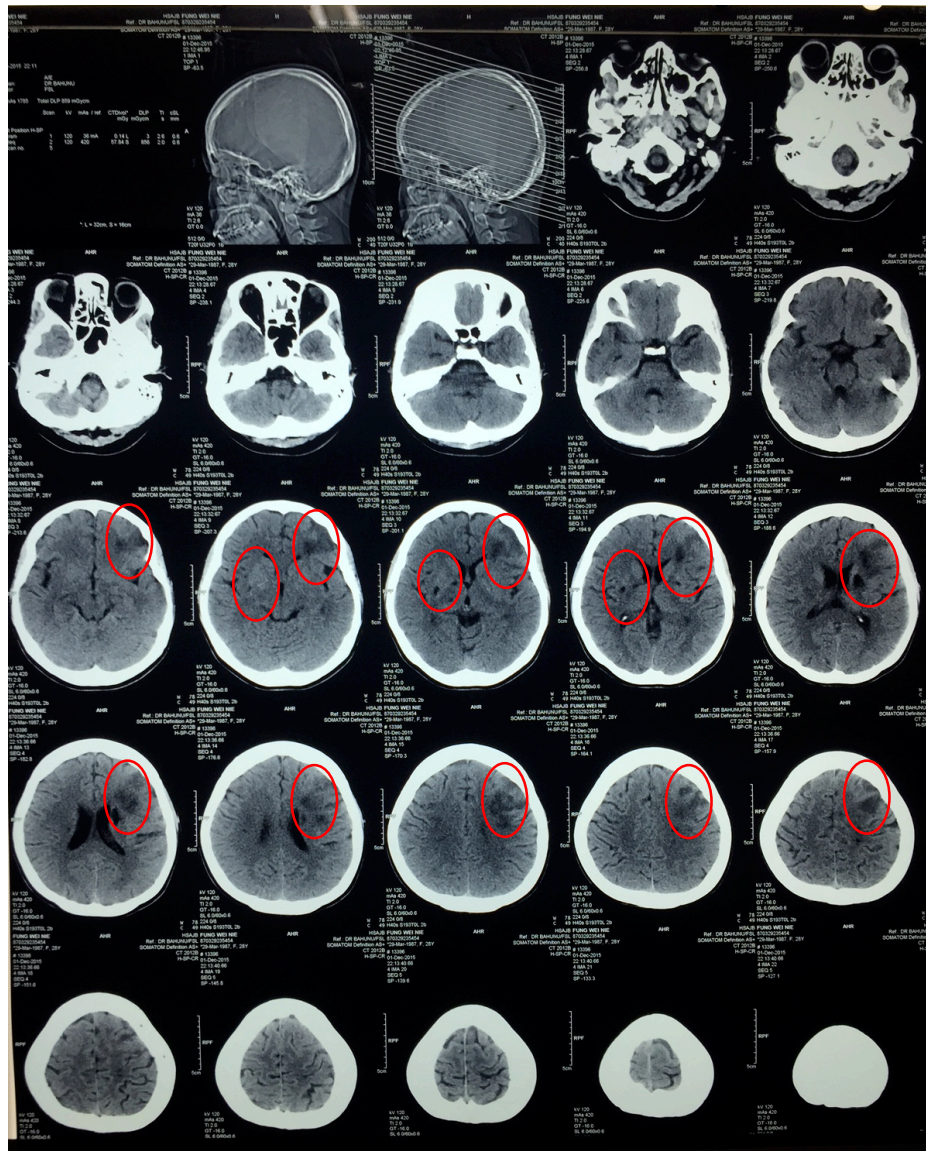


Figure 1. CT scan of the brain revealed well-defined hypodensity in the left corona radiata, left centrum semiovale, right thalamus, right internal capsule, right external capsule. The ill-defined hypodensity is in left frontal lobe [The right side of the patient's brain corresponds to the reader's left side].

On the 6th day of admission, she was started on pulse therapy; IV Methylprednisolone (500mg/ 3 days), and then oral tapering down dose of Prednisolone (30mg/2.5 months). In June of 2015, she was admitted for just over 1 week; presenting with L-sided paresthesiae and weakness of extremities; corresponding to a clinical diagnosis of Cerebrovascular

Accident. CT Brain then showed hypo densities in the left corona radiata, right basal ganglia and internal capsule. MRI/MRA showed irregular walls, with alternating stenosis & dilatation of the anterior and posterior circulation. She was treated as SLE with Vasculitis, with a course of oral prednisolone. Upon discharge, her medications

were optimized, and she was compliant to treatment.

Conjoined multidisciplinary efforts from Physiotherapy, Rehabilitation and Occupational Therapy, helped her overcome the strength deficits post stroke, but unfortunately her speech remained impaired, along with the presence of her pathological laughter. There was an occasion when her mother was expressing her frustration and caretaker burnout, eventually breaking into tears; she followed suit and started to cry too, with an obvious frown on her face, downward pointing lip angles, reddened nose and eyelids. Attempts to vocalize still ended up with her laughing uncontrollably, worsening her already present feelings of despair and hopelessness.

Communication was impaired as she lacked means for expression of her feelings, ideas, and questions. Verbal output was limited to monosyllabic words, of a restricted variety. She would break into a fit of laughter, lasting under 10 seconds, at every prompt or attempt made at trying to converse or convey ideas, and even when the stimulus was sub-threshold, causing an out of proportion response. Going outdoors proved to be a social challenge for the mother. She performed better when asked close-ended questions, with options being a simple nod or shake of the head sideways, still with occasions of laughter. An improvisation from her, was the use of her phone's text application, where she would type out phrases, albeit with some difficulty owing to residual right-sided hand weakness and mild discoordination.

She was diagnosed also as Major Depressive Disorder (MDD), secondary to her general medical condition. Her mother had noted her to be socially withdrawn prior to admission, reduced appetite, and appeared to sleep more throughout the day. She was started on T. Escitalopram 5mg, and optimized to 10mg per nocte. During subsequent outpatient follow up, her mother noted that her condition worsened; developing uncontrolled laughter even without stimuli. Affect was incongruent with the thought. She was started on T. Topiramate 25mg per nocte, and Escitalopram at 10mg per nocte was continued.

During her next follow up, her mother attested, to a degree, of improvement. The frequency and intensity of her uncontrolled laughter reduced. During routine questioning, she would try to answer, but due to her slowly recovering aphasia, would be able to give monosyllabic answers only, when failing to; then only breaking into a fit of laughter. Her mother also noticed that her affect was very much appropriate to her environment and emotions. There was an episode where she had to leave her husband's home to return to her mother's residence; she was crying profusely due to her unwillingness to leave without a bout of paradoxical laughter.

Discussion

The normal mechanism of laughter involves coordination between the facial and respiratory muscles, triggered by an external stimulus accompanied by elated mood [3]. Pathological laughter is defined as an uncontrollable laughter without apparent stimulus or inappropriate stimulus under normal situations [4]. It is a clinical condition as a consequence of various neurological disorders such as stroke, brain tumors, Alzheimer's disease, traumatic brain injury, amyotrophic lateral sclerosis, extrapyramidal and cerebellar disorders [5,6]. It is a disorder of emotional motor expression rather than disorder of mood [3].

Accurate estimations of the prevalence according to specific neurological disorders are lacking [5]. The prevalence of pathological laughing and crying (PLC) post stroke reported about 10 to 34% [7,8,9]; 5 to 11% in traumatic brain injury [10,11]; 10% in multiple sclerosis [12,13,14]; 49% in amyotrophic lateral sclerosis [15], 5% in Parkinson's disease and non-cerebellar type of multiple system atrophy (MSA) [16]; 37% of cerebellar type of MSA [17].

Systemic lupus erythematosus (SLE) is a chronic multisystem autoimmune inflammatory disease which affects females, predominantly [18]. It is a disorder which affects multiple organs throughout the body, including the central nervous system [19]. Within Psychiatry per se, SLE also presents with various types of neuropsychiatric systemic lupus erythematosus (NPSLE)

syndromes according to the American College of Rheumatology (ACR) [20], of which less than 40 to 50% of the presentations are directly due to underlying lupus activity. There are about 30 to 40% of NPSLE syndrome occurrence, according to several cohort studies [21,22]. The NPSLE syndromes associated with central nervous system included meningitis, cerebrovascular disease, cognitive disorders, headaches, psychiatric disorders, and many others [20]. However, pathological laughter as a sequela of cerebral lupus has rarely been reported hence so far. There have been reports on post stroke pathological laughter [3], but they were not associated with SLE.

There is no exact pathophysiology of PLC. It has been suggested that serotonergic dysfunction contributes to the impaired emotional regulation in patients, resulting in PLC [23]. Serotonin receptors are widespread throughout the brain and project down to the cerebellum, which is also involved in controlling of emotion [24]. Correspondingly, the post-stroke patient with pathological laughter responded well with the selective serotonin reuptake inhibitors suggests that the serotonergic pathways are involved in coordinating, crying and laughing [4,10,25]. In this patient, there is extensive involvement of the cerebral cortex and multiple deep grey matter structures without apparent lesions affecting the cerebellum or pons. Despite the multitude of regional involvement, she was successfully able to recover her motor function gradually, but her pathological laughter remained, showing some deficit in the control of her expression, even though congruency was kept in line.

There are currently no established guidelines for the treatment of pathological laughter. There have been cases reporting lamotrigine effective for cases secondary to traumatic brain injury [26]. Tricyclic antidepressants such as Amitriptyline [27] and selective serotonin reuptake inhibitors, particularly Citalopram [28,23], Fluoxetine [29] or Sertraline [30] had been used for pathological laughter post stroke. There are also cases reporting Venlafaxine [31] and Mirtazapine [32] use for those who suffering from pathological laughing and crying post stroke, but have not responded well with SSRIs.

Combination therapy of Dextromethorphan and Quinidine is found to be effective for PLC associated with multiple sclerosis [33] and amyotrophic lateral sclerosis [34]. This led to the approval of the Dextromethorphan/Quinidine for the usage of PBA by US Food and Drug Administration (FDA) in 2010. However, in this case, we are reporting the combination of Escitalopram and Topiramate as the treatment option for PLC.

Topiramate is among one of the antiepileptic agents. Its structure is different from other antiepileptic agents, which contributes to its array of acting mechanisms [35]. There have been reports on antiepileptics, particularly lamotrigine in the treatment of pathological laughter [26,36]. Topiramate has shown to have an inhibitory effect on sodium conductance, which decreases the generation of action potential frequency; enhancing GABA, inhibiting carbonic anhydrase and AMPA subtype glutamate receptor [35]. However, its effect on pathological laughter in this post cerebral lupus patient remains unknown. It is proposed that topiramate may exert an inhibitory effect on the cerebellum, thus resulting in a decrease of frequency and intensity of pathological laughter.

Conclusion

The present case is unique, where pathological laughter occurs as prodromal syndrome prior to cerebral lupus, and progressively rises prominence and worsens post cerebral lupus in contrast to the improvement of other neurological deficits, especially the motor power of all 4 limbs. This resulted in difficulty to the patient to express herself as well as for the loved ones surrounding her to understand her in any other way. The combination of an SSRI and Topiramate is reported to be effective for symptomatic treatment of pathological laughter. These interventions offered treatment options for those who suffer from pathological laughter or crying.

Acknowledgements

We would like to thank the Director General of Health Malaysia for his permission to publish this article.

References

1. Ahmed A, Simmons Z. Pseudobulbar affect: prevalence and management. *Ther Clin Risk Manag.* 2013;9:483-9.
2. Pioro EP. Current concepts in the pharmacotherapy of pseudobulbar affect. *Drugs.* 2011;71:1193-1207.
3. Manabendra Makhal, Uttam Majumder. Pathological Laughter after stroke. *Delhi Psychiatry Journal* 2013;16(2): 441-442.
4. Parvizi J, Anderson SW, Martin CO, Damasio H, Damasio AR: Pathological laughter and crying: a link to the cerebellum. *Brain.* 2001;124:1708–19.
5. Parvizi J, Arciniegas DB, Bernardini GL, Hoffmann MW, Mohr JP, Rapoport MJ, et al. Diagnosis and management of pathological laughter and crying. *Mayo Clin Proc.* 2006;81(11): 1482-1486.
6. Parvizi J, Coburn KL, Shillcutt SD, Coffey CE, Lauterbach EC, Mendez MF. Neuroanatomy of pathological laughing and crying: a report of the American Neuropsychiatric Association Committee on Research. *J Neuropsychiatry Clin Neurosci.* 2009;21(1):75–87.
7. House A, Dennis M, Molyneau A, Warlow C, Hawton K. Emotionalism after stroke. *BMJ.* 1989;198:991–994.
8. Kim JS, Choi KS. Poststroke depression and emotional incontinence: correlation with lesion location. *Neurology.* 2000;54:1805–1810.
9. Morris PL, Robinson RG, Raphael B. Emotional lability after stroke. *Aust N Z J Psychiatry.* 1993;27:601-5.
10. Tateno A, Jorge RE, Robinson RG. Pathological laughing and crying following traumatic brain injury. *J Neuropsychiatry Clin Neurosci.* 2004;16:426–34.
11. Zeilig G, Drubach DA, Katz-Zeilig M, Karatinos J. Pathological laughter and crying in patients with closed traumatic brain injury. *Brain Inj.* 1996;10:591-7.
12. Feinstein A, Feinstein K, Gray T, O'Connor P. Prevalence and neurobehavioral correlates of pathological laughing and crying in multiple sclerosis. *Arch Neurol.* 1997;54:1116-21.
13. Feinstein A, O'Connor P, Gray T, Feinstein K. Pathological laughing and crying in multiple sclerosis: a preliminary report suggesting a role for the prefrontal cortex. *Mult Scler.* 1999;5:69-73.
14. Minden SL, Schiffer RB. Affective disorders in multiple sclerosis: review and recommendations for clinical research. *Arch Neurol.* 1990;47:98-104.
15. Gallagher JP. Pathologic laughter and crying in ALS: a search for their origin. *Acta Neurol Scand.* 1989;80:114-7.
16. Siddiqui MS, Kirsch-Darrow L, Fernandez HH, Jacobson CE IV, Okun MS. Prevalence of pseudobulbar affect in movement disorders and its mood correlates: a prospective study of 754 consecutive patients. *Neurology.* 2006;66 Suppl 2:A369.
17. Parvizi J, Joseph J, Press DZ, Schmahmann JD. Pathological laughter and crying in patients with multiple system atrophy-cerebellar type. *Mov Disord.* 2007;22(6):798–803.
18. Sherif Z. Yacoub Wasef. Gender differences in systemic lupus erythematosus. *Gender Medicine.* 2004;1(1):12-7.

19. Honczarenko K, Budzianowska A, Ostanek L. Neurological syndromes in systemic lupus erythematosus and their association with antiphospholipid syndrome. *Neurol Neurochir Pol.* 2008 Nov-Dec;42(6):513-7.
20. The American College of Rheumatology nomenclature and case definitions for neuropsychiatric lupus syndromes. *Arthritis Rheum.* 1999 Apr;42(4):599-608.
21. Borowoy AM, Pope JE, Silverman E, Fortin PR, Pineau C, Smith CD. Neuropsychiatric lupus: the prevalence and autoantibody associations depend on the definition: results from the 1000 faces of lupus cohort. *Semin Arthritis Rheum.* 2012 Oct;42(2):179-85.
22. Unterman A, Nolte JE, Boaz M, Abady M, Shoenfeld Y, Zandman-Goddard G. Neuropsychiatric syndromes in systemic lupus erythematosus: a meta-analysis. *Semin Arthritis Rheum.* 2011 Aug. 41(1):1-11.
23. Andersen G, Vestergaard K, Riis JO. Citalopram for post-stroke pathological crying. *Lancet.* 1993;342:837-9.
24. Okuda DT, Chyung AS, Chin CT, Waubant E. Acute pathological laughter. *Mov Disord.* 2005;20:1389-90.
25. Kosaka H, Omata N, Omori M, Shimoyama T, Murata T, Kashikura K, et al. Abnormal pontine activation in pathological laughing as shown by functional magnetic resonance imaging. *J Neurol Neurosurg Psychiatry.* 2006;77:1376-80.
26. Chahine LM, Chemali Z. Du rire aux larmes: pathological laughing and crying in patients with traumatic brain injury and treatment with lamotrigine. *Epilepsy Behav.* 2006;8:610-5.
27. Schiffer RB, Herndon RM, Rudick RA. Treatment of pathological laughing and weeping with amitriptyline. *N Engl J Med.* 1985;312:1480-2.
28. Grethe Andersen, Karsten Vestergaard, Jens O Riis. Citalopram for post-stroke pathological crying. *Lancet.* 1993;342:837-9.
29. Brown KW, Sloan RL, Pentland B. Fluoxetine as a treatment for poststroke emotionalism. *Acta Psych Scand.* 1998;98:455-8.
30. Burns A, Russell E, Stratton-Powell H, Tyrell P, O'Neill P, Baldwin R. Sertraline in stroke-associated lability of mood. *Int J Geriatr Psychiatry.* 1999;14:681-5.
31. Smith AG, Montealegre-Orjuela M, Douglas JE, Jenkins EA. Venlafaxine for pathological crying after stroke. *J Clin Psychiatry.* 2003;64(6):731-2.
32. Kim SW, Shin IS, Kim JM, Lim SY, Yang SJ, Yoon JS. Mirtazapine treatment for pathological laughing and crying after stroke. *Clin Neuropharmacol.* 2005;28(5):249-51.
33. Panitch HS, Thisted RA, Smith RA, Wynn DR, Wymer JP, Achiron A, et al. Pseudobulbar Affect in Multiple Sclerosis Study Group. Randomized, controlled trial of dextromethorphan/quinidine for pseudobulbar affect in multiple sclerosis. *Ann Neurol.* 2006;59:780-7.
34. Brooks BR, Thisted RA, Appel SH, Bradley WG, Olney RK, Berg JE, et al: AVP-923 ALS Study Group. Treatment of pseudobulbar affect in ALS with dextromethorphan/quinidine: a randomized trial. *Neurology.* 2004;63(8):1364-70.
35. Shank RP, Gardocki JF, Streeter AJ, Maryanoff BE. An overview of the preclinical aspects of topiramate: pharmacology, pharmacokinetics, and mechanism of action. *Epilepsia.* 2000;41 Supp 1:S3-S9.

36. Ramasubbu R. Lamotrigine treatment
for post-stroke PLC. Clin
Neuropharmacol. 2003;26:233–5.

**Corresponding author: Dr. Jasraj Singh, Department of Psychiatry, Hospital Sultanah Aminah,
Johor Bahru, 10 Jalan Rebab 14, Taman Desa Tebrau, 81100 Johor Bahru, Malaysia.**

Email: jasrajs87@gmail.com

Received: 11 October 2016

Accepted: 3 April 2017