

# A rare case of large sphenothmoidal osteoma

Nazli Zainuddin, MMed(ORL-HNS)<sup>1</sup>, Abdul Fattah Abdul Wahab, MMed(ORL)<sup>2</sup>

<sup>1</sup>Health & Wellbeing (HW) Core, Universiti Teknologi MARA, Shah Alam, Selangor, <sup>2</sup>Department of Otorhinolaryngology, Hospital Sungai Buloh, Selangor

### SUMMARY

Osteoma is the most common benign tumour of the nose and paranasal sinuses. However, involvement of the sphenoid sinus by osteoma is rare. Most of the time, patients with paranasal sinus osteoma are asymptomatic. However, symptoms may present, depending on the location and extension of the tumour. We report a case of a patient with sphenothmoidal osteoma found incidentally on imaging, with evidence of impingement onto the optic nerve at the optic canal. However, the patient was asymptomatic. He was surgically treated using the endoscopic transnasal approach.

### KEY WORDS:

*Sphenothmoidal osteoma, sphenoid osteoma, paranasal sinuses osteoma*

### INTRODUCTION

Paranasal sinus osteoma is a slow growing tumour mostly found in the frontal, ethmoid and maxillary sinuses. Commonly, osteoma is asymptomatic and discovered as an incidental finding on computed tomography (CT). Involvement of the sphenoid sinus is extremely rare. Osteoma measuring more than 30mm in diameter is usually considered a large or giant osteoma.<sup>1</sup> The symptoms of osteoma depend on its location.<sup>2</sup>

### CASE REPORT

A 22-year-old male was involved in a motor vehicle accident and sustained a left zygomatic fracture. The fracture was treated by the maxillofacial surgeon. He was referred to the otolaryngologist because of an incidental finding of osteoma in the CT scan. The patient denied any nasal symptoms like nasal blockage and eye symptoms. Nasal endoscopy showed a huge mass extending medially to the right middle turbinate, to the level of the middle of the right inferior turbinate. The mass pushed the septum to the left. However, it had no nasopharyngeal extension.

CT scan showed bony dense outgrowth with expansion involving the right ethmoid and sphenoid sinuses (Fig 1). Anterior extension was till the anterior ethmoid air cells and posterior extension till the right sphenoid sinus. The nasal septum was deviated to the left side. Laterally, there was bowing of the medial wall of the right orbit, causing a mass effect on the medial rectus muscle. Impingement onto the optic nerve at the optic canal was noted.

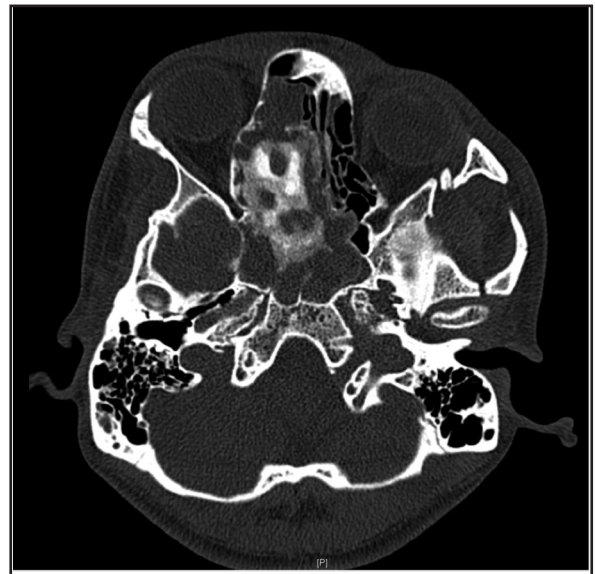


Fig. 1: CT scan showing osteoma involving the right ethmoid and sphenoid sinuses, measuring about 3.1 x 2.0 x 2.6 cm (W x AP x CC).

He underwent endoscopic excision and the intraoperative finding was a right bony mass at the lower half of the right middle turbinate extending into the bullae and lamina papyracea. The main bulk of tumour occupied the sphenoid sinus with extension into the anterior and posterior ethmoidal sinuses. The middle turbinate was removed; access to the sphenoid osteoma was through the right ethmoid sinus. Postoperative recovery was uneventful, and he was discharged well. He came for follow up in the clinic after six months. No complication from the surgery was noted.

### DISCUSSION

The distribution of osteoma in the paranasal sinuses includes: the frontal sinus, which accounts for 71.8%, ethmoidal sinus 16.9%, maxillary sinus 6.4%, and sphenoid sinus 4.9%.<sup>2</sup> Involvement of the sphenoid sinus region is extremely rare and the most common symptoms are headache and unilateral or bilateral visual disturbances.<sup>3</sup> Early visual disturbance only occur with sphenoid osteoma and blindness is usually unilateral. It can also cause optic atrophy.<sup>4</sup> Neurological symptoms are more rare. Sphenoid osteoma has a variable growth rate, causes proptosis and may cause complete blindness due to optic nerve compression.<sup>3</sup> Our patient can be considered as having a

This article was accepted: 16 December 2016

Corresponding Author: Nazli Zainuddin, Health & Wellbeing (HW) Core, Universiti Teknologi MARA (UiTM), 40450 Shah Alam, Selangor Darul Ehsan.

Email: nazlizainuddin@yahoo.com

large osteoma based on size. However, he did not have any symptom despite the findings of optic nerve impingement and mass effect on the medial rectus on CT. We could not tell whether the osteoma originated from the ethmoid or sphenoid sinus.

CT scan is the investigation of choice and shows a well demarcated homogenous mass.<sup>2</sup> Usually, a small osteoma can be observed, especially in the elderly. Indications for surgery include a large osteoma, osteoma filling more than 50% of the volume of the frontal sinus, symptomatic headache or sinusitis, orbital and neurological symptoms or for cosmetic reasons.<sup>1</sup> In our case, even though the patient was asymptomatic, we decided to do surgery to prevent future possible complications such as orbital symptom since compression of the optic nerve had already been demonstrated on imaging.

Access to the sphenoid sinus has traditionally been a challenge. Before the introduction of the sinonasal endoscope, the most popular technique used was the sublabial transseptal approach. Alternative techniques were the transethmoid and transpalatal approaches. Streck in 2005 described the first purely endoscopic approach to a sphenoid osteoma.<sup>5</sup> The choice depends on the extent of the tumour and surgical expertise. In our case, we used the endoscopic transnasal approach and we accessed the sphenoid sinus through the right ethmoid sinus. The middle turbinate of this patient had to be removed since it was involved by the osteoma.

The endoscopic transnasal approach allowed a direct access to the sphenoid sinus with preservation of adjacent structures which were not affected by the tumour. Furthermore, endoscopic examination of the nasal cavity during follow up to look for evidence of recurrence will be much easier and safer.

## CONCLUSION

Involvement of the sphenoid sinus by osteoma is rare, but it has serious complication to the vision due to optic nerve compression. In this case, we treated the patient surgically as early as possible, before he developed visual impairment.

## REFERENCES

1. Cheng KJ, Wang SQ, Lin L. Giant osteomas of the ethmoid and frontal sinuses. Clinical characteristics and review of the literature. *Oncol Lett* 2013; 5(5): 1724-30.
2. Mansour AM, Salti H, Uwaydat S, Dakroub R, Bashshour Z. Ethmoid sinus osteoma presenting as epiphora and orbital cellulitis: Case report and literature review. *Surv Ophthalmol* 1999; 43(5): 413-26.
3. Pompili A, Caroli F, Iandolo B, Mazzitelli MR, Riccio A. Giant osteoma of the sphenoid sinus reached by an extradural transbasal approach: case report. *Neurosurgery* 1985; 17(5): 818-21.
4. Huang HM, Liu CM, Lin KN, Chen HT. Giant ethmoid osteoma with orbital extension, a nasoendoscopic approach using an intranasal drill. *Laryngoscope* 2001; 111(3): 430-2.
5. Canevari FR, Giourgos G, Pistochini A. The endoscopic transnasal parasseptal approach to a sphenoid sinus osteoma: Case report and literature review. *Ear Nose Throat J* 2013; 92(12): E7-10.