

# Treatment of Heavily Pre-treated Metastatic Breast Cancer with Eribulin: First local experience in Sabah

Lee Dai Wee, MBBS<sup>1</sup>, Flora Chong Li Tze, MCO<sup>1</sup>, Daren Teoh Choon Yu, FRCR<sup>2</sup>

<sup>1</sup>Oncology & Radiotherapy Department, Likas Hospital, Sabah, <sup>2</sup>Rafflesia Medical Centre, Kota Kinabalu

### SUMMARY

There are many options in the treatment of heavily pre-treated metastatic breast cancer however none of the therapeutic agents have shown promising improvement of survival with good toxicity profile. Eribulin is a novel non-taxane microtubule dynamics inhibitor. Two recent clinical trial showed that Eribulin improves progression-free and overall survival in this subset of patients. We report our experience with using Eribulin in five patients with metastatic breast cancer either in second or third-line setting, in our centre.

### BACKGROUND

There are various treatment options in heavily pre-treated metastatic breast cancer. However, there is currently no chemotherapy that has shown survival benefit in this group of patients. *Eribulin mesylate* (E7389) is a novel non-taxane microtubule dynamics inhibitor, of the halichondrin class of antineoplastic agent.<sup>1</sup> Eribulin inhibits the growth phase of microtubule dynamics without affecting the shortening phase and sequesters tubulin into non-productive aggregates. Its anticancer effects exert via a tubulin-based antimitotic mechanism leading to G2/M cell-cycle block, mitotic spindle disruption, and, eventually apoptotic cell death after prolonged mitotic blockage.<sup>1</sup>

In the pivotal EMBRACE trial, eribulin was compared with treatment of physician's choice in patients who had received a median of four prior chemotherapy regimens.<sup>2</sup> The median overall survival (OS) was 13.1 versus 10.6 months and median progression-free survival (PFS) was 3.7 versus 2.2 months.<sup>2</sup> In another phase III randomised trial - Study 301 compared eribulin versus capecitabine in patients with locally advanced or metastatic breast cancer previously treated with an anthracycline and a taxane.<sup>3</sup> In this study there was no statistical significance in improvement of OS (15.9 and 14.5 months) and PFS (4.1 and 4.2 months).<sup>3</sup> A pooled analysis of these two phase III trials was done, in total, 1,062 patients were randomised to eribulin and 802 patients to control.<sup>4</sup> Median OS was 15.2 months with eribulin versus 12.8 months with control which is statistically and clinically significant.<sup>4</sup>

In Malaysia, eribulin is approved for treatment in locally advanced or metastatic breast cancer patients who have progressed after at least two chemotherapeutic regimens for

advanced disease. Prior therapy should include an anthracycline and a taxane based regimen, unless contraindicated. We report our experience among the first five patients who received eribulin in Sabah, Malaysia.

### CASE PRESENTATION

In this case series, we report five female patients aged between 39 to 59 years old with metastatic breast cancers (core biopsy confirmed prior to first-line metastatic treatment). They were all previously treated with anthracycline and taxane chemotherapy, then received eribulin as second (n=2) or third line (n=3) palliative chemotherapy. All of them had ECOG (Eastern Cooperative Oncology Group) performance status of 0 or 1 at the time of commencement of treatment. Eribulin was administered intravenously 1.4 mg/m<sup>2</sup> over two to five minutes on Day one and Day eight of every 21-day cycle. Patients were monitored for clinical symptoms, CA15-3 level and radiological assessments. Adverse events were also observed closely during outpatient follow-up and graded according to NCI CTCAE v4.0. The first radiological assessments were done using CT thorax, abdomen and pelvis three months after commencement of eribulin. Eribulin was continued unless there was evidence of disease progression as per Response Evaluation Criteria in Solid Tumors, Version 1.1 (RECIST, v1.1) or unacceptable toxicity. Progression-free survival (PFS) was measured from date of first cycle of eribulin to date of recorded disease progression or death. Overall survival (OS) was measured from date of first cycle of eribulin to date of death from any cause.

#### Case 1

Patient 1 is a 56-year-old lady who initially had left breast ductal carcinoma pT2N2M0 (triple negative) and received adjuvant anthracycline and docetaxel chemotherapy. After seven years, she was diagnosed to have lung metastasis and right breast recurrence. She then received bevacizumab/paclitaxel, and subsequently capecitabine. She was commenced on eribulin as a third-line palliative chemotherapy. Her ECOG was one. Throughout therapy, she had stable disease clinically and by CA15-3 level. Her adverse events were grade 1 headache and anaemia. After three months, CT showed increase in size of lung and nodal disease and eribulin was stopped. Her PFS on eribulin was 3.0 months and OS was 12.5 months.

This article was accepted: 17 June 2016

Corresponding Author: Lee Dai Wee, Likas Hospital, Oncology and Radiotherapy Department, Karung Berkunci No 187, Kota Kinabalu, Sabah 88996, Malaysia Email: eeldavid@hotmail.com

**Case 2**

Patient 2 is a 49-year-old lady with left breast ductal carcinoma pT2N1M0 (ER & PR positive, HER2 negative) which recurred in bilateral breasts, liver, lung and bone. She had received prior anthracycline, docetaxel and cisplatin in the adjuvant setting. As for metastatic setting, she had docetaxel, letrozole and combination everolimus & exemestane prior to eribulin. Her ECOG was 0. Her CA 15-3 level dropped from 138.1U/mL to 38.4U/mL after 5 months. Serial CT and clinical assessments showed stable disease. Grade 2 anaemia was observed however did not require any transfusions. In total she underwent eight cycles of eribulin (third line) before she opted for a drug-holiday. Both her PFS and OS were 8.8 months.

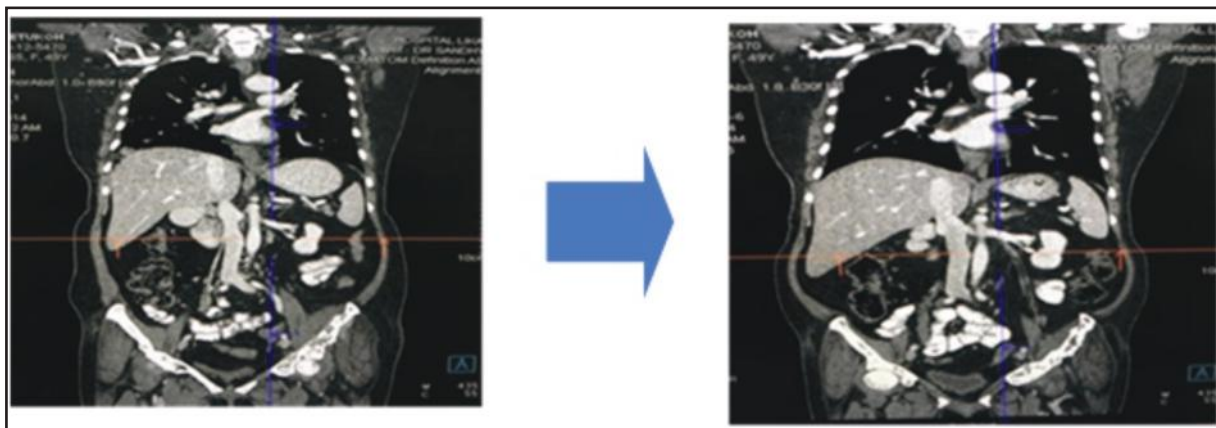
**Case 3**

Patient 3 is a 59-year-old lady who initially had left breast ductal carcinoma stage pT2N2M0 (ER positive, PR negative, HER2 negative) and had adjuvant anthracycline and docetaxel based chemotherapy, and sequential tamoxifen-anastrozole. While on adjuvant anastrozole, she developed left breast, axillary node, liver and bone metastasis. She received combination exemestane and everolimus however

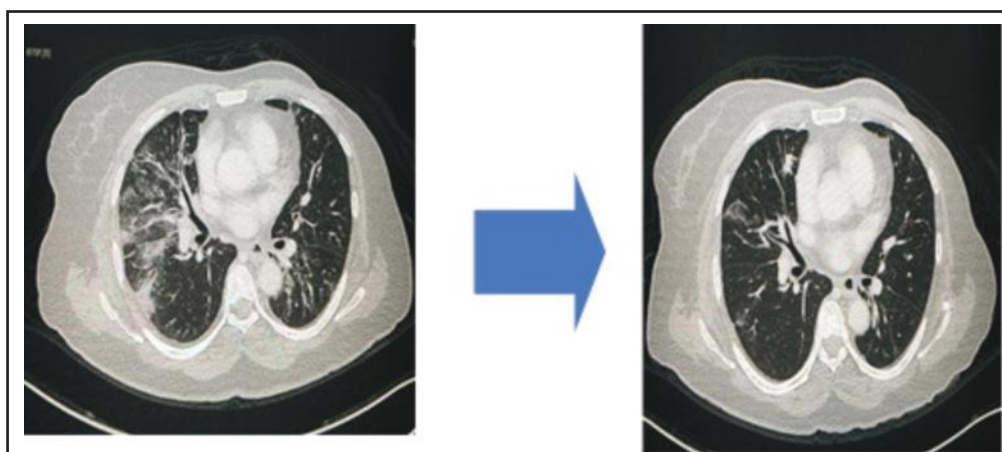
her disease progressed in the liver. She was then started on eribulin (second line). Her ECOG was 0. Grade 3 transaminitis, Grade 2 anaemia and grade 2 alopecia were reported. After 8 cycles of eribulin, her disease progressed again in the liver. Her PFS was 5.7 months and OS was 7.6 months.

**Case 4**

Patient 4 is a 59-year-old lady with de novo left breast ductal carcinoma with liver metastasis (ER and PR positive, HER2 negative). Previously she had anthracycline, docetaxel, tamoxifen and anastrozole. While on anastrozole she developed new lung, bone and para-aortic node metastasis. She was then started on eribulin (third line). Her ECOG was one. Her CA15-3 dropped from 1502U/mL to 194.2U/mL after four months on eribulin. CT at 3 months showed resolution of lung and para-aortic lymphadenopathy (see Figure 1 and 2). Clinically, there was reduction of bone pain. Eventually her disease progressed in the lung and eribulin was stopped after 12 cycles. Grade 2 peripheral neuropathy, grade 2 alopecia and grade 2 transaminitis were observed. Her PFS was 7.3 months and OS is not met.



**Fig. 1:** Coronal CT at baseline and 3 months after eribulin showing resolution of para-aortic lymphadenopathy.



**Fig. 2:** CT Thorax at baseline and 3 months after eribulin showing drastic response in the lung metastasis.

Table I: Summary of treatment cycle and treatment response in these 5 patients

| Patient | Cycles of Eribulin | Initial response | Progression-free survival (months) | Overall survival (months) |
|---------|--------------------|------------------|------------------------------------|---------------------------|
| 1       | 5                  | Stable disease   | 3.0                                | 12.5                      |
| 2       | 8                  | Stable disease   | 8.8                                | 8.8                       |
| 3       | 8                  | Stable disease   | 5.7                                | 7.6                       |
| 4       | 12                 | Partial response | 7.3                                | Not met                   |
| 5       | 2                  | Not available    | Not met                            | Not met                   |

## Case 5

Patient 5 is a 39-year-old lady who initially had cT4aN1M0 (ER & PR Positive, HER2 positive) disease. She received prior neoadjuvant 5-fluorouracil/ epirubicine/ cyclophosphamide and adjuvant tamoxifen. While on tamoxifen she developed right chest wall recurrence, mediastinal lymphadenopathy and right pleural effusion. She then received trastuzumab and docetaxel. Upon disease progression, she was commenced on eribulin (second line). Her ECOG was 0. After three cycles of eribulin she opted to stop eribulin due to Grade 2 peripheral neuropathy despite no evidence of disease progression. Both PFS and OS are not met.

## DISCUSSION

The progression-free survival for these five patients ranges from 3.0 to 8.8 months while the overall survival ranges from 7.6 to 12.5 months. The PFS and OS observed seemed comparable to the EMBRACE trial and study 301. However, it is difficult to make direct comparison in view that this is a case series.

The most commonly seen adverse events were mild and manageable including anaemia, alopecia and peripheral neuropathy. No grade 3/4 haematological or non-haematological toxicities were observed. These were no dose modifications (dose delay or dose reduction) required for any of these patients when they were on treatment.

Due to limitation of resources we were only able to provide eribulin treatment for five patients in the initial stage. Thus, direct comparison of survival analysis may be challenging. However, this reflects the more heterogeneous, realistic patient group that we treat in the clinical setting, compared with the clinical trial setting.

## CONCLUSION

From our experience with these five patients, eribulin is a viable option for heavily pre-treated breast cancer patients with reasonable survival outcomes and manageable toxicity profile in the Malaysian setting. With this initial exposure to eribulin usage, we have derived new clinical experience and confidence to use eribulin again in the future.

## REFERENCES

1. Eisai Limited. Halaven® product monograph. Mississauga, Ontario; 2015
2. Cortes J, O'Shaughnessy J, Loesch D, Blum JL, Vahdat LT, Petrakova K, et al. Eribulin monotherapy versus treatment of physician's choice in patients with metastatic breast cancer (EMBRACE): a phase 3 open-label randomised study. *Lancet*. 2011; 377: 914-23
3. Kaufman PA, Cortes J, Awada A, Yelle L, Perez EA, Wanders J, et al. A phase III, open-label, randomized study of eribulin mesylate versus capecitabine in patients with locally advanced or metastatic breast cancer previously treated with anthracyclines and taxanes: subgroup analyses. *J Clin Oncol* 2013; 31(suppl; abstr 1049)
4. Twelves C, Cortes J, Vahdat L, et al. Efficacy of eribulin in women with metastatic breast cancer: a pooled analysis of two phase 3 studies. *Breast Cancer Res Treat*. 2014; 148(1): 553-61