

Case Report

Mild-Aortic Syndrome : A Cause of Recurrent Abdominal Pain

*Putri Yubbu¹, Haifa Abdul Latiff², Alan Sing³

¹ Department of Paediatric, Faculty of Medicine and Health Sciences, University Putra Malaysia, 43400 Serdang, Selangor.

² Pediatric cardiology Department, Institut Jantung Negara, 145 Jalan Tun Razak, 50586 Kuala Lumpur, Wilayah Persekutuan Kuala Lumpur.

³ Pediatric Cardiology Department, Children's Hospital of Philadelphia, Philadelphia, PA 19104 USA

ABSTRACT

Mid-aortic syndrome (MAS) is a rare clinical entity that is characterized by coarctation involving the distal thoracic and/or abdominal aorta and its major branches accounting for 0.5–2% of all cases of coarctation of the aorta (1). Renovascular hypertension can be a significant sequelae - it is the main symptomatic presentation of this disease among children and adolescents. We describe a 9-year-old girl who presents with recurrent abdominal pain and symptomatic hypertension. Due to significant left ventricular systolic dysfunction and uncontrolled hypertension, percutaneous balloon angioplasty was performed to treat the coarctation. To our knowledge, this is the first reported case of MAS in Malaysia. This case report highlights the clinical presentation, the role of computed tomography angiogram (CTA) in the diagnosis and current options in the management of MAS.

Keywords: Mid-aortic syndrome, Recurrent abdominal pain, Balloon dilatation angioplasty, Hypertension, CT angiogram

INTRODUCTION

MAS is an important cause of renovascular hypertension in pediatric age group. Literature review revealed 640 cases had been reported with less than 5% presenting as recurrent abdominal pain. The main etiologies are idiopathic, but some cases have been associated with acquired inflammatory diseases such as Takayasu's arteritis or systemic lupus erythematosus and genetic causes such as Alagille syndrome, William's syndrome, neurofibromatosis type 1 and others (1, 2). In untreated or improperly treated cases, studies have reported a mortality rate of 8% after a median follow-up period of 4.5 years (2, 3, 5). Death was usually attributable to cerebrovascular accidents or concomitant renal disease (2, 5). As many patients can be asymptomatic until they develop end organ damage, recognition of its clinical presentation is essential to avoid delay in diagnosis of this potentially treatable disease.

CASE REPORT

A 9-year-old girl with an otherwise uneventful past medical history presented with a two-year history of intermittent abdominal pain. Due to severe abdominal pain associated with vomiting and diarrhea, she was admitted for inpatient management of her symptoms. On further history, she had also experienced headaches, exercise intolerance, and intermittent facial edema. However, there was no history of chest pain, lower extremity edema or pain. Physical examination revealed a small for age girl, a weight of 15.5 kg (< 3rd percentile) and a height of 113cm (<3rd percentile). She was not dysmorphic or in distress and appeared pink in room air. She was tachycardic with a heart rate of 110 bpm. She had a 30mmHg blood pressure gradient from her upper extremities at 140/90 mmHg to her lower extremities at 109/78 mmHg. The femoral pulses were barely palpable. Further cardiovascular examination showed a normal S1 and S2 with a soft systolic ejection murmur grade II/VI auscultated loudest at the upper left sternal border. The lungs were clear and the liver was enlarged to 3cm below the right costal margin.

Chest radiography demonstrated cardiomegaly with slightly increased pulmonary vascular markings. An echocardiogram was performed that suggested coarctation of the aorta at the level of the diaphragm (figure 1a). There was a significant diastolic run off pattern on Doppler interrogation of the descending aorta with a peak gradient of 44 mmHg. Her left ventricle was noted to have mild hypertrophy with an ejection fraction (EF) of 36 % indicating moderately depressed systolic function. Subsequent CT angiogram further delineated the coarctation as discrete suprarenal narrowing of aorta, just above the superior mesenteric artery (figure 1b). Her blood investigation parameters including renal function, inflammatory markers and connective tissue disorders screening were all normal.

She subsequently underwent cardiac catheterization and an aortogram (figure 2a) which revealed a discrete coarctation at the level of T11-T12 with the narrowest diameter measuring only 2 mm. The proximal diameter was measured to be 9mm and

*Corresponding Author: Putri Yubbu
drputri@upm.edu.my

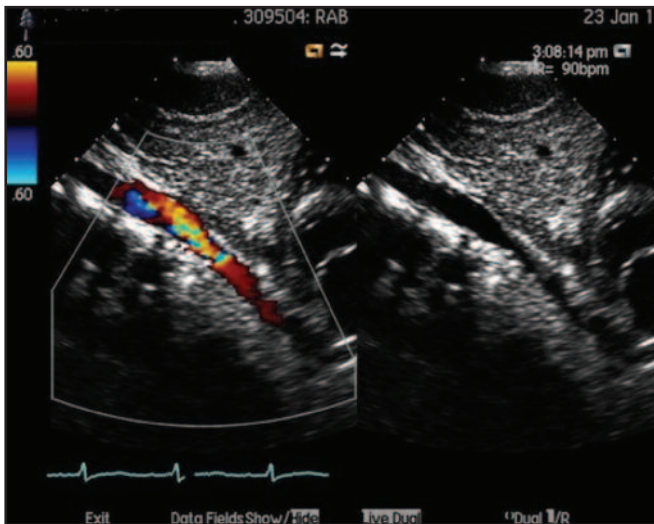


Figure 1a

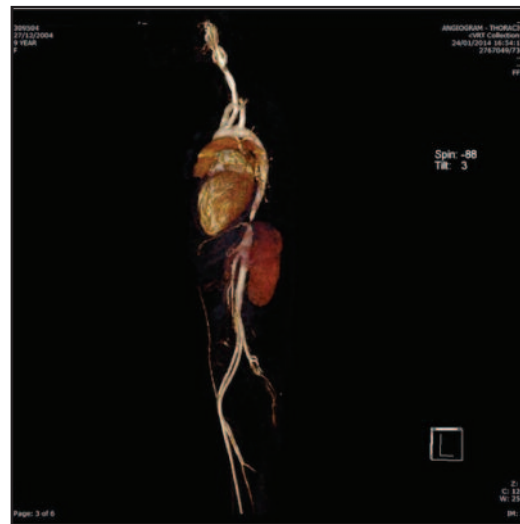


Figure 1b

Figure 1: a) Subcostal sagittal view, 2D Color Doppler showing the coarctation with turbulence flow just below diaphragm.
b) Volume rendered reconstructed CTscan demonstrating suprarenal discrete coarctation at the level just above the superior mesenteric artery.

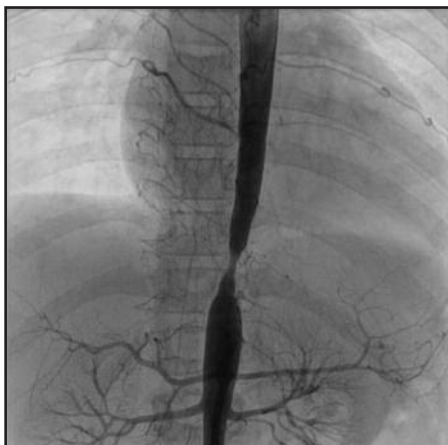

Figure 2a

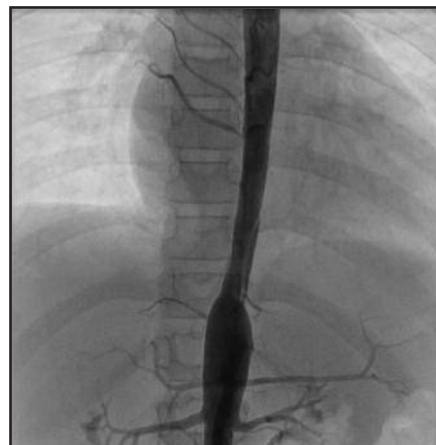


Figure 2b

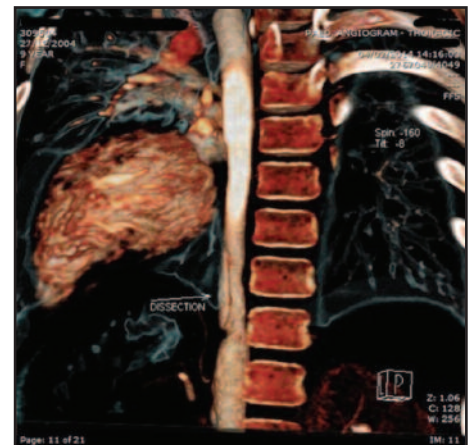


Figure 2c

Figure 2: a) Aortogram finding reveals discrete coarctation at level T11-12 with narrowest diameter 2 mm, Prox 9.3 mm, distal about 10.9mm.
b) Post Balloon dilation showing significant improvement in the caliber was noted with very mild residual gradient but it was complicated by dissection at the site of intervention.
c) Volume rendered CT scan showing the aortic dissection at the site of intervention.

the distal diameter 11mm. The recorded gradient across the coarctation was 38 mmHg. There was no visceral branch artery stenosis but multiple small collaterals were noted around the coarctation. Percutaneous balloon angioplasty of the abdominal coarctation was performed using a 7Fr 10 mm peripheral cutting balloon inflated to 10 atmosphere. Significant improvement in the caliber of the coarctation was noted with a very mild residual gradient but the procedure was complicated by dissection at the site of inflation (figure 2b). The dissection was monitored in the laboratory and there was no further extension or extravasation of contrast noted. CTA was performed after the procedure for further evaluation of the dissection. (figure 2c).

After the procedure, her symptoms resolved with a palpable femoral pulse but she continued to be hypertensive and required management with a beta-blocker therapy. Her cardiac function improved on repeat echocardiography. She was discharged on propranolol and diuretics after 5 days with a plan to repeat a CTA in 6 months for reassessment of recoarctation, dissection or development of aneurysm. She was, however, lost to follow-up so this study was never performed.

DISCUSSION

Patients with MAS can present with hypertension (86%), headache (13.2%) and claudication (10.3%) (2). In the case of

our patient, abdominal pain or angina associated with vomiting was the chief complaint. Her symptoms were likely attributed to ischemia of her intestines due to significant stenosis of the descending aorta just proximal to the origin of the superior mesenteric artery. Rumman et al, in their systemic review, also reported that 4.1% of MAS presented with abdominal angina, and 2.4% presented with vomiting. Abdominal angina is reported to occur most frequently in postprandial periods. We believe that the failure to thrive in this patient is related to her abdominal symptoms and uncontrolled heart failure secondary to hypertension. Further work is needed to understand the effect of intestinal ischemia on intestinal function and constitutional growth.

As hypertension is the main presentation of MAS, it is extremely important to measure four extremity blood pressures and to palpate the femoral or distal pulses as part of the routine cardiovascular examination. Many hypertensive patients can be completely asymptomatic until they develop complications. Another important physical examination finding is the presence of an abdominal bruit, which is reported in up to 22.5% of cases (2,3). The presence of an abdominal bruit, absent or diminished arterial pulses in the lower extremities and upper limb hypertension form the classic triad that suggest the presence of MAS (3).

The gold standard for evaluation of MAS is angiography, but magnetic resonance angiography (MRA) is more frequently being used as an alternative. MRA is able to provide a high level of diagnostic accuracy, including the aortic branches (2,3). Currently, CTA with 3D reconstruction is widely accepted as a diagnostic tool in many specialized institutions (4,5). In our experience, CTA is more readily available and equally effective in delineating the anatomy of the coarctation and provides valuable information in the management plan.

The aim of MAS management is to reverse hypertension, preventing the associated long-term complication, and preserving end-organ function. In most cases, it can be effectively treated with a combination of medical, endovascular and/or surgical interventions (2). The endovascular technique, also known as percutaneous angioplasty, is increasingly performed as it is a minimally invasive non-surgical procedure. It can be in either a stent or balloon form of angioplasty. The short- and medium-term data is showing encouraging results but limited long-term data compared with surgery (2,4,5). In our case, the presence of discrete coarctation, the patient's age, and poor ventricular function led to the decision to perform balloon angioplasty. For this patient, she will likely need another intervention either via stent or surgery due to her young age and a higher risk of restenosis. A recent systemic review reported a procedure failure rate as high as 32.5% for balloon angioplasty compared with 20% for stent angioplasty (2). On the other hand, open surgery is determined mainly by the severity of hypertension and age of the patient. It is recommended to be deferred until full growth potential has been achieved (5). Surgical outcomes are more promising with immediate normalization of blood pressure achieved in 94% of cases and procedure failure rate of 8.3% (2,5). Residual systemic hypertension was a relatively common post-intervention finding (more than 33%) as illustrated in our case study. Compared to genetic etiologies of MAS, patients with the idiopathic disease had higher rates of non-response to medical treatment (2).

In conclusion, MAS can potentially cause significant morbidity and mortality if not properly managed. The presentation can be various and non-specific. A thorough physical examination including four extremity blood pressure measurements can avoid an unnecessary delay in diagnosis that may lead to development of end-organ injury. The management of this clinical entity can be challenging but a combination of medical, endovascular and/or surgical intervention may be able to provide effective treatment.

REFERENCES

1. Sen PK, Kinare SG, Engineer SD. et al. The middle aortic syndrome. *Br Heart J.* 1962;25:610-8.
2. Rawan K. Ruman, Cheri Nickel, Mina Matusda-Abedin, Armando J. Lorenzo, Valerie Langlois et al .Disease Beyond the Arch: A systemic review of Middle Aortic Syndrome in Childhood. *American Journal of Hypertension* 2015;28(7).
3. Kim ten Dam, Roel L. F. van der Palen,Ronald B. Tanke, Michiel F. Schreuder, Huib de Jong . Clinical recognition of mid-aortic syndrome in children; *Eur J Pediatr* 2013;172:413-6.
4. Holloway B J, Rosewarne D, Jones R G. Imaging of thoracic aortic disease. *The British Journal of Radiology* 2011;84:S338354
5. Delis K, Gloviczki P (2005) Middle aortic syndrome: From Presentation to Contemporary Open Surgical and Endovascular treatment. *Perspectives in Vascular Surgery Endovascular Therapy* 2005;17:187-203.