

Case Report

High Myopia Following Unilateral Cryocoagulation for Threshold Retinopathy of Prematurity

*Nazri Omar^{1,2}, Lo Yee Lin², Rafidah Md Saleh^{1,2}

¹ Ophthalmology Department, Faculty of Medicine and Health Sciences, Universiti Putra Malaysia, 43400 Serdang, Selangor, Malaysia.

² Ophthalmology Department, Hospital Serdang, Lebuhraya Kajang-Puchong, 43000 Kajang, Selangor, Malaysia.

ABSTRACT

Despite the proven benefit of cryotherapy in the management of threshold retinopathy of prematurity (ROP), it was shown leading to ocular adverse effects. A male infant was born at 28 week of gestation with a birth weight of 1200 g. Serial examinations revealed worsening ROP in both eyes until he reached a high risk pre-threshold ROP in his right eye and threshold ROP in his left eye. Cryotherapy was performed for the threshold ROP in the left eye while the right eye was subjected to further observation. Subsequently, ROP in both eyes regressed without cicatrization. The patient was followed-up over 8 years and refractions showed that the treated eye developed steadily increasing myopia while the untreated eye remained emmetropic. This case demonstrated the detrimental effect of cryotherapy to the treated eye leading to the progressive myopia as the child grew.

Keywords: Myopia, Cryotherapy, Retinopathy of prematurity

INTRODUCTION

Treatment is indicated in threshold retinopathy of prematurity (ROP) to prevent unfavourable visual outcomes. The CRYO-ROP study paved way for evidence-based treatment of ROP by peripheral retinal ablation using cryocoagulation. Cryotherapy was shown to be an effective treatment in threshold ROP before the introduction of laser therapy. However, cryotherapy can lead to ocular and systemic adverse effects. This report highlights the adverse effect of cryotherapy in threshold ROP.

CASE REPORT

A male infant was born at 28 week of gestation with a birth weight of 1200 g. Patient was intubated for three days followed by nasal continuous positive airway pressure (NCPAP) treatment for two weeks. He also had multiple conditions such as respiratory distress syndrome, anaemia of prematurity and G6PD deficiency.

He progressed to high risk pre-threshold ROP in his right eye and threshold ROP in his left eye. Treatment was decided upon but the laser was unfortunately unavailable at that time. Cryotherapy was performed for the threshold ROP in the left eye. The pre-threshold ROP in the right eye was subjected to further observation. Subsequently, ROP in both eyes regressed without cicatrization.

The patient was followed up regularly over 8 years and serial refractions showed that the treated eye developed steadily increasing myopia while the untreated eye remained emmetropic. Latest refraction showed emmetropic right eye but the left eye had -10.00 DS/-3.00 DC x170 (Fig. 1). Fundus examination revealed normal right eye and tigroid left eye with tilted optic disc indicating elongated globe (Fig. 2). A-scan biometry revealed an axial length of 22.81 mm \pm 0.02 mm (mean \pm standard deviation, SD) in the right eye and 26.30 mm \pm 0.01 mm (mean \pm SD) in the left eye. Other parameters of the eyes are shown in Table 1. At latest review, the patient was prescribed with full correction spectacle which he tolerated well with best corrected visual acuity of 6/6 and 6/7.5 in the right and left eyes, respectively (Fig. 3).

DISCUSSION

The primary goal of the CRYO-ROP study was to investigate the efficacy of peripheral retinal ablation procedure for treatment for ROP, of which cryotherapy was most widely used at that time. Initial publications from the study clearly demonstrated a statistically and clinically relevant 49.3% reduction in the rate of unfavourable outcome in the treated eyes when compared with the control eyes (1). At about the same time of the trial, transpupillary laser photocoagulation was introduced as an alternative treatment. Subsequently, the wide availability of portable lasers with indirect ophthalmoscopic delivery, which can be applied transpupillary with fewer associated local and systemic adverse effects such as pain and swelling, allowed laser photocoagulation to become the most widely used treatment for ROP. Laser photocoagulation remained as the predominant

*Corresponding Author: Dr. Nazri Omar
naz@upm.edu.my

Table 1: Biometric comparison between the patient’s untreated right eye and cryo-treated left eye.

	Right eye	Left eye
K, vertical, D	45.00	46.00
K, horizontal, D	44.75	44.50
Corneal astigmatism, D	0.25	1.50
Axial length, mm	22.81 ± 0.02	26.30 ± 0.01
Anterior chamber depth, mm	3.91 ± 0.05	3.50 ± 0.04
Lens thickness, mm	3.30 ± 0.05	3.57 ± 0.05
Vitreous length, mm	15.61 ± 0.01	19.24 ± 0.02

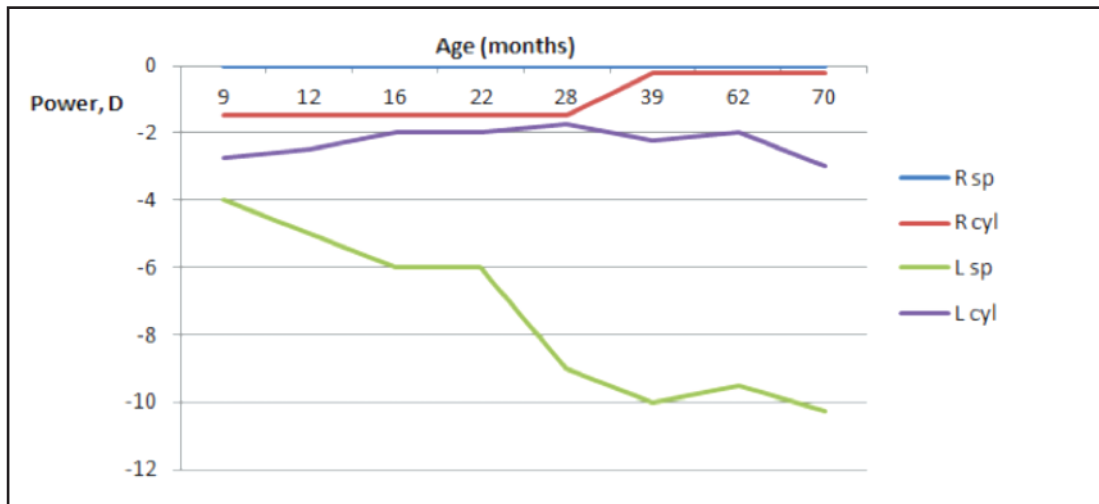


Figure 1: Line chart showing the refractive changes in the patient’s right and left eyes (D, dioptre; R sp, Right eye, spherical; R cyl, Right eye, cylindrical; L sp, Left eye, spherical; L cyl, Left eye, cylindrical).

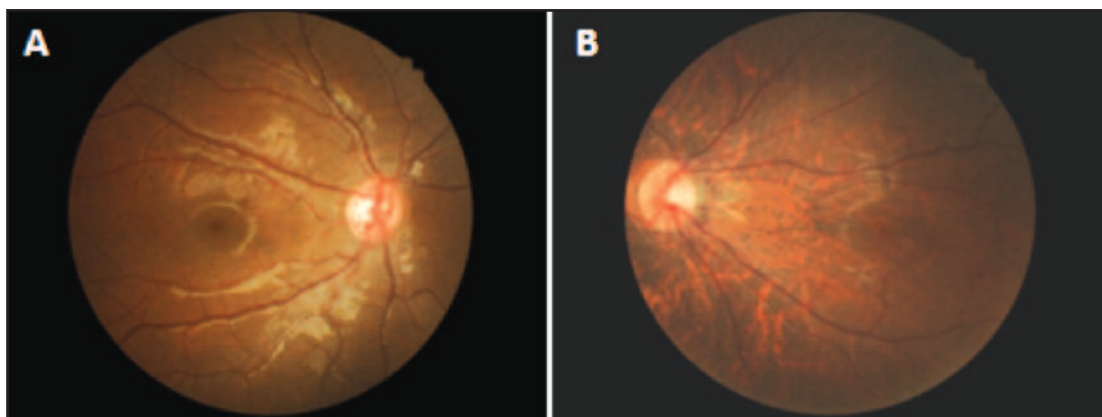


Figure 2: Photographs showing normal right eye (A) and markedly tigroid fundus in the left eye with no scarring from retinopathy of prematurity in the posterior pole (B).



Figure 3: Photograph of the patient while using the full-correction spectacles which was well-tolerated despite the huge anisometropia.

method of treatment to the present time, and cryotherapy is generally reserved for patients with opaque media or other technical limitations to transpupillary photocoagulation.

Although there were limited randomized clinical trials directly comparing cryotherapy and photocoagulation, higher percentages of poor structural and functional outcomes generally were seen in eyes treated with cryotherapy compared with eyes treated with laser treatment. It was shown that the mean spherical equivalent was significantly higher in the cryotherapy group than in the laser photocoagulation group (-9.21 D vs. -1.80 D, $p = 0.001$). Patients in the cryotherapy group were also more likely to have against-the-rule astigmatism (2).

Kent et al reported higher axial and posterior segment lengths in cryo-treated eyes than in untreated or laser-treated eyes. However, the eyes were not from the same patients (3). In contrast, Connolly et al observed that laser-treated eyes were significantly less myopic than cyro-treated eyes predominantly attributable to the lens power in premature babies with threshold ROP, after 10 years' follow up. This finding was accompanied with shorter axial length and thicker lens in cryo-treated compared to laser treated eyes (4).

In our report, the cryo-treated eye and the untreated eye were from the same patient, hence ruling out roles of differences in genetic, systemic or environmental factors in the development of the refractive changes. It points to the possibility of a local factor unique to the treated eye as compared to the fellow eye prior to the onset of the changes which was the cryotherapy. The patient also had shallower anterior chamber depth, thicker lens, increased axial and posterior segment lengths compared to untreated right eyes (Table 1) which were consistent with features reported by Kent et al (3).

In a study of cryo-treated developing eyes in rabbits, Axer-Siegl et al noted histopathological changes including peripheral chorioretinal scar, retinal atrophy and microcystoid oedema, pigment dispersions in the ciliary body without atrophy, adhesion and condensations of the vitreous, and slight disorganization of the overlying sclera possibly making it more susceptible to stretching. These could explain the more severe myopia in cryo-treated eye compared to laser-treated or untreated eyes (5).

Laser photocoagulation is the preferred mode for peripheral retinal ablation in threshold ROP cases and should be made available in centres managing ROP. New treatment modality such as intra-vitreous bevacizumab may offer regression of the threshold ROP with possibly minimal risk of high refractive errors.

CONCLUSION

Although cryotherapy was proven to be effective in reducing the unfavorable outcome in threshold ROP, it can lead to refractive side effects such as myopia and astigmatism. Diode laser is preferred over cryotherapy and should be made available in the treatment of threshold ROP.

ACKNOWLEDGEMENT

The authors would like to thank the Director of Health Malaysia for permission to publish this report. We declare there was no conflict of interest involved in the preparation of this report.

REFERENCES

1. Multicenter trial of cryotherapy for retinopathy of prematurity. Preliminary results. Cryotherapy for Retinopathy of Prematurity Cooperative Group. *Arch Ophthalmol.* 1988 Apr; 106(4):471-9.
2. Al-Ghamdi A, Albiani DA, Hodge WG, Clarke WN. Myopia and astigmatism in retinopathy of prematurity after treatment with cryotherapy or laser photocoagulation. *Can J Ophthalmol.* 2004 Aug;39(5):521-5.
3. Kent D, Pennie F, Laws D, White S, Clark D. The influence of retinopathy of prematurity on ocular growth. *Eye (Lond).* 2000 Feb; 14(Pt 1):23-9.
4. Connolly BP, Ng EYJ, McNamara JA, Regillo CD, Vander JF, Tasman W. A comparison of laser photocoagulation with cryotherapy for threshold retinopathy of prematurity at 10 years: part 2. Refractive outcome. *Ophthalmol.* 2002 5//;109(5):936-41.
5. Axer-Siegel R, Bourla D, Kremer I, Weinberger D, Snir M. Effect of peripheral retinal ablation with cryotherapy versus diode laser photocoagulation on axial length in the growing rabbit eye. *Br J Ophthalmol.* 2006;90(4):491-5.