

Case Report

A Rare Cause of Ootalgia and Otorrhagia: Alive Leech in the Ear

*Mohd Syafwan Mohd Soffian, Irfan Mohamad, Norasnieda Md Shukri

Department of ORL- Head & Neck Surgery, School of Medical Sciences, Universiti Sains Malaysia, 16150 Kota Bharu, Kelantan, Malaysia.

ABSTRACT

Leech infestation in otolaryngology is sporadically seen in remote area of tropical countries, but the cases are usually not scientifically reported. We are reporting an unusual case of a land leech removal from external auditory canal (EAC).

INTRODUCTION

Leeches usually gain access into the human body via ingestion of unclean water from non-hygienic sources or swimming in contaminated water like wells, lakes, swamps and springs (1). Previous leech involvement cases were reported in nose, nasopharynx, larynx, pharynx, eye, rectum and vagina. Prominent sign of all cases was active bleeding from the leech attachment site; that stopped with leech removal (2). The most common mode of presentation in the leech infestation is via the nasal cavity (3).

Leeches that attack human may be divided into two classes (aquatic and land). Land leeches have powerful jaws that can penetrate the skin so that they can attach anywhere on the external surface of the body. Land leeches are common in Southeast Asia, the Pacific Islands and South America. Aquatic leeches have weak jaws and are only able to attach on soft tissues, such as the mucosa of the upper aerodigestive tract, rectums or vagina. Aquatic leeches live exclusively in fresh water and they have a worldwide distribution (2,3).

CASE REPORT

A 71-year-old man presented with sudden onset right otalgia and otorrhagia for a 12-hour duration. He had no history of the head trauma or previous ear disease. Further history was taken and the patient mentioned that the symptoms started several minutes after feeding the dairy herd in the farm during heavy rain. He had no history of swimming in river.

During initial presentation, the patient mentioned of having motile foreign body sensation and active bleeding from the right ear. Suspicious of alive foreign body, the patient then applied a few drop of tobacco leaf juice into the right ear as a traditional repellent. He took dried-tobacco leaf from the cigarette and

mixed it with few drops of water to produce the juice. Upon the application of the tobacco leaf juice, the pain and the sensation of foreign body movement in the right ear canal decreased. However, a small amount of bleeding still occurred. He denied of any attempt to remove the foreign body.

Upon review, the patient appeared comfortable and was not in a severe pain. The endoscopic examination of the right ear revealed minimal oozing of blood with clot obscuring the ear canal. After suction of clots, a leech was observed to be deeply seated near the tympanic membrane. There was a jagged wound with minute point of oozing blood at the anterior wall of the external auditory canal (Figure 1). Eventually a 3 cm non-motile leech was smoothly removed from the right ear using a Baron suction tips under endoscopic visualization. The bleeding stopped a few minutes after a compression with cotton ball soaked in adrenaline. The tympanic membrane was intact. No other foreign body or abnormality was seen. Follow up review at the clinic 5 days later showed that the patient had no otalgia or otorrhagia. The otoscopic examination on the patient revealed there were minimal clots in the right ear canal and at the tympanic membrane.

DISCUSSION

Review of literatures showed only one case of a leech in the ear had been reported. It was a case of an aquatic leech removal from EAC in a man with history of swimming in the river. The author concluded that "Leech infestation is a rare cause of otorrhagia and should be suspected in the endemic region in all of unusual bleeding; it can be diagnosed and treated by exact inspection and removal" (4).

Leeches are blood-sucking hermaphroditic worm, belonging to the phylum Annelida of the subclass Hirudinea (2,6). Leeches comes in different shapes from elongated and cylindrical to broad or ovoid. Their colour may be black, brightly coloured, or mottled. Their length varies from 5 mm to 45 cm. Posteriorly, the leech has three jaws arranged in a triradiate configuration that attach to and bite through human skin. Anteriorly, it has a smaller sucker that is utilized for feeding to suck out blood (6). Leech bites result in a triradiate wound that remains open for a

*Corresponding Author: Dr. Mohd Syafwan Mohd Soffian
mohdsyafwan@yahoo.com , mohdsyafwan@gmail.com

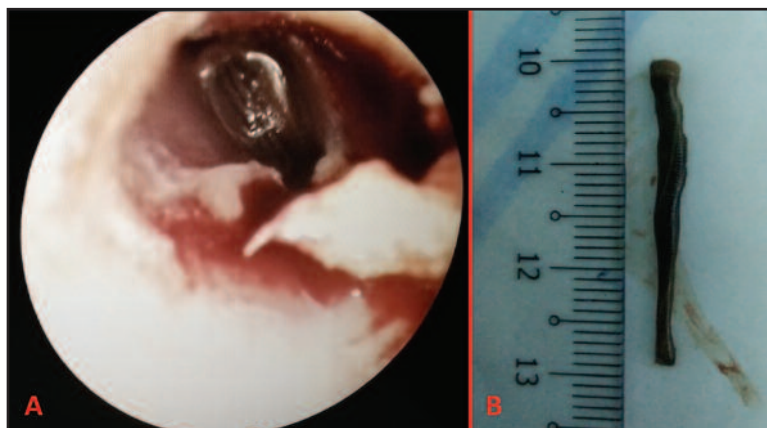


Figure 1: Showing otoscopic view of right ear. There is a leech deeply seated in the right EAC near the tympanic membrane. Jagged wound with oozing blood seen at the anterior wall of right EAC (A). Leech removed from the right EAC measuring approximately 3 cm in length (B).

long time and heals slowly (5,6). As seen in our case, there was jagged wound at the anterior wall of EAC with minimal oozing of blood.

Leeches are capable to secrete an anticoagulant (hirudin) to help them obtain a full meal of blood. Hirudin in leech saliva can inhibit thrombin, factor IXa and hementerin, a plasminogen activator (4,6). It causes prolonged bleeding time, which explains the longer bleeding duration in our patient despite of non-motile leech. The anticoagulant effect will wear off several hours after complete removal of the leech (4).

Since a leech has a soft, slippery body surface and it attaches strongly with its suckers, it is difficult to hold and remove a leech with force especially in a narrow limited space of ear canal, but it should be removed completely to stop the bleeding. In a case of leech attached on the surface of a skin, it may drop off once they have sucked enough blood, or can be removed by a gentle traction or by application of alcohol, insect repellent, vinegar, salt, or a heated instrument to the leech. Leech attached to mucosal surfaces may detach on exposure to saline or could be removed by proper forceps (2). Authors proposed few methods to cause immobility of the leech in facilitating its removal. Hypertonic sodium chloride solution or cocaine/lidocaine were the preferable solution used by the authors to release the hold of the leech or to paralyse it,

respectively (2). Lidocaine 4% was reported to cause immobility of the leech in the eye (4). Unfortunately, Askari et al. mentioned that there was no benefit of using lidocaine 2% and hypertonic saline 5% in his case, but they were successful in causing immobility of the leech by filling the ear with glycerine phenice (4). In our presented case, the leech was believed to become non-motile by the tobacco leaf juice that had been applied by the patient himself, which further facilitates the removal of the leech by using suction tip.

Leeches are not harmful to humans at all times, leeches such as the *Hirudo medicinalis* is often used to treat venous congestion in the settings of microvascular replantations, reconstructive surgery such as free-flap reconstruction, and traumatology such as massive post-traumatic soft tissue hematoma (4).

The important consideration in handling these cases are good history-taking and physical examination to determine the infestation. Drinking or swimming in unclean water in endemic areas carries the possibility of aquatic leech infestation, but land leech infestation is hardly to be suspicious as it can occur even in case of exposure to the grass area in a rainy day. Sudden onset of otorrhagia or otalgia with no history of ear disease and sense of moving object in the ear canal can lead us to a living foreign body in the external ear.

REFERENCES

1. Wiwanitkit V. ENT bleeding and leech bite. *Adv Biomed Res.* 2013; 2: 64.
2. Al B, Yenen ME, Aldemir M. Rectal bleeding due to leech bite: A case report. *Ulus Travma Acil Cerrahi Derg* 2011;17:83-6.
3. Guerrant RL, Walker DH, Weller PF. *Essentials of tropical infectious diseases.* Philadelphia: Churchill Livingstone; 2001. p. 607-8.
4. Askari N, Eshaghian A. Otorrhagia bleeding due to leech bite. *Adv Biomed Res* 2012;1:15.
5. Irish JC, Gullane PJ, Mulholland S, Neligan PC. Medicinal leech in head and neck reconstruction. *J Otolaryngol* 2000;29:327-32.
6. Pandey CK, Sharma R, Baronia A, Agarwal A, Singh N. An unusual cause of respiratory distress: live leech in the larynx. *Anesth Analg* 2000;90:1227-8.