

Original Article

Arthroscopic Mumford Procedure Utilizing the Anteromedial and Neviaser Portals – A Pilot Cadaveric Study on Neurovascular Structures at Risk

*Nasir Mohd Nizlan¹, Azfar Rizal Ahmad², Hisham Abdul Rashid¹, Paisal Hussin¹, Che Hamzah Fahrudin¹, Abdullah Arifaizad¹, Mohamad Aris Moklas³

¹Department of Orthopaedics, Faculty of Medicine and Health Sciences, Universiti Putra Malaysia, 43400 UPM Serdang, Selangor, Malaysia.

²Department of Orthopaedics, Columbia Asia Hospital Cheras, Lot 33107, Jalan Suakasih 43200 Cheras, Selangor, Malaysia.

³Department of Human Anatomy, Faculty of Medicine and Health Sciences, Universiti Putra Malaysia, 43400 UPM Serdang, Selangor, Malaysia.

ABSTRACT

Introduction: Degenerative disorder involving the acromioclavicular joint (ACJ) is quite common especially in the elderly. One of the surgical modalities of treatment of this disorder is the Mumford Procedure. Arthroscopic approach is preferred due to its reduced morbidity and faster post-operative recovery. One method utilizes the anteromedial and Neviaser portals, which allow direct and better visualization of the ACJ from the subacromial space. However, the dangers that may arise from incision and insertion of instruments through these portals are not fully understood. This cadaveric study was carried out to investigate the dangers that can arise from utilization of these portals and which structures are at risk during this procedure. **Materials and Methods:** Arthroscopic Mumford procedures were performed on 5 cadaver shoulders by a single surgeon utilizing the anteromedial and Neviaser portals. After marking each portals with methylene blue, dissection of nearby structures were carried out immediately after each procedure was completed. Important structures (subclavian artery as well as brachial plexus and its branches) were identified and the nearest measurements were made from each portal edges to these structures. **Results:** The anteromedial portal was noted to be closest to the suprascapular nerve (SSN) at 2.91 cm, while the Neviaser portal was noted to be closest also to the SSN at 1.60 cm. The suprascapular nerve was the structure most at risk during the Mumford procedure. The anteromedial portal was noted to be the most risky portal to utilize compared to the Neviaser portal. **Conclusion:** Extra precaution needs to be given to the anteromedial portal while performing an arthroscopic distal clavicle resection in view of the risk of injuring the suprascapular nerve of the affected limb.

Keywords: Acromioclavicular joint, Mumford procedure, Neviaser portal, cadaveric study

INTRODUCTION

The acromioclavicular joint (ACJ) which constitutes the distal end of the clavicle and the medial clavicular facet of the acromion process is a diarthrodial joint which is stabilized by the acromioclavicular (AC) and the coraco-clavicular (CC) ligaments. Degenerative disorder involving the ACJ is quite common in the elderly population as well as in those with traumatic ACJ separation or distal clavicle fractures (1). This condition presents as chronic pain in the upper shoulder region which is clinically localized to the ACJ area and made worse by cross-adduction of the affected shoulder (2).

One of the surgical modalities of treatment of this disorder is the Mumford Procedure (3), which entails excision of the distal 1 cm of the clavicle. This procedure can be performed via an open approach or an arthroscopic approach (1,2,4,5). Arthroscopic approach is preferred due to its reduced morbidity and faster post-operative recovery (2,5,6). Furthermore, it allows diagnosis and treatment of other concomitant lesions associated with ACJ arthrosis, such as rotator cuff tears, impingement lesions and long-head of biceps pathologies (5-8). Open excision of the ACJ, which is less commonly performed of late, has been associated with numerous complications such as shoulder stiffness, infection and prolonged local tenderness (9). Moreover, it has been shown to violate the AC and CC ligaments responsible for the stability in the ACJ (10).

One variant of the arthroscopic method utilizes the Neviaser portal (Fig. 1 – yellow line) and the anteromedial portal (Fig. 1 – blue line), which allows direct and better visualization of the ACJ especially the superior aspect of the acromioclavicular ligament and the joint capsule, thus enabling complete excision of the distal clavicle. Other than arthroscopic Mumford procedures, the Neviaser portal is also used in certain procedures such as arthroscopic rotator cuff repair and superior labral repair. The Neviaser portal is created from outside-in approximately 5

*Corresponding Author: Mohd Nizlan Mohd Nasir
neezlan@yahoo.com

to 10 mm posterior to the ACJ, while the anteromedial portal is created in a similar manner 5 to 10 mm lateral to the clavicular end. However, the close proximity of these portals to some important structures such as the branches of the brachial plexus and the subclavian vessels poses risk of injuring these structures while this procedure is being performed. The objective of this cadaveric study is to find out the dangers that can arise from utilization of these two portals, while identifying which specific structures are at risk when Mumford procedure is performed.

MATERIALS AND METHODS

10 shoulders from 5 male cadavers were used as subjects. The cadavers were thawed a day before the planned procedure and then put in a lateral decubitus positions with a 30-degree posterior inclination just like any standard lateral shoulder arthroscopic surgeries. Four portals were then made (standard posterior viewing, direct lateral, anteromedial and Neviasser). A bursectomy was then performed through the lateral portal using a shaver blade to clear all the bursal tissue within the subacromial space for better visualization of the rotator cuff and also the inferior aspect of the ACJ (4).

The arthroscope was then switched to the lateral portal. Once the ACJ had been identified, the AM portal was made 5 to 10 mm anterior and lateral to the anterior border of the ACJ (See Fig. 1), followed by burring of the anterior aspect of the distal 1 cm of the clavicle, using an acromionizer. The anterior half of the distal clavicle was excised using this process; however, the superior aspect of the distal clavicle residue is usually difficult to visualize through the lateral and also the standard posterior portals.

The arthroscope was then shifted to the anteromedial portal (where the superior aspect of this joint would be easily visualized), and the Neviasser portal was then created. The portal placement was first identified by inserting an 18G branula approximately 10 mm posterior to the posterior border of the ACJ (marked earlier before the starting of the procedure). Through this portal, the excision process was completed while visualization of the joint was done from the AM portal. By switching between these two portals (Fig. 2), the Mumford procedure was carried out completely until at least 8-10 mm of the distal clavicle was removed (2). The acromionizer (4 mm in diameter) was used to gauge the completeness of the excision.

Once the procedure has been completed, methylene blue dye was injected into the portals to mark the edges of the two portals and a dissection was then performed to identify the structures which are at risk (namely the suprascapular nerve, the brachial plexus and the subclavian vessels). The structures which are in close proximity to these two portals were then recorded and the distances between these structures and the edge of both portals were measured using a Vernier caliper. Figure 3 showed the process of measuring the distance between the anteromedial portal to the brachial plexus of the left shoulder in one of the cadavers.

RESULTS

All cadavers had no abnormalities around the subacromial space and the ACJ. All five cadavers were thawed completely to allow proper dissection and measurements. Table 1 shows the measurement results for all 10 shoulders. Due to the limited number of shoulders in this study, the median instead of the mean value was chosen.

Table 1 : The distance between the suprascapular nerve, the musculocutaneous nerve and the brachial plexus and the subclavian vessels to the anteromedial and Neviasser portals, in all 10 shoulders (5 cadavers).

Suprascapular Nerve

The median distance of the anteromedial portals to the suprascapular nerve (SSN) is 3.69 cm (range, 2.91-5.00), while the median distance of the Neviasser portals to the same nerve is 6.01 cm (range, 1.60-6.84). These results show that the Neviasser portal can be very near this nerve, as close as 1.60 cm. The closest distance of the anteromedial portal to this nerve is 2.91 cm.

Musculocutaneous Nerve

The median distance of the anteromedial portals to the musculocutaneous nerve (MCN) is 4.85 cm (range, 3.19-7.00), with the median distance of the Neviasser portals to the nerve being 6.79 cm (range, 5.50-9.13). This nerve appears to be at a much lower risk to be injured compared to the suprascapular nerve.

Brachial plexus and Subclavian vessels

The median distance of the anteromedial portals to the brachial plexus and subclavian vessels is 5.67 cm (range, 4.12-7.50), while the median distance between the Neviasser portals and these structures is 7.75 cm (range, 6.00-9.23). The brachial plexus and subclavian vessels appears to have the least risk of being injured. Table 2 summarizes these findings

DISCUSSION

We believe this is the first cadaveric study investigating the effects of arthroscopic Mumford procedure which specifically looked at the structures at risk when the two portals (anteromedial and Neviasser) are utilized in performing this procedure. Based on these measurements, the suprascapular nerve is the structure most at risk during the Mumford procedure. Among the two portals, the anteromedial portal is the most 'dangerous' portal and needs extra precautions while making its incision and during insertion of instruments and arthroscope. The Neviasser portal is relatively safe to use during this procedure albeit not completely being risk-free. The brachial plexus and subclavian vessels are relatively risk-free.

A cadaveric study by Gartsman et al. in 1991 was done to investigate the adequacy of bone resection performed through arthroscopic Mumford compared to an open method (2). Incomplete excision has been reported to be related to persistent

Table 1: The distance between the suprascapular nerve, the musculocutaneous nerve and the brachial plexus and the subclavian vessels to the anteromedial and Neviaser portals, in all 10 shoulders (5 cadavers).

No	Cadaver	Side	Portals	Distance to SSN (cm)	Distance to MCN (cm)	Distance to BP and vessels (cm)
1	A3	Right	Neviaser	6.44	9.13	9.23
			Anteromedial	2.91	4.76	5.49
2	A3	Left	Neviaser	6.00	6.91	7.99
			Anteromedial	3.05	3.19	4.12
3	K4	Right	Neviaser	3.00	5.50	6.00
			Anteromedial	4.50	7.00	7.50
4	K4	Left	Neviaser	2.60	5.50	6.00
			Anteromedial	5.00	6.00	6.50
5	N1	Right	Neviaser	6.27	7.43	8.17
			Anteromedial	4.01	4.69	5.86
6	N1	Left	Neviaser	6.03	8.38	9.00
			Anteromedial	3.78	6.25	7.39
7	Half-torso	Right	Neviaser	6.84	7.93	8.69
			Anteromedial	4.71	5.39	6.43
8	Half-torso	Left	Neviaser	6.06	6.67	7.11
			Anteromedial	3.54	4.95	4.92
9	A4	Right	Neviaser	1.70	6.50	7.20
			Anteromedial	3.60	3.90	5.10
10	A4	Left	Neviaser	1.60	6.45	7.50
			Anteromedial	3.40	4.40	5.40

Table 2: Median distances between the two portals and the three structures being studied.

Median distance, cm	AM portal	Neviaser portal
Suprascapular nerve (SSN)	3.69	6.01
Musculocutaneous nerve (MCN)	4.85	6.79
Brachial plexus and subclavian vessels	5.67	7.75

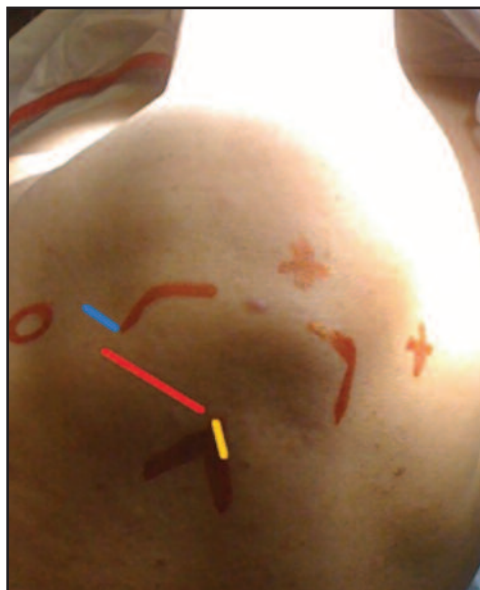

Figure 1

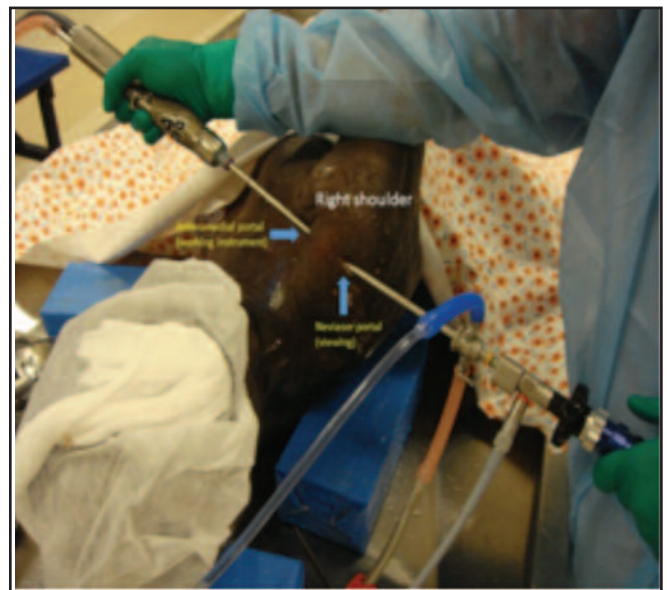


Figure 2

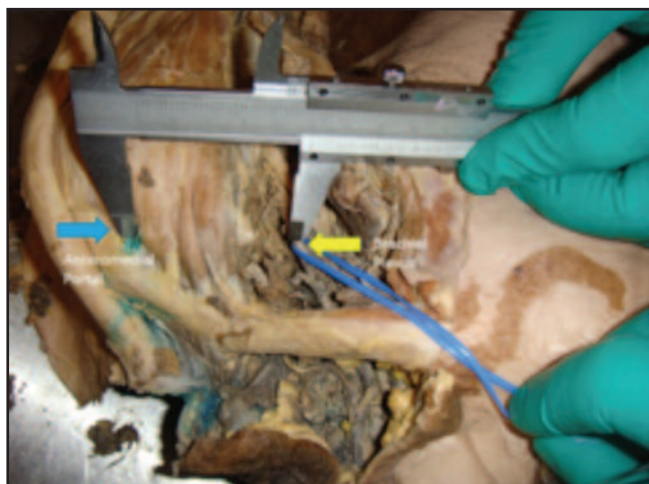

Figure 3

complaint of pain in the affected shoulder (4,11). However, one study showed that excision should not exceed ten millimeters to avoid post-operative pain (1). These two portals are used to ascertain optimum excision of the distal clavicle bone while protecting the superior acromioclavicular (AC) ligament during an arthroscopic Mumford procedure. An alternative way of ensuring complete excision is via the usage of a 70-degree arthroscope (12), however this type of scope is not readily available in all hospitals and also requires some degree of learning curve for a particular surgeon to get used to. Using these two portals allows any surgeons utilizing a 30-degree arthroscope to perform an arthroscopic Mumford procedure while at the same time enabling them to ensure complete excision and avoid residual pain in their patients.

The suprascapular and musculocutaneous nerves are the two structures nearest to these two portals, this was why they were chosen for this study. As the brachial plexus and the subclavian vessels are also in the proximity especially to the anteromedial portal, these structures were also included. Based on the results of this study, the anteromedial portal needs to be used with caution as the risk of this portal injuring both the suprascapular and musculocutaneous nerves is quite high compared to the Neviaser portal. Extra care and diligence are needed while making the incision and also while inserting any instruments through the anteromedial portal.

A cadaveric dissection on 12 cadavers by Woolf et al. showed that the superior-medial or Neviaser portal is 18.5 mm or greater from the suprascapular nerve (13). Their finding is consistent with our result which showed that the nearest distance from this portal to the suprascapular nerve is 16.0 mm, probably because the cadavers used in our study were all of Asian origin, who are smaller in size compared to Caucasian cadavers used in their study. A safe distance was defined as 10 mm in that particular study (13), therefore the nearest distance obtained from our study is still relatively safe. Another study done on 12 shoulders also showed that the Neviaser portal is a safe portal to utilize (14).

Even though the Neviaser portal usage poses risk to the suprascapular nerve, the fact that the upper portion of this nerve is always covered by the supraspinatus muscle (15) makes the risk of injuring this nerve when using this portal somewhat less marked compared to the anteromedial portal. However, in cases where the supraspinatus tendon is torn and medially retracted, the suprascapular nerve would then be exposed directly to the incision to create the Neviaser portal and the risk would then be higher, especially during release of the retracted tendon (16). Therefore, extra precaution is needed if a Mumford procedure were to be performed in a medially retracted supraspinatus tendon tear.

This study was conducted on a small number of cadavers (only 10 shoulders). We propose further studies using a higher number of cadavers, with an equal number of male and female cadaver specimens and probably a variety of ethnicity as these variations may show different findings than our current study.

CONCLUSION

When utilizing the anteromedial and Neviaser portals during an arthroscopic Mumford procedure for ACJ arthrosis, extra caution is needed especially when creating and inserting instruments into the anteromedial portal, as this portal poses the highest risk of injuring the suprascapular and musculocutaneous nerves. A study on a higher number of cadaveric shoulders will yield a more accurate result in the future.

ACKNOWLEDGMENT

The authors would like to thank Puan Farhatani and the support staff of the Anatomy Dissection Hall, Faculty of Medicine and Health Sciences, UPM, for their help in the preparation and maintenance of the cadaveric specimens throughout this study.

REFERENCES

1. Eskola A, Santavirta S, Viljakka HT, Wirta J, Partio TE, Hoikka V. The results of operative resection of the lateral end of the clavicle. *J Bone Joint Surg.* 1996;78-A(4):584-7.
2. Gartsman GM, Combs AH, Davis PF, Tullos HS. Arthroscopic acromioclavicular joint resection. An anatomical study. *Am J Sports Med.* 1991;19:2-5.
3. Mumford EB. Acromioclavicular dislocation – a new operative treatment. *J Bone Joint Surg.* 1941;23:799-802.
4. Lesko PD. Arthroscopic Mumford procedure variation of technique. *Iowa Orthop J.* 1999;19:93-8.
5. Martin SD, Baumgarten TE, Andrews JR. Arthroscopic resection of the distal aspect of the clavicle with concomitant subacromial decompression. *J Bone Joint Surg.* 2001;83-A(3):328-35.
6. Robertson WJ, Griffith MH, Carroll K, O'Donnell T, Gill TJ. Arthroscopic versus open distal clavicle excision. A comparative assessment at intermediate-term follow-up. *Am J Sports Med.* 2011;39(11):2415-20.
7. Freedman BA, Javernick MA, O'Brien FP, Ross AE, Doukas WC. Arthroscopic vs open distal clavicle excision – comparative results at six months and one year from a randomized, prospective clinical trial. *J Shoulder Elbow Surg.* 2007;16:413-8.
8. Kim W, Deniel A, Ropars M, Guillin R, Fournier A, Thomazeau H. How long should arthroscopic clavicular resection be in acromioclavicular arthropathy? A radiological-clinical study (with computed tomography) of 18 cases at a mean 4 years' follow-up. *Orthop Traumatol Surg Res* 2014;S219-23.
9. Chronopoulos E, Gill HS, Freehill MT, Petersen SA, McFarland EG. Complications after open distal clavicle excision. *Clin Orthop Relat Res* 2008;466:646-51.
10. Klimkiewicz JJ, Williams GR, Sher JS, Karduna A, Des Jardins J, Iannotti JP. The acromioclavicular capsule as a restraint to posterior translation of the clavicle : a biomechanical analysis. *J Shoulder Elbow Surg* 1999;8(2):119-24.
11. Strauss EJ, Barker JU, McGill K, Verma NN. The evaluation and management of failed distal clavicle excision. *Sports Med Arthrosc Rev* 2010;18:213-9.
12. Chan HZ, Ooi CL, Lim MY, Ong EKS, Zulkiflee O. Arthroscopic resection of the distal clavicle with concomitant subacromial decompression : A case series. *Malays Orthop J* 2014;8(2):59-62.
13. Woolf SK, Guttman D, Karch MM, Graham RD, Reid JB, Lubowitz JH. The superior-medial shoulder arthroscopy portal is safe. *Arthroscopy* 2007;23(3):247-50.
14. Meyer M, Graveleau N, Hardy P, Landreau P. Anatomic risks of shoulder arthroscopy portals : Anatomic cadaveric study of 12 portals. *Arthroscopy* 2007;23(5):529-36.
15. Metwally ESAM, Elshenety RM, Motawea BA. Suprascapular nerve : Anatomical and clinical study. *Int J Clin Exp Med* 2016;2(3):31-9.
16. Tom JA, Mesfin A, Shah MP, Javandel M, Lee DJ, Cerynik DL, Amin NH. Anatomical considerations of the suprascapular nerve in rotator cuff repairs. *Anat Res Int* 2014; Vol. 2014: (Article ID 674179) 4 pages.