

Multiple magnet ingestion: The attractive hazards

Mohd Yusran Othman¹, MBBS, Srihari Singaravel², MPaedSurg

¹Department of Paediatric Surgery, Institute of Paediatrics, Hospital Kuala Lumpur, 50586 Kuala Lumpur, Malaysia, ²Division of Paediatric Surgery, Department of Surgery, University Malaya Medical Center, Lembah Pantai, 59100 Kuala Lumpur, Malaysia

SUMMARY

Foreign body ingestion among children is common and most usually pass through the gastrointestinal tract without requiring any intervention. Magnets, however, pose a greater threat especially when more than one are ingested. We report a case of multiple bowel perforation secondary to ingestion of magnetic beads in a 3-year-old.

KEY WORDS:

Magnet ingestion, multiple bowel perforation

INTRODUCTION

Ingested foreign bodies spontaneously pass through the gastrointestinal tract in up to 90% of cases and cause serious morbidity in less than 1% of cases.¹ However, ingestion of magnets poses a greater morbidity in children particularly when more than one are swallowed.² The attractive force between 2 magnets in different parts of the bowel can cause bowel wall entrapment and potentially result in bowel wall ischemia and necrosis due to pressure, which can lead to fistula formation, bowel perforation or intestinal obstruction.^{2,3} Unwitnessed magnet ingestion in children and radiological misinterpretation of attracted or aligned multiple magnets from different locations as a single clumped entity can lead to delayed intervention and result in greater morbidity.⁴ In this report, we present one such case with complications ensuing unwitnessed ingestion of 15 magnetic beads in a 3-year-old boy and discuss the possible management scenarios for multiple magnet ingestion.

CASE REPORT

A 3-year-old boy was brought to the emergency department for frequent vomiting for two days associated with abdominal pain. The vomitus was initially clear but became coffee ground on the second day. He had no associated fever, diarrhoea or abdominal distension. He was initially treated as acute gastroenteritis by the paediatricians, and subsequently referred to us when the symptoms gradually worsened. Otherwise he had no significant past medical or surgical history. Upon examination, the child appeared dehydrated. He was afebrile. Abdomen was mildly distended with generalised tenderness and guarding. Plain abdominal radiograph revealed a radiopaque foreign body in the upper abdomen resembling a string of beads. There was minimal bowel dilatation and no evidence of pneumoperitoneum. Total white blood cells count was raised ($18.2 \times 10^9/L$),

predominantly neutrophilic (83%). Haemoglobin level was 14.4 g/dL and serum electrolytes were normal. Broad spectrum antibiotics were started and boluses of Hartmann's solution given for resuscitation.

Upon further enquiry, it was apparent that the foreign body ingestion was unwitnessed and his parents were unsure of the nature of the foreign body and timing of ingestion. Subsequently, his parents found a cluster of magnetic beads at home which resembled the foreign body on the radiograph. He was then prepared for an emergent exploratory laparotomy. Oesophagogastroduodenoscopy was initially performed and one magnetic bead was visualised in the stomach wall but endoscopic retrieval failed. Exploratory laparotomy was performed via a right upper transverse incision. There was no faecal contamination seen upon entry. Multiple magnetic beads were identified attracted to each other entrapping segments of bowel involving the anterior stomach wall, a few loops of small bowel and the caecum. The pressure effect was seen at the entrapped bowel walls, all appearing necrotic and slough laden, which easily desloughed upon dismantling the attracted magnetic beads exposing multiple bowel wall perforations. A total of 15 magnetic beads were retrieved completely from the perforated sites and absence of any other beads was counter checked using the image intensifier. Primary repair with interrupted absorbable sutures in a single layer was performed followed by peritoneal irrigation with sterile water. The patient recovered well postoperatively. Oral intake was commenced on day three post-surgery and he was discharged home well within a week. At six months follow up, he was satisfactorily well with no complaints.

DISCUSSION

Magnetic foreign body ingestion poses a significant health hazard, especially among children. The increasing use of small attractive magnets in toys or as part of various household accessories, make it easily accessible to the children. An analysis from US National Electronic Injury Surveillance System (NEISS) showed the incidence of emergency department visits for possible magnet ingestion in children less than 18 years of age has increased 8.5 fold within ten years (year 2002 to 2011), and 54.7% of them were younger than five years.² These young children are vulnerable to more severe complications because the ingestion can go completely unnoticed and they may present with nonspecific symptoms.

This article was accepted: 22 April 2016

Corresponding Author: Mohd Yusran Othman, Hospital Kuala Lumpur, Paediatric Surgery, Paediatric Institute, Jalan Pahang, Kuala Lumpur, Kuala Lumpur 50586, Malaysia

Email: yusranothman@gmail.com

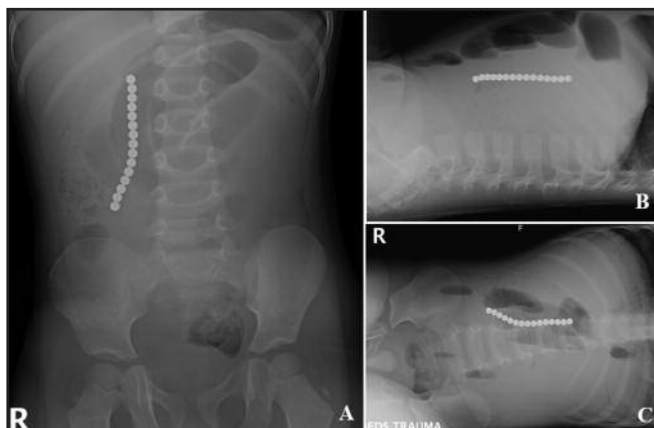


Fig. 1: Plain abdominal radiograph showing radiopaque foreign body resembling a string of beads. There is no evidence of pneumoperitoneum.

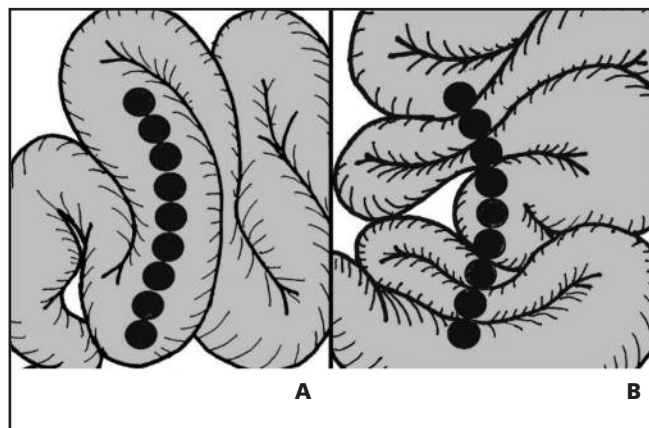


Fig. 2: Attached multiple magnets can be easily misinterpreted as a single entity in a single lumen (A) when they are actually in different bowel sites, attracted to each other causing bowel wall entrapment (B).

In 2012, the North American Society of Pediatric Gastroenterology, Hepatology, and Nutrition (NASPGHAN) described a comprehensive algorithm for the management of ingested magnets in children.⁴ Regardless of size and shape, it is the number of ingested magnets that matter. After confirmation of an ingested foreign body on plain radiograph, the number of magnets ingested need to be determined; either a single magnet or multiple magnets or a single magnet co-ingested with another metallic object. Plain radiograph needs to be carefully evaluated because multiple magnets which adhere to each other can be misdiagnosed as being in continuity within a single lumen (Figure 2) and thus multiple radiologic views are sometimes necessary.⁴

Single magnet ingestion which passes beyond the oesophagus and pylorus can be safely managed conservatively. If accessible, endoscopic removal is recommended if the child is thought to be at risk for further ingestion.⁴ It can spontaneously pass through the gastrointestinal tract without morbidity unless it gets lodged in the appendix or a diverticulum.² It is recommended that children should not come into close contact with metal objects such as metal buttons or belt buckles and serial x-rays can be done as an outpatient.⁴

Ingestion of multiple magnets or a single magnet co-ingested with other metallic objects need urgent attention because of the risk of bowel injury. Clumped magnets may behave like a single foreign body which may spontaneously pass through without a complication. However, separated multiple magnets along the bowel can attract each other trapping the bowel wall in between them causing perforation or fistula formation due to pressure necrosis.⁵ Careful evaluation is needed to identify this condition. Urgent removal needs to be planned if the bowel is thought to be at risk of injury. Endoscopic removal can be attempted if all the objects are accessible but once they passed beyond the stomach, the

surgeon should be immediately notified.⁴ Significant bowel injury due to this pressure effect can be seen as early as eight hours and bowel perforation following multiple magnets has been reported in up to 50%.^{4,5} As in our case, timing of injury was uncertain because the incidence was unwitnessed. The attracted magnetic beads was initially thought to be in a single lumen but upon exploration, the 15 magnetic beads were widely spread from the stomach down till the caecum, attracted to each other and causing multiple bowel perforations. This would explain why the initial attempt at endoscopic retrieval failed; we were tugging at literally ‘the tip of the iceberg’. Fortunately, all the perforations were repaired primarily without requiring bowel resection and his postoperative recovery was uneventful.

CONCLUSION

Single magnet ingestion is generally safe but if it is coupled with another metallic object or if multiple magnets are consumed, the risk of bowel injury is very high. Thus, we recommend immediate surgical referral for early assessment and appropriate intervention.

REFERENCES

1. Chung S, Forte V, Campisi P. A Review of Pediatric Foreign Body Ingestion and Management. *Clin Pediatr Emerg Med.* 2010; 11(3): 225-30.
2. Abbas MI, Oliva-Hemker M, Choi J, et al. Magnet Ingestions in Children Presenting to US Emergency Department, 2002-2011. *J Pediatr Gastroenterol Nutr.* 2013; 57(1): 18-22.
3. Naji H, Isacson D, Svensson JF, Wester T. Bowel injuries caused by ingestion of multiple magnets in children: A growing hazard. *Pediatr Surg Int.* 2012; 28(4): 367-74.
4. Hussain SZ, Bousvaros A, Gilger M, et al. Management of ingested magnets in children. *J Pediatr Gastroenterol Nutr.* 2012; 55(3): 239-42.
5. Tavares MM, Saladino RA, Gaines BA, Manole MD. Prevalence, Clinical Features and Management of Pediatric Magnetic Foreign Body Ingestions. *J Emerg Med.* 2012; 44(1): 261-8.