

ORIGINAL ARTICLE

P16INK4a: a potential diagnostic adjunct for prediction of high-grade cervical lesions in liquid-based cytology: with HPV testing and histological correlation

Yin Ping WONG, Sayyidi Hamzi ABDUL RAUB, Ahmad Zailani Hatta MOHD DALI*, Fauziah KASSIM**, Vicknesh VISVALINGAM***, Zubaidah ZAKARIA****, Muhammad Amir KAMALUDDIN*****, Sharifah NOOR AKMAL

*Departments of Pathology, *Obstetrics and Gynaecology, Universiti Kebangsaan Malaysia Medical Centre, Kuala Lumpur, Malaysia, **Departments of Pathology, ***Obstetrics and Gynaecology, Hospital Kuala Lumpur, Kuala Lumpur, Malaysia, and ****Cancer Research Centre, *****Environmental Health Research Centre, Institute for Medical Research, Kuala Lumpur, Malaysia*

Abstract

Human papillomavirus (HPV) is a necessary cause of cervical cancer and its precursors. Increased expression of high-risk hrHPV viral oncogenes in abnormal cells might increase the expression of p16INK4a. We aimed to determine the role of p16INK4a in detecting hrHPV-transformed epithelial cells in liquid-based cervical cytology, and compared the results with hrHPV DNA testing by real-time polymerase chain reaction (RT-PCR). Fifty-seven cytological samples were tested for p16INK4a immunomarker and hrHPV DNA. Test performance of both tests was determined by comparing sensitivity, specificity and predictive values using available histological follow-up data as gold standard. Of 57 samples, 36 (63.2%) showed immunoreactivity for p16INK4a and 43 (75.4%) were hrHPV-infected. A fairly low concordance rate ($k = 0.504$) between p16INK4a immunolabelling and hrHPV DNA status was noted. For prediction of cervical intraepithelial neoplasia (CIN) II and worse lesions, p16INK4a had a sensitivity and specificity of 93.5% and 60%; whereas hrHPV DNA testing had a sensitivity and specificity of 100% and 20%. Dual testing by combining p16INK4a and hrHPV showed sensitivity and specificity of 100% and 33.3%. In conclusion, p16INK4a is useful in predicting severity of the cytological abnormalities. Although p16INK4a is more specific but less sensitive than hrHPV in detecting high-grade cervical lesions, a combination of both tests failed to demonstrate significant improvement in diagnostic sensitivity, specificity and predictive value. Larger-scale prospective studies are required to assess further whether this biomarker should be routinely used as primary screening tool independently or in combination with hrHPV testing to improve diagnostic accuracy in cervical cytology.

Key words: p16INK4a, human papillomavirus, ThinPrep, liquid-based cytology, cervical dysplasia

INTRODUCTION

Incidence and mortality resulting from cervical cancer has decreased dramatically following the implementation of conventional Papanicolaou (Pap) test cytological screening for detection of cervical precancerous lesions since 1940s. Nevertheless, studies have demonstrated the test's imperfections, including high false negative rate (20–30%) and interobserver and interpretive discrepancies in the diagnosis of cervical lesions, especially within the atypical squamous cells of undetermined significance (ASC-US) and low-

grade squamous intraepithelial lesions (LSIL) diagnostic categories.¹ Liquid-based cytology (LBC), although claimed to provide clearer background and better preservation of nuclear and cytoplasmic details, have yet to be proven to have better sensitivity and specificity for identification of high-grade cervical intraepithelial lesions compared to the conventional smears.²

High-risk human papillomavirus (hrHPV) strains are detected in virtually all cervical cancer cases and are responsible for its development. DNA testing for hrHPV recently has gained

Address for correspondence: Prof. Dr. Sharifah Noor Akmal, Department of Pathology, Faculty of Medicine, Universiti Kebangsaan Malaysia Medical Center, Jalan Yaacob Latiff, Bandar Tun Razak, 56000 Cheras, Kuala Lumpur, Malaysia. Tel: +603-91455356. Fax: +603-91456676. Email: sharifah@pukm.ukm.edu.my

worldwide acceptance as additional primary screening for selected age groups, triage of equivocal cytology results (ASC-US) and post-treatment surveillance tools. Mayrand *et al*³ in their large scale randomised control trial reported that hrHPV DNA testing had greater sensitivity than Pap test at the expense of specificity for detecting high-grade cervical lesions (cervical intraepithelial neoplasia grade II and above). This resultant higher rate of false positive test results, may impose significant adverse psychosocial implications on HPV+ women, besides subjecting them to unnecessary and costly colposcopy and possible surgical intervention. Furthermore, detection of hrHPV DNA merely shows the presence of virus,⁴ and cannot delineate between transient and potentially transforming chronic persistent infection. The distinction between the two types of infection is crucial as persistent viral infection is essential for the progression of cervical cancer precursors to invasive lesions.⁴ Hence, there is a demand for reliable, promising and yet cost effective alternative biomarkers that can accurately identify potentially treatable precancerous cervical lesions.

p16INK4a, one of the tightly regulated cyclin-dependent kinase (CDK) inhibitors, is overexpressed in hrHPV transformed cells.^{5,6} Physiologically, p16INK4a inhibits CDK4 and CDK6 that phosphorylate retinoblastoma (Rb) protein (pRb). Hypophosphorylated pRb allows complex with E2F transcription factors, halting cell cycle in G1 phase.

In cells with transforming HPV infections, viral oncoproteins E6 and E7 integrate into the host genome and interfere with cell cycle control mechanisms by interacting with cell cycle-regulatory proteins, particularly p53 and pRb.⁷⁻⁹ The E6 oncoproteins stimulate ubiquitinylation and proteasome-dependent degradation of p53 tumour suppressor protein, disabling apoptosis and promote tumourigenesis. The E7 oncoproteins bind to pRb, prevent its binding to E2F transcription factors and consequently promotes G1/S phase of cell cycle progression. Functional inactivation of pRb leads to reflex upregulation of p16INK4a to counteract the irregular cell cycle activation as part of negative transcriptional feedback mechanism. As a result, p16INK4a accumulates in nuclei and cytoplasm of the infected cells and can be readily detected by immunohistochemical testing.¹⁰

The aim of our study was to determine the diagnostic role of the potential surrogate marker, p16INK4a, in detecting hrHPV-transformed

epithelial cells in liquid-based cervical cytology and to compare its sensitivity, specificity, positive predictive value (PPV) and negative predictive value (NPV) with hrHPV DNA testing for detection of high-grade cervical squamous and glandular lesions with follow-up histological diagnosis as gold standard.

MATERIALS AND METHODS

Case selection

This is a multi-centre, retrospective study using liquid-based cytology (ThinPrep, Hologic, USA) samples obtained from 57 women between the ages of 23 to 84 years (mean age of 49.6 years) who attended Universiti Kebangsaan Malaysia Medical Centre (UKMMC) and Hospital Kuala Lumpur (HKL) for routine gynaecological screening for a study period of two years. The cytological samples were assessed and interpreted using the Bethesda system (TBS) of 2001.¹¹ The cytological diagnostic categories were represented as follows: negative for intraepithelial lesion or malignancy (NILM; n=10), atypical squamous cells of undetermined significance (ASC-US; n=5), low-grade squamous intraepithelial lesion (LSIL; n=10), atypical squamous cells, high-grade lesion cannot be excluded (ASC-H; n=3), high-grade squamous intraepithelial lesion (HSIL; n=19), squamous cell carcinoma (SCC; n=2), atypical glandular cell (AGC; n=5) and adenocarcinoma (ADC; n=3). Relevant patients' clinical data as well as follow up cervical biopsy results, if available, were retrieved from the laboratory information system of the respective hospitals. The study was approved by the local ethics committee (FF-179-2010 and 06-CAM-01-05).

Sample preparation and processing

Residual ThinPrep sample volume obtained from all studied subjects was reassessed to ensure sufficient material for preparation of two cytology slides and for hrHPV DNA testing. The two ThinPrep cytology slides were prepared according to manufacturer's instruction using a T2000 slide processor (Hologic) and the remaining liquid specimen was subjected to hrHPV DNA testing. All samples were processed within six weeks from the date of specimen collection. Inadequate sample volume for slides preparation was excluded from the study.

The first ThinPrep cytology slide was stained with Papanicolaou stain. It was then screened independently by a cytotechnologist

and a cytopathologist in a blinded manner and a consensus cytological diagnosis was reached. The second cytology slide was processed preceding antibody staining as follow: slide was incubated in 95% ethanol bath for 20 minutes, air dried overnight until immunocytochemistry staining the following day.

P16INK4a immunocytochemistry staining

Immunostaining for p16INK4a was performed on ThinPrep slides using commercially available CINtec p16INK4A Cytology Kit (K5340, Dako, Denmark) according to the manufacturer's instructions. The slides were incubated in 50% ethanol for five minutes, followed by washing step in distilled water and immersed in wash buffer for rehydration purposes. The slides subsequently underwent heat-induced antigen retrieval with preheated 10 mM citrate solution at 95°C for 40 minutes, and then left to cool for 20 minutes at room temperature. In preparation for immunostaining, the slides were briefly rinsed in distilled water, placed in wash buffer for five minutes and covered with peroxidase-blocking reagent for another five minutes. This was followed by a two-step immunocytochemical procedure where the slides were incubated with primary p16INK4a antibody (clone E6H4) for 30 minutes. In a next step, the slides were left for incubation with the polymer visualisation reagent for 30 minutes, two five-minute incubations with chromogen diaminobenzidine (DAB) substrate (Dako) before subjected for counterstained with Papanicolaou. A control slide (mtm laboratories AG) containing known p16INK4a immunopositive and -negative control cells was used for each automated immunocytochemistry run.

Interpretation of p16INK4a immunocytochemistry stain

P16INK4a-stained slides were initially screened by a cytotechnologist to locate and identify potentially abnormal cells (regardless whether the brown positive staining was in nucleus, cytoplasm or both). Those p16INK4a-positive slides were subsequently evaluated and carefully scored by a cytopathologist based on four-tiered nuclear cytomorphological grading system proposed by Wentzensen *et al.*¹² Briefly, individual nucleus was assessed for presence of any morphologic abnormalities e.g. increased nuclear/cytoplasmic ratio, altered chromatin, altered nuclear shape or anisonucleosis and was given score 1 to 4 (where 1 = mere presence of p16INK4a+ cells without any nuclear abnormality; 2 = p16INK4a+

cells that display only one nuclear abnormality as mentioned above; 3 = p16INK4a+ cells that exhibit increased nuclear/cytoplasmic ratio and any one additional nuclear abnormality; 4 = p16INK4a+ cells that demonstrate increased nuclear/cytoplasmic ratio and more than one additional nuclear abnormalities). A score of 0 was rated for cases without any p16INK4a-positive cells. Any one nucleus with score ≥ 2 was regarded as positive. Staining intensity was not taken into account in determining a p16INK4a-positive result.

DNA extraction and hrHPV detection

DNeasy Blood and Tissue Kit (Qiagen, Germany) was used for DNA extraction from ThinPrep cervical samples according to manufacturer's protocol. Samples were first lysed using proteinase K. The lysate was subsequently loaded into DNeasy spin columns for centrifugation to remove contaminants. Pure DNA was then eluted in low salt buffer after two efficient wash steps. Optical density (OD) was measured using ND-1000 spectrophotometer (NanoDrop, Wilmington DE, USA) to confirm high purity of DNA (within ratios of 1.7 – 1.9). The extracted DNA was stored in -20°C until further analysis with quantitative real-time polymerase chain reaction (RT-PCR).

HPV genotyping was performed by RT-PCR using SACACE HPV High Risk Typing Real-TM kit (Sacace Biotechnologies, Italy), an *in vitro* Real Time amplification test for qualitative detection and genotyping of hrHPV (16, 18, 31, 33, 35, 39, 45, 51, 52, 56, 58, 59), targeting on E7 viral oncogene. Multiplex amplification reaction was performed in a reaction volume of 13 μ l containing 8 μ l of reaction mix (PCR-mix-1, PCR-buffer FRT, Hot Start DNA Polymerase) and 5 μ l of extracted DNA sample. The reaction was carried out for 45 cycles under the following conditions: 15 minutes at 95°C, 20 seconds at 95°C and 60 seconds at 60°C using Real-Time PCR Stratagene MX3000P (La Jolla, CA). Data obtained from RT-PCR was then keyed-in to a software (Microsoft® Excel HPV Typing Real-Time MX Results Matrix.xls) provided together with the kit and was interpreted.

Statistical analysis

Statistical analysis was conducted using Statistical Package for Society Study (SPSS) version 21.0 statistic software (Chicago, IL, USA). Chi square, χ^2 test was used to analyse correlation between variables. Cohen's Kappa (*k*)

was used to measure the degree of agreement between variables beyond chance. Values of *k* of less than 0.40 indicate poor agreement, values between 0.40 and 0.75 indicate fair to good agreement and values greater than 0.75 indicate excellent agreement between the two variables. We considered *P* value of less than 0.05 as statistically significant. Sensitivity, specificity and predictive value of the test (p16INK4, hrHPV DNA testing) were calculated, considering follow-up biopsy results as gold standard.

RESULTS

In the present study, we analysed p16INK4a overexpression and hrHPV infection in 57 routine screening ThinPrep cytology specimens. Of 47 abnormal cervical smears, P16INK4a immunoreactivity and hrHPV DNA positivity were demonstrated in 76.6% (36/47) and 87.2% (41/47) of 47 abnormal cervical smears. We also found that 20% cases with NILM showed hrHPV DNA positivity and were all negative when tested with p16INK4a immunostain.

Table 1 summarises the results of p16INK4a labelling and hrHPV status in different diagnostic categories. In brief, 0% cases of NILM (0/10), 20% cases of ASC-US (1/5), 55.5% cases of LSIL (5/9), 100% cases of ASC-H (3/3), 90% cases of HSIL (18/20), 100% cases of SCC (2/2), 80% cases of AGC (4/5) and 100% cases of ADC (3/3) displayed p16INK4a immunoreactivity; whereby hrHPV DNA was detected in 20% cases of NILM (2/10), 80% cases of ASC-US (4/5), 66.7% cases of LSIL (6/9), 100% cases of ASC-H (3/3), HSIL (20/20) and SCC (2/2), 60% cases of AGC (3/5) and 100% cases of ADC

(3/3). Interestingly, we observed an increasing frequency of samples overexpressing p16INK4a and hrHPV DNA with increasing severity of cervical lesions (from average of 0 - 20% in NILM to 100% in SCC and ADC).

Figure 1 illustrates the prevalence of hrHPV infections in various diagnostic categories among the studied population. Of 43 hrHPV-infected cases, majority (79.1%) was infected by multiple HPV genotypes and only 9 (20.9%) by single HPV genotype. In our study, we found that HPV-16 being the most frequent HPV genotype, representing 53.2% of all HPV infections, mostly (96.0%) in a form of multiple infections. This was followed by HPV-18 (34.0%), HPV-33 (17.0%), HPV-31 (14.9) and HPV-39 (14.9%) in descending order of prevalence.

Relationship between p16INK4a labelling and hrHPV infections

Of the 43 cases which showed hrHPV positivity, 34 (79.0%) expressed p16INK4a immunoreactivity; whereas 12 (85.7%) of 14 hrHPV-negative cases were also p16INK4a negative. In remaining 11 (19.3%) of 57 cases in which no correlation between p16INK4a expression and hrHPV results were demonstrated, 9 (15.7%) were hrHPV-positive but lacked p16INK4a overexpression, and 2 (3.5%) expressed p16INK4a but were negative for hrHPV DNA (*k* = 0.504; *P* < 0.0001).

Correlation between p16INK4a labelling and hrHPV infections for all cytologic diagnostic categories is shown in Table 2. For individual diagnostic categories, we found excellent correlation (100%) between p16INK4a

TABLE 1: Results of p16INK4a immunolabelling and hrHPV status in various cytological categories

Cytological Categories	No of Samples (n)	P16 ^{INK4A}				HPV DNA			
		Positive		Negative		Positive		Negative	
		N	(%)	N	(%)	N	(%)	N	(%)
NILM	10	0	(0.0)	10	(100.0)	2	(20.0)	8	(80.0)
ASCUS	5	1	(20.0)	4	(80.0)	4	(80.0)	1	(20.0)
LSIL	9	5	(55.6)	4	(44.4)	6	(66.7)	3	(33.3)
ASC-H	3	3	(100.0)	0	(0.0)	3	(100.0)	0	(0.0)
HSIL	20	18	(90.0)	2	(10.0)	20	(100.0)	0	(0.0)
SCC	2	2	(100.0)	0	(0.0)	2	(100.0)	0	(0.0)
AGC	5	4	(80.0)	1	(20.0)	3	(60.0)	2	(40.0)
ADC	3	3	(100.0)	0	(0.0)	3	(100.0)	0	(0.0)
Total	57	36		21		43		14	

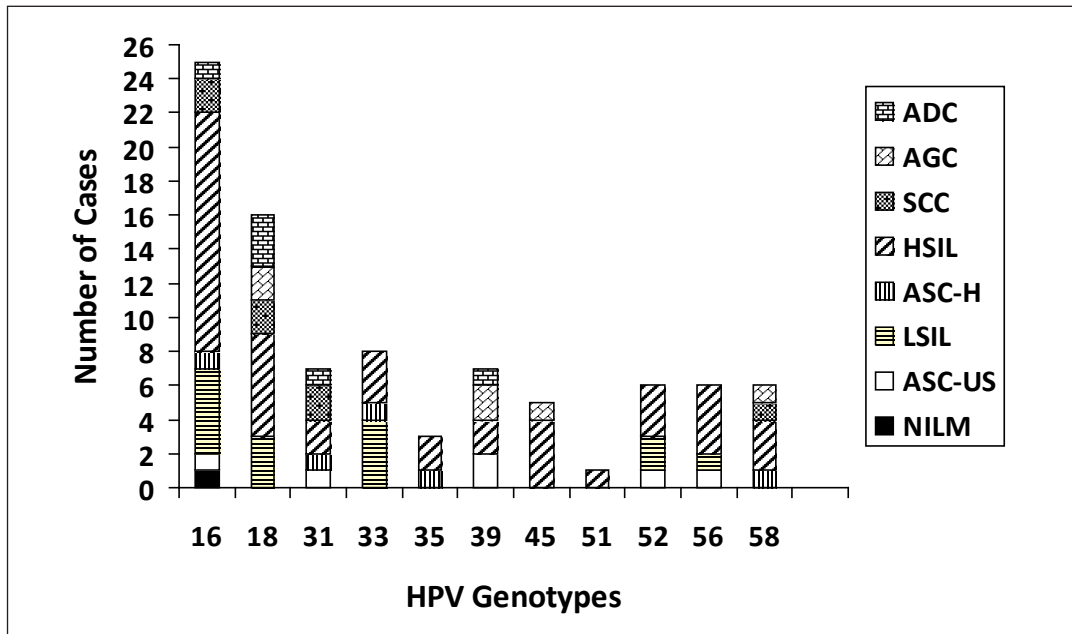


FIG. 1: The bar chart illustrates prevalence of high-risk human papillomavirus (hrHPV) infections in various cytological diagnostic categories among studied population. HPV-16 is the most frequent HPV genotype detected, representing 53.2% of all HPV infections. This was followed by HPV-18 (34.0%), HPV-33 (17.0%), HPV-31 (14.9) and HPV-39 (14.9%). (Abbreviations: NILM, negative for intraepithelial lesion or malignancy; ASC-US, atypical squamous cells of undetermined significance; LSIL, low-grade squamous intraepithelial lesion; ASC-H, atypical squamous cells, high-grade lesion cannot be excluded; HSIL, high-grade squamous intraepithelial lesion; SCC, squamous cell carcinoma; AGC, atypical glandular cell; ADC, adenocarcinoma).

expression and hrHPV results in ASC-H, SCC and ADC. Of 10 NILM cases, 8 (80%) were both hrHPV and p16INK4a negative, and remaining 2 were hrHPV positive but p16INK4a negative. Of 5 ASC-US cases, only one (20%) showed p16INK4a overexpression. Interestingly, 2 (50%) out of 4 ASC-US cases which lacked p16INK4a overexpression showed hrHPV positivity. In 6 of 9 hrHPV-positive LSIL, 2 (33.3%) were p16INK4a negative. Of all 20 hrHPV-positive HSIL cases, 18 (90%) expressed p16INK4a immunopositivity and lacking in remaining 2 (10%) cases. Of 5 AGC cases, 4 (80%) showed

p16INK4a overexpression, of which 3 were also hrHPV infected.

Correlation between cytological and histological diagnoses

To determine accuracy of the cytomorphological diagnosis of ThinPrep samples from studied population, we compared cytological results with subsequent follow-up histological diagnoses from cervical biopsies/resection specimen (Table 3). As expected, no follow-up biopsy was performed for cases within the NILM cytological categories. A total of 21 (36.8%)

TABLE 2: Relationship between p16INK4a labelling and hrHPV infections

	NILM	ASC-US	LSIL	ASC-H	HSIL	SCC	AGC	ADC
P16+/HPV+	0	1	4	3	18	2	3	3
P16+/HPV-	0	0	1	0	0	0	1	0
P16-/HPV+	2	3	2	0	2	0	0	0
P16-/HPV-	8	1	2	0	0	0	1	0
Total	10	5	9	3	20	2	5	3

TABLE 3: Correlation between cytological and histological diagnoses

Cytological Categories	Histological Diagnoses (%)				
	Negative	CIN I	CIN III	SCC	ADC
LSIL	1 (33.3)	2 (100.0)	0	0	0
HSIL	2 (66.7)	0	9 (100.0)	2 (50.0)	0
SCC	0	0	0	2 (50.0)	0
ADC	0	0	0	0	3 (100.0)
Total	3 (100.0)	2 (100.0)	9 (100.0)	4 (100.0)	3 (100.0)

available biopsies were obtained from 47 study subjects with abnormal cytological results. These included 3 from LSIL samples, 13 from HSIL samples, 2 from SCC samples and 3 from ADC samples. Of these, 3 biopsy specimens showed reactive changes, 2 CIN I, 9 CIN III, 4 SCC and 3 ADC cases. No cytohistological discrepancies existed for malignant cases (SCC, ADC) with 100% concordance rate.

Intriguingly, of 3 cases that were histologically proven as reactive changes with squamous metaplasia, 1 was cytologically categorised as LSIL and 2 over-reported as HSIL. A review of those two over-reported HSIL cases showed possible squamous metaplastic cells displaying mild regenerative atypia, almost impossible to

distinguish confidently from HSIL; whereby the one case which was over-diagnosed as LSIL indeed showed definite low-grade SIL changes. Interestingly, both HSIL cases showed p16INK4a overexpression and hrHPV positivity.

Correlation among p16INK4a labelling, hrHPV DNA, cytological diagnosis with histological findings

We then compared p16INK4a immunolabelling and hrHPV status with the available histological follow-up data to further assess their clinical performance (Figure 2). For all cytological categories, of 16 cases diagnosed as CIN II and above, 15 were p16INK4a positive, yielding a diagnostic sensitivity of 93.8% (95% confidence

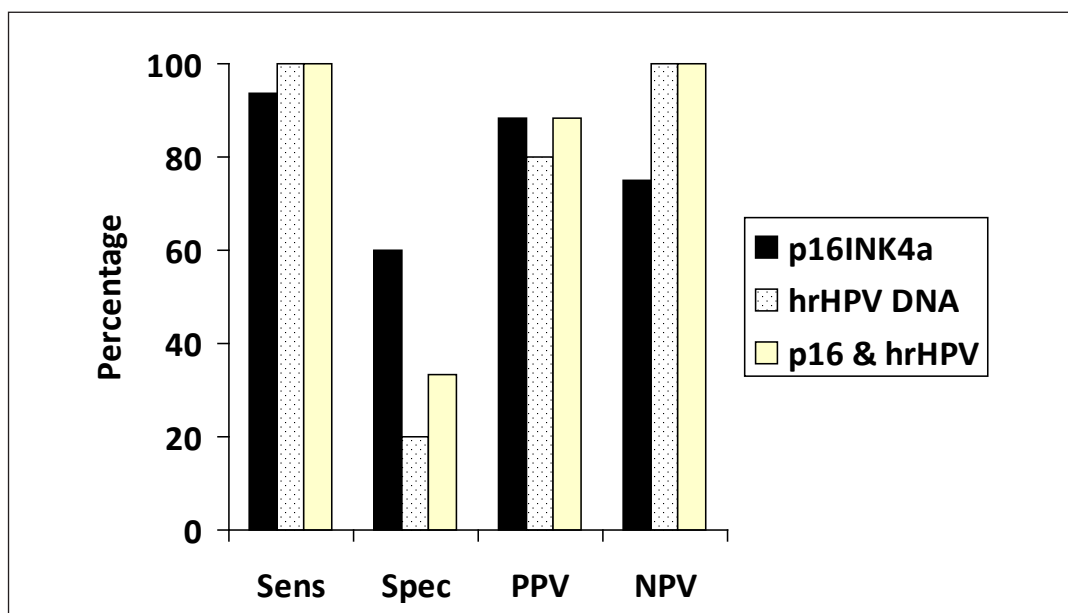


FIG. 2: The bar chart compares sensitivity, specificity, PPV and NPV between p16INK4a labelling, hrHPV DNA testing and combination of both tests, considering follow-up histological diagnosis of cervical intraepithelial neoplasia (CIN) II or worse as gold standard. Molecular testing for hrHPV DNA is more sensitive but less specific than p16INK4a in its ability to detect high-grade cervical lesions. (Abbreviation: Sens, sensitivity; Spec, specificity; PPV, positive predictive value; NPV, negative predictive value).

interval: 69.7 – 98.9); and 3 of 5 cases with follow-up biopsy of \leq CIN I were found negative for p16INK4a, yielding a diagnostic specificity of 60% (95% confidence interval: 15.4 – 93.5). The positive predictive value (PPV) and negative predictive value (NPV) for p16INK4a immunolabelling were 88.2% and 75.0% respectively.

By comparison, hrHPV DNA testing yielded higher diagnostic sensitivity of 100% (95% confidence interval: 79.3 – 100.0) with all (16/16) CIN II and above biopsy specimens tested positive for hrHPV DNA. However, it had a lower diagnostic specificity of only 20.0% (95% confidence interval: 3.3 – 71.2) with only 1 of 5 histologically confirmed \leq CIN I cases showed hrHPV DNA negativity. PPV and NPV for hrHPV DNA testing were 80% and 100% respectively. With the combination of both p16INK4a and hrHPV DNA test results, we found no significant increment in sensitivity (100%) but a decrement in specificity to 33.3% was noted, compared to testing with just hrHPV or p16INK4a alone.

DISCUSSION

In the present study, we evaluated the feasibility of p16INK4a in detecting hrHPV-transformed epithelial cells in cervical smears using ThinPrep technology, and at the same time, to determine its additional benefit (sensitivity, specificity, PPV, NPV) compared to hrHPV DNA testing by RT-PCR method using follow-up cervical biopsies as gold standard.

Among the available biomarkers for detection of precancerous high-grade cervical lesion (HPV, MIB-1, ProEx C, L1, PIK3Ca, TRT-H239), p16INK4a has been reported as one of the most promising and potential immunomarkers since its first introduction in 2002. Although few studies demonstrated otherwise, our findings were in agreement with the majority where p16INK4a expression were correlated to the degree of cervical atypia. Tsoumpou *et al*¹³ in their meta-analysis on 61 pooled studies revealed that among the normal smears, only 12% showed p16INK4a immunopositivity, compared to 45% and 89% for ASCUS/LSIL and HSIL smears respectively.

A recent study discovered an astonishingly high prevalence of HPV infections among Malaysian women, compared with generally a lower prevalence reported among healthy Asian women (46.7% vs 14%).¹⁴ A meta-analysis performed on one million women with normal cytology revealed an overall

HPV prevalence of 24.0% in Sub-Saharan African regions, 16.1% in Latin America and the Caribbean and 14.2% in Eastern Europe.¹⁵ This was comparable to our finding (20%). HPV-16 and -18 have been recognised as the most prevalent genotypes worldwide and most carcinogenic,¹⁶ which account for 70% of cervical cancer. Correspondingly, HPV-16 infection was associated with 70% of HSIL and 100% of SCC cases in our studied population.

Notably, our study demonstrated multiple hrHPV infections of at least two hrHPV genotypes occurred in 79.1% cases, particularly high-grade cervical lesions. This observation strengthened the postulation that multiple concurrent HPV infections act synergistically in cervical carcinogenesis.^{17,18}

In present study, we demonstrated a relatively low concordance rate ($k = 0.504$) between p16INK4a overexpression and hrHPV infections in ThinPrep cervical specimens. Few other studies by Nasioutziki *et al*¹⁹ and Benevolo *et al*²⁰ drew similar conclusions. Some observed that all p16INK4a+ cases showed the presence of hrHPV infections; although not all hrHPV+ cases demonstrated p16INK4a overexpression. They concluded that p16INK4a overexpression may serve as an indicator for cervical carcinogenesis, regardless of HPV status.^{21,22} Intriguingly, we found evidence of hrHPV infections in 60% of ASCUS samples, all of which showed p16INK4a immunonegativity. It was unfortunate that those cases were not followed by cervical biopsy. It would have been interesting to have a tissue confirmation of those hrHPV+ but cytological equivocal cases.

Many previous studies criticised the clinical performance of conventional Pap smears for their imperfect sensitivity and hampered interobserver variability.²³ Over-reporting of LSIL and HSIL in three histologically proven normal cases were observed in the present study. Similarly, Yeoh and Chan²⁴ revealed a relatively low concordance rate of 63.9% and 74.6% for LSIL and HSIL respectively. The possible causes of false positive HSIL reporting were attributed to sampling error during colposcopy, atrophy, immature squamous metaplasia, unrecognised endometrial cells, histiocytes or endocervical polyp atypia.²⁵ The so-called false positive LSIL in one of our cases indeed demonstrated cytological abnormalities upon second review. This could be resultant from missed sampling during colposcopy or likelihood of spontaneous resolution of the lesion during the follow-up period.

Of interest is that those two false positive HSIL cases showed positivity when tested with p16INK4a and hrHPV DNA. As suggested in some p16INK4a literature, p16INK4a is sporadically expressed in occasional normal, atrophic, metaplastic squamous cells, endocervical cells, inflammatory cells and bacteria.²⁵ Moriarty²⁶ criticised p16INK4a being a visual method and was subjected to poor interobserver reliability and reproducibility.

Of 28 published data that evaluated the use of p16INK4a immunostaining in liquid-based cytology samples, four came to negative conclusions and denied its routine use, as p16INK4a did not produce additional benefits in identifying high-grade cervical lesions compared with the existing conventional Pap smears and hrHPV DNA testing. The vast discrepancies between those studies might be attributed to a lack of standardised interpretation method of immunostaining being performed and this issue needed to be further addressed. Some authors suggested a scoring system that rely on well-established cytomorphological criteria for HSIL might increase test specificity.²⁷

In the present study, we applied nuclear morphological scoring system proposed by Wentzsen *et al.*¹² Our results demonstrated that p16INK4a was more specific (60.0% vs 20.0%) but less sensitive (93.5% vs 100.0%) than hrHPV in its ability in detecting high-grade cervical lesions (\geq CIN II). This is in agreement with other previous reports of p16INK4a test performance with sensitivity and specificity ranged from 67 – 89.5% and 56.2 - 100% respectively.^{20,28,29}

To date, very few literature have analysed the correlation between p16INK4a protein expression and demonstratable hrHPV infections. Ekalaksananan *et al.*²⁸ reported that combined testing with p16INK4a and hrHPV DNA enabled prediction of high-grade cervical lesions with significant better sensitivity (93.8%) and specificity (59.2%). A higher PPV (32%) and NPV (97.1%) were also observed with combined testing, in agreement with the results of other studies.^{20,30} These findings were corroborated by Carozzi *et al.*,³⁰ who concluded that triage to colposcopy by hrHPV and p16INK4a testing was cost-effective and helped double the PPV for > CIN II to 30.5%, but at the expense of missing minority of CIN II cases. In a recent multicentre randomised controlled trial triaging HPV-positive women with p16INK4a, investigators managed to produce a significant increment in sensitivity

(88%) while maintaining specificity for high-grade cervical lesions.³¹ Interestingly, when these women (n = 1042) were followed up at yearly interval for three years, Carozzi *et al.*³² noticed that more p16INK4a-positive women with initial negative histology had progressed to CIN II or worse compared with p16INK4a-negative cases, with relative risk of 2.61.

Our results, however proved otherwise, with lower test specificity (33.3% vs 60.0%) and slightly improved test sensitivity (100% vs 93.5%) compared to testing with just p16INK4a alone. Also, similar PPV and slight increased in NPV were noted with combined testing. The variation may be the result of relatively low concordance rate between p16INK4a labelling and hrHPV DNA status among our studied population.

In conclusion, p16INK4a is a potential useful diagnostic adjunct in predicting severity of the cytological abnormalities. Although p16INK4a is more specific but less sensitive than hrHPV testing alone in detection of high-grade cervical lesions, a combination of both tests failed to demonstrate significant improvement in diagnostic sensitivity, specificity and predictive value in cervical lesions. It is worth noting that larger-scale prospective studies are required to further assess whether this biomarker should be routinely used as primary screening tool independently or in combination with hrHPV testing to improve diagnostic accuracy in cervical cytology.

ACKNOWLEDGEMENTS

The authors wish to thank the staffs of Cytopathology and Cytogenetic Unit, Department of Pathology, UKMMC and HKL, for their technical assistance and support. The current work is funded by MOH, Malaysia (06-CAM-01-05).

REFERENCES

1. Stoler MH, Schiffman M. Interobserver reproducibility of cervical cytologic and histologic interpretations: realistic estimates from the ASCUS-LSIL Triage Study. *JAMA*. 2001; 285: 1500-5.
2. Arbyn M, Bergeron C, Klinkhamer P, Martin-Hirsch P, Siebers AG, Bulten J. Liquid compared with conventional cervical cytology: a systematic review and meta-analysis. *Obstet Gynecol*. 2008; 111: 167-77.
3. Mayrand MH, Duarte-Franco E, Rodrigues I, *et al.* Human papillomavirus DNA versus Papanicolaou screening tests for cervical cancer. *N Engl J Med*. 2007; 357: 1579-88.

4. Walboomers JM, Jacobs MV, Manos MM, *et al.* Human papillomavirus is a necessary cause of invasive cervical cancer worldwide. *J Pathol.* 1998; 189: 12-9.
5. Sano T, Oyama T, Kashiwabara K, Fukuda T, Nakajima T. Expression status of p16 protein is associated with human papillomavirus oncogenic potential in cervical and genital lesions. *Am J Pathol.* 1998; 153: 1741-8.
6. Klaes R, Friedrich T, Spitkovsky D, *et al.* Overexpression of p16(INK4A) as a specific marker for dysplastic and neoplastic epithelial cells of the cervix uteri. *Int J Cancer.* 2001; 92: 276-84.
7. Munger K, Phelps WC, Bubb V, Howley PM, Schlegel R. The E6 and E7 genes of the human papillomavirus type 16 together are necessary and sufficient for transformation of primary human keratinocytes. *J Virol.* 1989; 63: 4417-21.
8. Cho NH, Kim YT, Kim JW. Alteration of cell cycle in cervical tumor associated with human papillomavirus: cyclin-dependent kinase inhibitors. *Yonsei Med J.* 2002; 43: 722-8.
9. Duensing S, Munger K. Mechanisms of genomic instability in human cancer: insights from studies with human papillomavirus oncoproteins. *Int J Cancer.* 2004; 109: 157-62.
10. Cheah PL, Looi LM, Teoh KH, Mun KS, Nazarina AR. p16(INK4a) is a useful marker of human papillomavirus integration allowing risk stratification for cervical malignancies. *Asian Pac J Cancer Prev.* 2012; 13: 469-72.
11. Solomon D, Davey D, Kurman R, *et al.* The 2001 Bethesda System: terminology for reporting results of cervical cytology. *JAMA.* 2002; 287: 2114-9.
12. Wentzensen N, Bergeron C, Cas F, Eschenbach D, Vinokurova S, von Knebel Doeberitz M. Evaluation of a nuclear score for p16INK4a-stained cervical squamous cells in liquid-based cytology samples. *Cancer.* 2005; 105: 461-7.
13. Tsoumpou I, Arbyn M, Kyrgiou M, *et al.* p16(INK4a) immunostaining in cytological and histological specimens from the uterine cervix: a systematic review and meta-analysis. *Cancer Treat Rev.* 2009; 35: 210-20.
14. Chong PP, Asyikin N, Rusinahayati M, *et al.* High prevalence of human papillomavirus DNA detected in cervical swabs from women in southern Selangor, Malaysia. *Asian Pac J Cancer Prev.* 2010; 11: 1645-51.
15. Bruni L, Diaz M, Castellsague X, Ferrer E, Bosch FX, de Sanjosé S. Cervical human papillomavirus prevalence in 5 continents: meta-analysis of 1 million women with normal cytological findings. *J Infect Dis.* 2010; 202: 1789-99.
16. Bernard E, Pons-Salort M, Favre M, *et al.* Comparing human papillomavirus prevalences in women with normal cytology or invasive cervical cancer to rank genotypes according to their oncogenic potential: a meta-analysis of observational studies. *BMC Infect Dis.* 2013; 13: 373.
17. Trottier H, Mahmud S, Costa MC, *et al.* Human papillomavirus infections with multiple types and risk of cervical neoplasia. *Cancer Epidemiol Biomarkers Prev.* 2006; 15: 1274-80.
18. Paengchit K, Kietpeerakool C, Lalitwongsa S. Prevalence and genotype distribution of HPV among women attending a cervical cancer screening mobile unit in Lambang, Thailand. *Asian Pac J Cancer Prev.* 2014; 15: 6151-4.
19. Nasioutziki M, Daniilidis A, Dinas K, *et al.* The evaluation of p16INK4a immunexpression/immunostaining and human papillomavirus DNA test in cervical liquid-based cytological samples. *Int J Gynecol Cancer.* 2011; 21: 79-85.
20. Benevolo M, Vocaturo A, Mottolese M, *et al.* Clinical role of p16INK4a expression in liquid-based cervical cytology: correlation with HPV testing and histologic diagnosis. *Am J Clin Pathol.* 2008; 129: 606-12.
21. Lin ZH, Shen XH, Jin Z, *et al.* Human papillomavirus genotyping by oligonucleotide microarray and p16 expression in uterine cervical intraepithelial neoplasm and in invasive carcinoma in Korean women. *Pathol Int.* 2005; 55: 491-6.
22. Izaaks CD, Truter EJ, Khan S. Correlative analysis of CINTEC P16 and detection of HPV DNA by PCR in cervical abnormalities. *Med Technol SA.* 2011; 25: 23-9.
23. Raab SS, Grzybicki DM. Cytologic-histologic correlation. *Cancer Cytopathol.* 2011; 119: 293-309.
24. Yeoh GP, Chan KW. The accuracy of Papanicolaou smear predictions: cytohistological correlation of 283 cases. *Hong Kong Med J.* 1997; 3: 373-6.
25. Pinto AP, Degen M, Villa LL, Cibas ES. Immunomarkers in gynecologic cytology: the search for the ideal 'biomolecular Papanicolaou test'. *Acta Cytol.* 2012; 56: 109-21.
26. Moriarty AT. p16INK4a-is the future of cervical cancer screening rosy? *Cancer Cytopathol.* 2012; 120: 291-3.
27. Trunk MJ, Dallenbach-Hellweg G, Ridder R, *et al.* Morphologic characteristics of p16INK4a-positive cells in cervical cytology samples. *Acta Cytol.* 2004; 48: 771-82.
28. Ekalaksananan T, Pientong C, Kongyingyoes B, *et al.* Combined p16INK4a and human papillomavirus testing improves the prediction of cervical intraepithelial neoplasia (CIN II-III) in Thai patients with low-grade cytological abnormalities. *Asian Pac J Cancer Prev.* 2011; 12: 1777-83.
29. Rokita W, Kedzia W, Pruski D, *et al.* Comparison of the effectiveness of cytodiagnostics, molecular identification of HPV HR and CINtecPLUS test to identify LG SIL and HG SIL. *Ginekol Pol.* 2012; 83: 894-8.
30. Carozzi F, Cecchini S, Confortini M, *et al.* Role of P16^(INK4A) expression in identifying CIN2 or more severe lesions among HPV-positive patients referred for colposcopy after abnormal cytology. *Cancer.* 2006; 108: 119-23.
31. Carozzi F, Confortini M, Dalla PP, *et al.* Use of p16-INK4a overexpression to increase the specificity of human papillomavirus testing: a nested substudy of the NTCC randomised controlled trial. *Lancet Oncol.* 2008; 9: 937-45.
32. Carozzi F, Gillio-Tos A, Confortini M, *et al.* Risk of high-grade cervical intraepithelial neoplasia during follow-up in HPV-positive women according to baseline p16-INK4a results: a prospective analysis of a nested substudy of the NTCC randomised controlled trial. *Lancet Oncol.* 2013; 14: 168-76.