

**CASE REPORT**

## Stridor in Children: Croup or Something More Sinister? A Case of Subglottic Cyst

MOHD HISHAM MI, TAN TL, FADZLON MY

*Department of Emergency Medicine, Faculty of Medicine, Universiti Kebangsaan Malaysia Medical Centre, Jalan Yaacob Latif, Bandar Tun Razak, 56000 Cheras, Kuala Lumpur, Malaysia.*

### ABSTRAK

*Dengkuran nyaring akibat sista subglotik adalah keadaan yang jarang berlaku kepada bayi. Namun, ia boleh membawa maut jika tidak dirawat dengan betul kerana boleh menyebabkan terhalangnya saluran pernafasan dan mengakibatkan komplikasi yang serius. Kepelbagaian simptom dan tanda klinikal merupakan cabaran yang sangat besar dalam mendiagnosis sista subglotik ini. Manifestasi klinikal berbeza kerana ia bergantung kepada saiz dan lokasi sista. Kami melaporkan kes seorang bayi perempuan berumur 6 bulan yang mempunyai sista subglotik tetapi telah dirawat sebagai penyakit "croup" sehingga beliau mengalami kegagalan sistem pernafasan dan kesukaran proses intubasi. Oleh itu, adalah ditekankan supaya para pegawai perubatan perlu memikirkan diagnosis sista subglotik pada bayi-bayi pramatang yang datang ke kecemasan dengan bunyi dengkuran yang nyaring serta pernah melalui proses intubasi. Selepas diagnosis yang tepat dibuat, rawatan yang sewajarnya dapat diberikan untuk mengelakkan kecacatan dan kematian.*

*Kata kunci: sista subglotik, sista larink, bayi pramatang, intubasi, kegagalan sistem pernafasan*

### ABSTRACT

Stridor in infants with subglottic cyst is rare. Mismanagement of such cases may lead to respiratory compromise with a potentially serious and fatal outcome. The diversity of the clinical presentations throws a great challenge in the diagnosis of subglottic cysts. Manifestations vary as they depend on the size and location of the cysts. We report the case of a 6-month-old girl who had a subglottic cyst but managed as moderate croup till she developed worsening respiratory acidosis which difficult intubation. Any case of premature infants with previous history of neonatal intubation presenting with stridor should prompt clinicians to look for possible cysts in the larynx. This is important because once the diagnosis is made,

**Address for correspondence and reprint requests:** Dr. Mohd Hisham Bin Mohd Isa, Department of Emergency Medicine, Faculty of Medicine, Universiti Kebangsaan Malaysia Medical Centre, Jalan Yaacob Latif, Bandar Tun Razak, 56000 Cheras, Kuala Lumpur, Malaysia. Tel: +603-91455606 Fax: +603-91456577 Email: mohimois@yahoo.com

appropriate treatment may be given and unnecessary morbidity and mortality may be avoided.

Keywords: subglottic cysts, laryngeal cysts, premature infant, endotracheal intubation, airway obstruction

---

## INTRODUCTION

Stridor in children with subglottic cyst is rare. It is one of the potential life threatening conditions seen in the Emergency Department (ED), which jeopardize the airway. An acquired subglottic cyst is a condition resulting from previous trauma to glottic mucosa during intubation (Agada et al. 2006). Its clinical manifestations vary considerably from being asymptomatic to an airway obstruction and respiratory failure. Therefore, high index of suspicion is the key to early identification for prompt intervention from multidisciplinary teams. We highlight an important but an under-recognised case of acquired post-intubation subglottic cyst during a neonatal period presenting with stridor. The challenges encountered for identification and management of this case are being discussed.

## CASE REPORT

A 6-month-old baby girl, presented to ED of an academic hospital at day 3 of illness for worsening stridor with cough, rhinorrhea and poor oral intake. However, she had no fever. She was born prematurely at 27 weeks. Her birth weight was 855 gms and required ventilation support at 10 hrs of life for respiratory distress. The process of intubation was uneventful. She was initially extubated after 3

days but required repeat intubation for recurrent apnoeic episodes due to sepsis for another 3 days. She was noticed to have stridor since the age of 4 months, and was diagnosed for acute bronchiolitis at 5 months of age. During initial assessment, she appeared irritable. She was in respiratory distress with evidence of chest recession, and biphasic stridor, loud on inspiration. She appeared pink, and well perfused with capillary refilled time of less than 2 secs. Her respiratory rate was 56/min, blood pressure was 90/50 mmHg, heart rate was 196/min, afebrile, and oxygen saturation under room air ( $SpO_2$ ) was 85 %, which picked up to 100% on supplemental oxygen of 1l/min. There was transmitted sound over the lungs and reduced air entry at both bases. Other systemic examination was unremarkable. Laboratory findings showed that the total white cell count (WCC) was  $9.3 \times 10^9/l$  (normal range,  $4-10 \times 10^9/l$ ), neutrophils 35.7%, lymphocytes 58.1%, haemoglobin 12.1g/dl (12-15 g/dl), and the platelet count was  $334 \times 10^9/l$  ( $150-410 \times 10^9/l$ ). Blood electrolytes were normal except that there was evidence of hyperkalaemia with serum potassium of 5.9 mmol/l (3.5-5.0). Her C-reactive protein was not raised  $<0.003$  mg/dl ( $<1.0$ ). Capillary blood gases on room air were as follows: pH 7.34,  $PaCO_2$  59.6 mmHg,  $PaO_2$  44.6 mmHg,  $HCO_3$

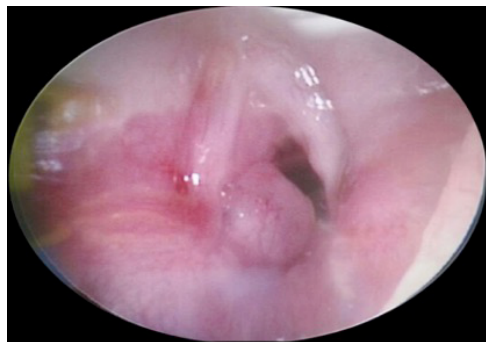


Figure 1: Endoscopic photograph of the larynx showing a subglottic cyst at left posterior commissure with subglottic oedema

29.3 mmol/L. The infant was treated at the critical area as moderate to severe croup. However, she did not respond to intravenous dexamethasone at 2.5 mg and 2 mg of inhaled budesonide. A bolus intravenous adrenalin (1:1000) was delivered to her as she became progressively breathless and the stridor became worsened by the next few hours. She was then transferred to the Paediatric Intensive Care Unit (PICU). The patient was subjected to intubation due to worsening respiratory acidosis (Capillary Blood Gases: pH 7.25, pCO<sub>2</sub> 60.6 mmHg, pO<sub>2</sub> 61.3 mmHg, HCO<sub>3</sub> 22.5 mmol/l). However, there were difficulties with the intubation attempts. The vocal cord appeared oedematous with an unexplained resistance, which prevented the tube from passing thorough the trachea. She was urgently sent to the operating theatre for an emergency advance airway procedure. A direct laryngoscopy showed subglottic cyst (Figure 1). Subsequently endolaryngeal microsurgery (ELMS) was performed in emergency setting. Histopathological report showed benign epithelial cyst. Intravenous

dexamethasone was continued for 9 days in tapering fashion. With all the efforts made, she was discharged well after 10 days of admission.

## DISCUSSION

Subglottic cysts can be either congenital or acquired and can present as single or multiple cysts, but it is often difficult to distinguish, as most paediatric patients coming in with respiratory distress generally requires endotracheal intubation based on clinical judgment without prior endoscopy. The first-reported case was in 1968 with the patient's death due to subglottic cysts (Wigger & Tang 1968).

The challenges remain in diagnosing subglottic cysts as early detection and intervention play a crucial role in improving a patient outcome and reducing the need for tracheostomy. A subglottic cyst clinical presentation varies depending on the size and location of the cyst. Inspiratory stridor and expiratory stridor suggest airway obstruction above and below the glottis, respectively. Biphasic stridor on the other hand, suggests of glottic or subglottic lesions. In the present case, the premature infant presented with biphasic stridor. Apart from that, she had a previous neonatal history of intubation. This condition should prompt the clinicians to narrow down the possible cause of stridor and to look for possible underlying cysts in infants' larynx.

A review from previous literature showed that the development of subglottic cysts has a strong association with past history of neonatal intubation

(Johnson et al. 2005). However, the duration of intubation has limited value in predicting the risk of development of subglottic cyst. A study showed that it could develop even after a period of intubation of less than 24 hrs (Johnson et al. 2005). A majority of the cases developed in premature infants (Lim et al. 2003). Agada et al. (2006) found 7 cases of subglottic cyst in a large cohort of 12,240 premature newborns. All 7 cases had history of intubation with an average intubation period of 20.6 days. The development of subglottic cyst is not always associated with history of prematurity and previous intubation. Aksoy et al. (2012) found in their study that 6 out of 9 children had no history of previous intubation.

Direct laryngoscopy is accepted as a gold standard tool to diagnose subglottic cysts (Zawadzka-Glos et al. 2009). In this patient, direct laryngoscopy was done on the next day when the infant's condition deteriorated and endotracheal intubation faced difficulty. Subglottic cysts are treatable as they can be decompressed by needle puncture and aspiration. It can safely be removed with laryngeal microdebrider with a low recurrence rate (Ransom et al. 2009). However, long-term follow-up should be planned for patients treated for subglottic cysts as there is still risk of recurrence (Lim et al. 2003).

## CONCLUSION

In the present case, we highlighted the need to have a high index of suspicion to diagnose subglottic cyst in premature infant with biphasic stridor and previous history of neonatal intubation. Early diagnosis is vital to successfully manage the airway without complications.

## ACKNOWLEDGEMENT

The authors thank the doctors, paramedics and administrative support staff in the ED, Universiti Kebangsaan Malaysia for the assistance.

## REFERENCES

- Agada, F.O., Bell, J., Knight, L. 2006. Subglottic cysts in children: A 10-year review. *Int J Pediatr Otorhinolaryngol* 70(8): 1485-8.
- Aksoy, E.A., Elsäurer, C., Serin, G.M., Unal, O.F. 2012. Evaluation of pediatric subglottic cysts. *Int J Pediatr Otorhinolaryngol* 76(2): 240-3.
- Johnson, L.B., Rutter, M.J., Shott, S.R., Cotton, R.T. 2005. Acquired subglottic cysts in preterm infants. *J Otolaryngol* 34(2): 75-8.
- Lim, J., Hellier, W., Harcourt, J., Leighton, S., Albert, D. 2003. Subglottic cysts: the Great Ormond Street experience. *Int J Pediatr Otorhinolaryngol* 67(5): 461-5.
- Ransom, E.R., Antunes, M.B., Smith, L.P., Jacobs, I.N. 2009. Microdebrider resection of acquired subglottic cysts: case series and review of the literature. *Int J Pediatr Otorhinolaryngol* 73(12): 1833-6.
- Wigger, H.J., Tang, P. 1968. Fatal laryngeal obstruction by iatrogenic subglottic cyst. *J Pediatr* 72(6): 815-820.
- Zawadzka-Glos, L., Frackiewicz, M., Brzewski, M., Biejat, A., Chmielik, M. 2009. Difficulties in diagnosis of laryngeal cysts in children. *Int J Pediatr Otorhinolaryngol* 73(12): 1729-1731.