

# Bilateral Cricoarytenoid Arthritis: A Cause of Recurrent Upper Airway Obstruction in Rheumatoid Arthritis

Pradeep PRADHAN, Abhishek BHARDWAJ, VP VENKATACHALAM

Submitted: 29 Jan 2015

Accepted: 15 Apr 2015

Department of Otorhinolaryngology, Safdarjung Hospital & Vardhmann Mahavir Medical College, Ansari Nagar, New Delhi-110029, India

## Abstract

We report a case of bilateral cricoarytenoid joint arthritis with history of rheumatoid arthritis, presented with stridor to the outpatient department. Endolaryngoscopy revealed adducted vocal cords and a nodule over left arytenoid which later confirmed to be rheumatoid nodule on histopathologic examination. Initially, although patient responded well to medical treatment, recurrence was noticed after 6 months follow-up.

**Keywords:** rheumatoid arthritis, Cricoarytenoid joint, stridor, disease recurrence

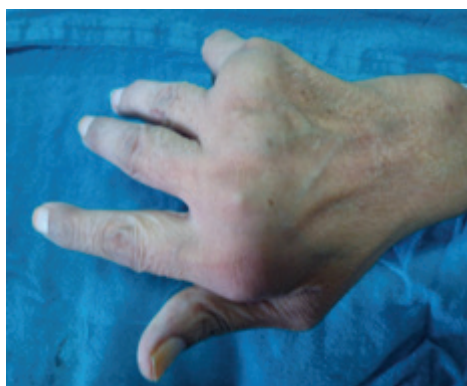## Introduction

Rheumatoid arthritis (RA) is a chronic inflammatory disease which involves the synovial membranes of diarthrodial articulations, affecting approximately 3% of adult population. [1, 2] Women between the age group of 30 to 50 years are commonly affected by the disease. All synovial joints in the body including Cricoarytenoid (CA) joint can be affected and patients often present with joint manifestations [3]. At the initial stage of the disease, the symptoms are nonspecific and subclinical and with progress of disease there may be acute airway obstruction because of bilateral CA joints involvement [4] and patients may require urgent tracheostomy [5]. Antirheumatic medications are the initial treatment offered to patients of laryngeal rheumatic arthritis and some are benefited by vocal cord abduction surgery [6]. Final outcome depends upon the response of CA joints mobility to medical treatment. Patients with bilateral CA joints involvement may have repeated laryngeal obstruction and some patients may function better with a permanent tracheostome [7].

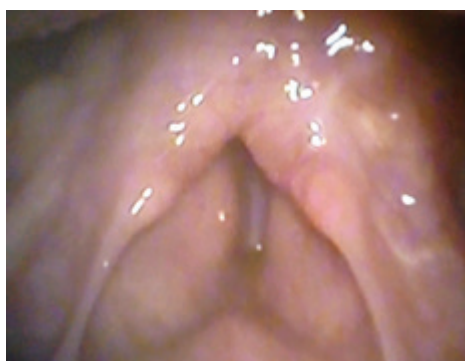## Case Report

A 52 year old female presented in outpatient department with respiratory distress for 15 days and hoarseness for 3 months. Intubation was tried but unsuccessful and hence emergency tracheostomy was performed as a life saving procedure. There was no history of smoking, tobacco chewing, and alcohol intake. Physical

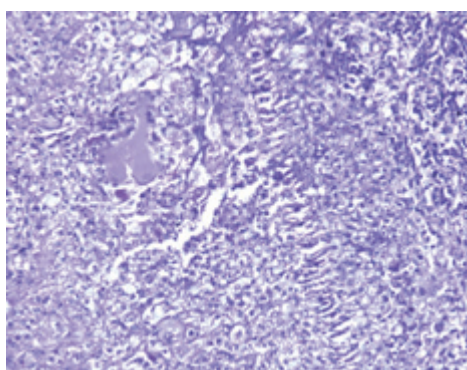
examinations revealed swelling and deformity of metacarpophalangeal joints (Fig 1) and restricted movement at elbow, wrist, shoulder, knee, and ankle joint. Two firm nodules were detected over the dorsal aspect of right forearm. Endoscopy revealed fixity of vocal cords in paramedian position, both arytenoids were edematous and there was a nodule over left arytenoids (Fig 2). CT scan of neck was found normal except the swollen arytenoids. Incisional biopsy of forearm nodule was performed and histopathological examination revealed a central area of fibrinoid necrosis surrounded by palisading epithelioid macrophages and mononuclear cells, classical feature of a rheumatoid nodule (Fig 3). Histopathologic examination of the tissue from left arytenoids was found consistent with granulomatous inflammation which was very similar to that of histopathology of forearm nodule. Rheumatoid factor (RF) and anti-cyclic citrullinated peptide (CCP) antibodies were negative. C-reactive protein (CRP) and Erythrocyte Sedimentation Rate (ESR) were raised. Diagnosis of rheumatoid arthritis was made based on 2010 ACR-EULAR criteria with a score of 7. Patient was treated with antirheumatic medications for one month and after one month; there was significant improvement in mobility at all the limb joints. Endolaryngoscopy revealed movement of bilateral true vocal cords and glottic chink was found adequate. Then patient was decannulated and discharged. After 6 months of follow-up, again patient presented with respiratory difficulty requiring a revision tracheostomy. Laryngoscopic findings were similar to the preoperative findings.



**Figure 1:** Swelling and deformity of metacarpophalangeal joints of right hand.



**Figure 2:** Endoscopic view showing adduction of bilateral true vocal cords and a nodule found over left arytenoids.



**Figure 3:** Histopathological picture of rheumatoid nodule showing fibrinoid necrosis surrounded by palisading epithelioid macrophages and mononuclear cells (arrow) (H&E x200).

Patient was on regular follow-up for past one year with a permanent tracheostome despite of antirheumatic medications.

## Discussion

We present a rare case of CA joint rheumatoid arthritis presented with hoarseness and stridor. Patient had history of multiple joint stiffness for 2 years involving both large and small joints. CA joint arthritis was confirmed by correlating the histopathological examination of laryngeal and forearm nodules. Patient was started on antirheumatic medications for one month and found to have significant improvement on laryngeal and extra laryngeal symptoms. Endoscopy showed movements of bilateral arytenoid and the glottic chink was found adequate. After one month of hospital stay, patient was decannulated and he was on regular follow-up in the outpatient department with continuation of medical treatment for rheumatoid arthritis. After 6 months, patient again presented with respiratory difficulty which required revision tracheostomy. Laryngoscopic findings were found similar to preoperative findings.

Rheumatoid arthritis (RA) is a chronic inflammatory disease where CA joint is found to be involved in 17%–70% of patients [8] and laryngeal nodule is found in about 20% cases [9]. Symptoms vary according to the involvement of CA joint, whether it is unilateral or bilateral and the position at which vocal cords become fixed. In early stage, symptoms are nonspecific and subclinical and with progress of disease, patient may have hoarseness, dysphasia, odynophagia and rarely stridor due to bilateral involvement of CA joints where cords become fixed in adducted position. But the clinical features of laryngeal pathology do not always seem to be related to systemic disease activity [10]. Stridor is a life threatening complication occurring late in the course of disease, and patients more often present with inactive joint manifestations although physical examination reveals significant joint deformity [5]. It can be precipitated by acute inflammation due to upper respiratory tract infection or due to chronic rheumatoid arthritis involving bilateral CA joints. Antirheumatic medications are considered as primary treatment modality and surgical treatment with arytenoidectomy and vocal cord lateralisation are sometimes offered to patients of CA joint arthritis [5]. Though there is significant improvement in the extra laryngeal manifestations of rheumatoid

arthritis, the response to CA joint is variable. Here we have described a case of bilateral CA joints rheumatoid arthritis which was satisfactorily responded to medical treatment and after one month, but after 6 months again patient had recurrence of laryngeal symptoms which needed revision tracheostomy. Patient was on close follow-up for the past one year with antirheumatic medications with a permanent tracheostome. In the literature, there are very few case reports of rheumatoid arthritis with bilateral CA joint involvement have been described and none has focused on the recurrence of the disease, although it has been found significant improvement in the extra laryngeal symptoms with standard antirheumatic medications.

## Conclusion

Bilateral cricoarytenoid arthritis is an infrequent involvement of rheumatoid arthritis. Patients can have subclinical and nonspecific symptoms in a progressive course of disease, so the diagnosis is often delayed. Air way obstruction is a life threatening complication of bilateral CA joint arthritis, requiring urgent tracheostomy as a life saving measure. Antirheumatic medications are the first line treatment offered to patients of CA joint arthritis with variable results. Very rarely patients can have recurrence of disease in spite of medical treatment.

## Acknowledgement

This study is attributed to Department of Otorhinolaryngology and Head Neck Surgery, VMMC and Sabdarjung Hospital, New Delhi-110029. This research received no specific grant from any funding agency, commercial or not-for-profit sectors.

## Correspondence

Dr Abhishek Bhardwaj  
MS (ENT)  
Department of Otorhinolaryngology,  
Safdarjung Hospital & Vardhmann Mahavir Medical  
College,  
Ansari Nagar, New Delhi-110029,  
India.  
Tel: +919899077921  
Fax: +01126163072  
Email: abhio4stanley@gmail.com

## References

1. Pickhard A, Smith E, Rottscholl R, Brosch S, Reiter R. Disorders of the Larynx and chronic Inflammatory diseases. *Laryngorhinootologie*. 2012;**91(12)**:758–766.
2. Gare BA. Epidemiology. *Bailliere's Clinical Rheumatology*. 1998;**12(2)**:191–208.
3. Berjawi G, Uthman I, Mahfoud L, Husseini ST, Nassar J, Kotobi A, et al. Cricothyroid joint abnormalities in patients with rheumatoid arthritis. *J Voice*. 2010;**24(6)**:732–737.
4. Hamdan AL, El-Khatib M, Dagher W, Othman I. Laryngeal involvement in rheumatoid arthritis. *Middle East J Anesthesiol*. 2007;**19(2)**:335–344.
5. Montgomery WW. Cricothyroid arthritis. *Laryngoscope*. 1963;**73**:801–836.
6. Kolman J, Morris I. Cricothyroid arthritis: A cause of acute upper airway obstruction in rheumatoid arthritis. *Can J Anesth*. 2002;**49(7)**:729–32.
7. Fujiwara S, Nakamura I, Higo R, Tajiri Y, Nakamura K, Oda H. Repeated postoperative laryngeal obstruction due to bilateral cricoarytenoid joint involvement in rheumatoid arthritis. *Mod Rheumatol*. 2005;**15(2)**:123–125.
8. Geterud A. Rheumatoid arthritis in larynx. *Scand J Rheumatol*. 1991;**20(3)**:215.
9. Murano E, Hosako-Naito Y, Tayama N, Oka T, Miyaji M, Kumada M, et al. Bamboo Node: primary vocal fold lesions as evidence of autoimmune disease. *J Voice*. 2001;**15(3)**:441–450.
10. Haben M, Chagnon FP, Zakhary K. Laryngeal Manifestation of Autoimmune Disease: Rheumatoid Arthritis Mimicking a Cartilaginous Neoplasm. *J Otolaryngol*. 2005;**34**:1–4.