

A case report of pyloric intussusception secondary to helicobacter pylori hyperplastic polyps

Wan Najmi Wan Daud, M.S (UKM)*, Noorfizura Ahmad, M.Rad (USM)**, Wan Anna Mohd Fahmi, M.Path (UKM)***

*Upper GI Unit, Department of Surgery, Hospital Sultanah Bahiyah, Kedah, **Department of Diagnostic and Imaging, Hospital Tuanku Fauziah, Perlis, ***Department of Pathology, Hospital Sultanah Bahiyah, Kedah

SUMMARY

We report a middle age man who presented with intermittent vomiting and loss of weight. Oesophagogastroduodenoscopy showed numerous antral hyperplastic polyps with inaccessible duodenum. Contrast enhanced computed topography demonstrated a classical target sign of intussusception. This finding was later confirmed at laparotomy. This rare presentation and management strategy is discussed.

KEY WORDS:

Pyloric intussusception and hyperplastic polyp

INTRODUCTION

Gastric polyps are usually discovered during endoscopy as incidental findings; around 6% in published reports.¹ Common presentations vary from mild form of dyspepsia, to more complex cases such as bleeding, obstruction and rarely intussusception. Hyperplastic polyps especially those arising from fundic glands; are the commonest type of benign polyps. A small percentage of familial type such as Familial Adenomatous Polyposis Syndrome, is discovered during surveillance endoscopy. Nevertheless, rare sporadic type of adenoma should be biopsied to exclude malignancy.

Hyperplastic polyps are usually present in the middle age group and rarely cause gastric outlet obstruction or other complex features. We present an interesting case of a middle age man with gastric outlet intussusception secondary to hyperplastic polyps.

CASE REPORT

A 42-year-old man was admitted for intermittent recurrent vomiting and loss of weight of three months duration. Oesophagogastroduodenoscopy (OGDS) showed multiple small polypoidal growth in the entire stomach, predominantly in the antral region. Normal pyloric opening was absent and duodenum was inaccessible. Nonetheless, there was neither pooling of undigested food nor dilated stomach evident, as typically seen in classical acute gastric outlet obstruction. Contrast enhanced computed topography scan (CECT) demonstrated a classical feature of intussusception in the pyloric region (Figure 1). Histology

from OGDS was reported as hyperplastic gastric polyps with presence of *Helicobacter pylori*.

He was resuscitated, optimised with parenteral nutrition before surgery. At laparotomy, as expected distal third of the stomach with numerous polyps intussuscepted into the duodenum (Figure 2). Partial gastrectomy, retrocolic with roux en Y gastrojejunostomy performed. Post-operative period was uneventful and he was discharged well with *Helicobacter pylori* eradication regime. A repeat OGDS around five weeks post resection showed nearly complete regression of remaining polyps in the body and cardio-oesophageal junction.

DISCUSSION

The management strategy of gastric polyps generally depends on the patient's presentation, morphology, location and histology of the polyps. Endoscopic polypectomy, laparoscopic excision and gastrectomy had been described in the literatures. Generally, at least 80% *Helicobacter pylori* associated hyperplastic polyps in the stomach will regress following eradication therapy.¹

Most common hyperplastic polyps causing gastric outlet obstruction or intussusception are the giant polyp (more than 3 cm) and the pedunculated type.^{2,3} Nevertheless, benign neoplasms like Brunner's gland polyp, Peutz Jegher's hamartoma and Gastrointestinal Stromal Tumors (GIST) are much more commonly associated with intussusception.² In general, intussusception in adults almost always requires surgical resection of the leading point.

While up to 80% of the polyps are asymptomatic, generally it is advisable to exclude dysplasia or malignant potential by histology. Neoplastic potential is higher if the size is more than 2 cm. It occurs around 28-40% in tubulovillous and 5% in tubular adenoma.¹ For hyperplastic polyps, the controversy is whether to perform a complete snare polypectomy; as the biopsy forceps might miss the dysplastic foci within. On the other hand, some authors recommend periodic assessment and biopsy.

In this patient, intussusception with gastric outlet obstruction is a clear indication for surgery despite being secondary to multiple hyperplastic polyps. However, pathophysiology of

This article was accepted: 12 November 2015

Corresponding Author: Wan Najmi Wan Daud, Upper GI Unit, Department of Surgery, Hospital Sultanah Bahiyah, 05100 Alor Setar, Kedah
Email: drnajmi@yahoo.com

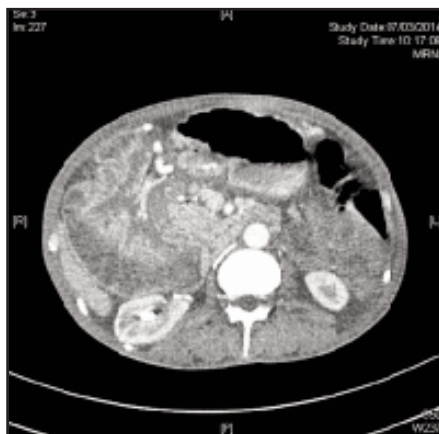

Fig. 1: Classical features of intussusception in CECT.

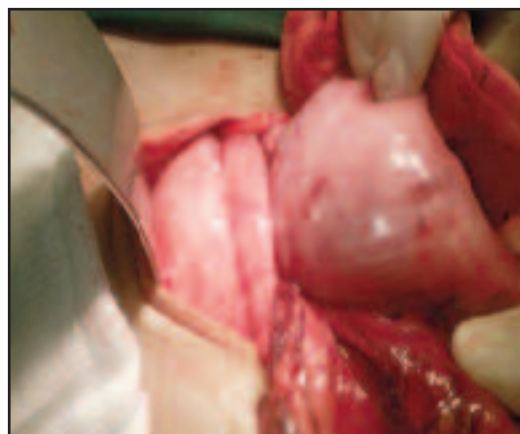


Fig. 2: Intra-operative photo of intussuscepted pylorus.

how these numerous hyperplastic polyps had caused intussusception remains unclear. Perhaps, one of the reasons was because the ability of stomach and duodenum to distend to withstand the chronic intermittent obstruction. This clump of numerous hyperplastic polyps formed a ‘giant polyp’ which is likely to be the leading point.

Contrary to other more common types of intussusception such as ileo-colic or colo-colic types; endoscopy with CECT are the invaluable investigation tools to confirm the diagnosis. If the endoscopic assessment is incomplete, an urgent imaging should be arranged in order to have a better picture of the underlying pathology. Our patient had recurrent partial gastric outlet obstruction which resulted in malnutrition. Therefore, optimizing his nutritional status was utmost important element in preoperative preparation. Partial parenteral nutrition was given to achieve near full total energy requirement as recommended by European Society of Parenteral and Enteral Nutrition (ESPEN).

Partial gastrectomy appears to be adequate to minimize all the risks and consequences of total gastrectomy such as anaemia, vitamins’ deficiency and malnutrition. Risk of dysplasia in hyperplastic polyps is estimated from 1.9-19% with prevalence of adenocarcinoma ranges in between 0.6-2.1%.¹ Therefore, we endeavour periodic endoscopic assessment of the remaining gastric mucosa to detect dysplastic changes. The remaining small polyps are expected to regress following *Helicobacter pylori* eradication. In addition to this, risk of dysplasia secondary to bile reflux is minimized by performing roux en Y gastrojejunostomy instead of Billroth II reconstruction.

In summary, management of hyperplastic polyps must be tailored to individual presentation. Occurrence with pyloric intussusception requires definitive surgical resection.

ACKNOWLEDGEMENT

We would like to thank Dato’ Dr Wan Khamizar for editing this manuscript. Last but not the least, the Director General of Health Malaysia for his permission to publish this article.

REFERENCES

1. Goddard AF, Badreldin R, Pritchard DM, Walker MM, Warren B; British Society of Gastroenterology. The management of gastric polyps. *Gut* 2010; 59(9): 1270-6.
2. Kim DJ, Lee JH, Kim W. Gastroduodenal intussusception resulting from large hyperplastic polyp. *J Gastric Cancer* 2012; 12(3): 201-4.
3. Parikh M, Kelley B, Rendon G, Abraham B. Intermittent gastric outlet obstruction caused by a prolapsing antral gastric polyp. *World J Gastrointest Oncol* 2010; 2(5): 242-6.