

## CASE REPORT

### Malignant transformation of breast ductal adenoma: a diagnostic pitfall

Hiroko HAYASHI, Hiroshi OHTANI,\* Junzo YAMAGUCHI,\*\* and Isao SHIMOKAWA

*Department of Pathology, Nagasaki University School of Medicine and Graduate School of Biomedical Science, Nagasaki, \*Department of Clinical Laboratory, Hakujuji Hospital, Fukuoka and \*\*Department of Surgery, National Hospital Organization Saga National Hospital, Saga, Japan*

#### Abstract

We present what is believed to be the first report of heterogeneous carcinoma arising from breast ductal adenoma. A 57-year-old woman presented with a nodule in her right breast. Histological examination of a vacuum-assisted biopsy specimen revealed epithelial tubular proliferation and papillary apocrine epithelium. The myoepithelial cells lining the tubules were confirmed by immunohistochemistry. The nodule had increased in size 18 months later and tumorectomy was performed. The surgical specimen revealed proliferating apocrine epithelium with sheet-like and cribriform architecture within a mammary duct. Some myoepithelial cells showed irregular proliferation around the tubular epithelium. All three components, including apocrine, myoepithelial and glandular cells, showed prominent nuclear atypia and significant mitotic activity. The patient was diagnosed with malignant transformation of ductal adenoma. The malignant potential of ductal adenoma has not previously been discussed, but this heterogeneous carcinoma could represent a serious pitfall in the diagnosis of ductal adenomas.

**Keywords:** ductal adenoma, adenomyoepithelioma, papilloma, epithelial–myoepithelial carcinoma, breast tumour

#### INTRODUCTION

Ductal adenoma is defined as a benign tumour with epithelial tubular proliferation in the mammary ducts. According to the World Health Organization (WHO), this tumour is classified as a benign epithelial proliferation.<sup>1</sup> Ductal adenomas characteristically have a sclerosing interstitium, and the tubular components thus resemble invasive carcinoma. It is therefore important to confirm the presence of myoepithelial cells lining the tubules, to distinguish them from malignant tumours. Ductal adenoma with some nuclear atypia but without extensive proliferative activity is considered benign.<sup>2-4</sup> To the best of our knowledge, no previous cases of a malignant tumour arising from ductal adenoma have been described, and the malignant potential of ductal adenomas has not been reported.

In this study, we describe what is believed to be the first report of a patient with heterogeneous carcinoma arising from ductal adenoma. The tumour demonstrated proliferation of apocrine,

glandular and myoepithelial cells with prominent nuclear atypia and significant mitotic activity. This case suggests that ductal adenoma has malignant potential, similar to that of papilloma and adenomyoepithelioma.

#### CASE REPORT

A 57-year-old woman visited our hospital with a nodule in her right breast. Ultrasonography showed a hypoechoic nodule 1.3 × 0.9 × 0.9 cm in size, located in the upper part of the breast. The nodule was solid, lobulated and demarcated. Breast cancer was suspected and vacuum-assisted biopsy was performed. The pathological diagnosis based on the biopsy specimen was ductal adenoma and the patient was subsequently followed up. Eighteen months later, the nodule had increased to 1.5 × 1.0 × 0.8 cm, and tumorectomy was performed. The patient received adjuvant radiotherapy with a total dose of 50 Gy. No signs of disease recurrence were evident 2 years after excision.

*Address for correspondence:* Hiroko Hayashi, Department of Pathology, Nagasaki University School of Medicine and Graduate School of Biomedical Science, 1-12-4 Sakamoto, Nagasaki 852-8523, Japan. Tel: +81-95-819-7050; Fax: +81-95-819-7052. E-mail: hayashih@nagasaki-u.ac.jp

*Pathological findings*

The biopsy specimen demonstrated epithelial proliferation within the intraductal lumen (Fig. 1a). The tumour was composed of apocrine epithelium with papillary features (Fig. 1b) and glandular epithelium proliferating in a tubular fashion, with sclerosing interstitium (Fig. 1c). The apocrine cell nuclei were enlarged, with prominent nucleoli (Fig. 1b). Atypical cells with clear cytoplasm surrounded the tubular structure and showed irregular proliferation (Fig. 1d). A few nuclear mitoses were discernible in the apocrine, glandular and myoepithelium-like cells. Immunohistochemistry revealed a mosaic distribution of 34 $\beta$ E12, and sporadic p63-positive cells around the tubules (Fig. 1e) and in the papillary apocrine epithelium. We suspected

that the tumour was a ductal adenoma because of the presence of intraductal proliferation mingled with tubular structures, surrounded by clear cells positive for myoepithelial markers, and apocrine epithelium.

The resected specimen showed that the tumour was 11.0  $\times$  8.5 mm in diameter and a nodule protruded into the ductal lumen (Fig. 2a). The duct wall was thickened by fibrous tissue. In most (90%) of the lesion, the proliferating tumour cells had abundant eosinophilic granular cytoplasm and enlarged nuclei with prominent nucleoli, consistent with the features of apocrine epithelium. In 70% of the tumour, apocrine epithelium had a cribriform pattern and focal solid proliferation (Fig. 2b). In this area, the tumour cells had a high nucleo-cytoplasm ratio

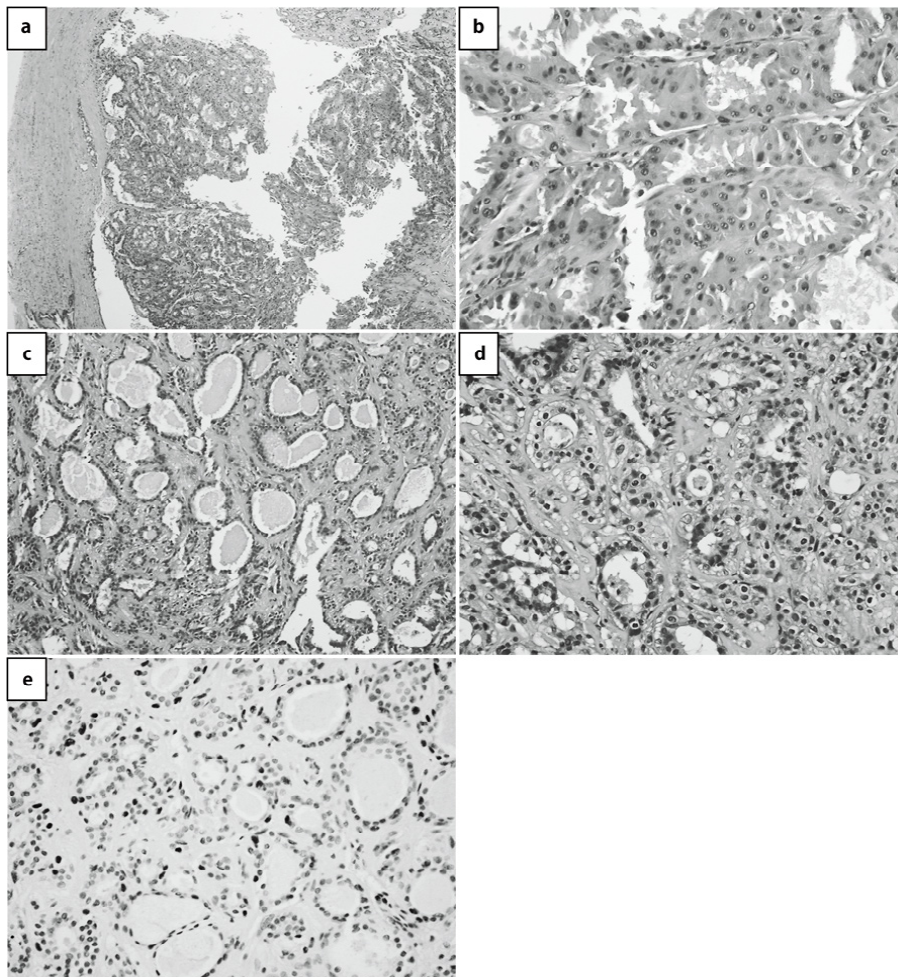


FIG. 1: Microscopical examination of the vacuum-assisted biopsy specimen. (a) The proliferative lesion was in the mammary duct. (b) Apocrine epithelium proliferated in a papillary fashion showed enlarged nuclei and prominent nucleoli with eosinophilic cytoplasm. (c) Tubular architecture was seen within the sclerosing interstitium. (d) Clear myoepithelium-like cells proliferated irregularly. (e) Myoepithelium-like cells were p63 positive.

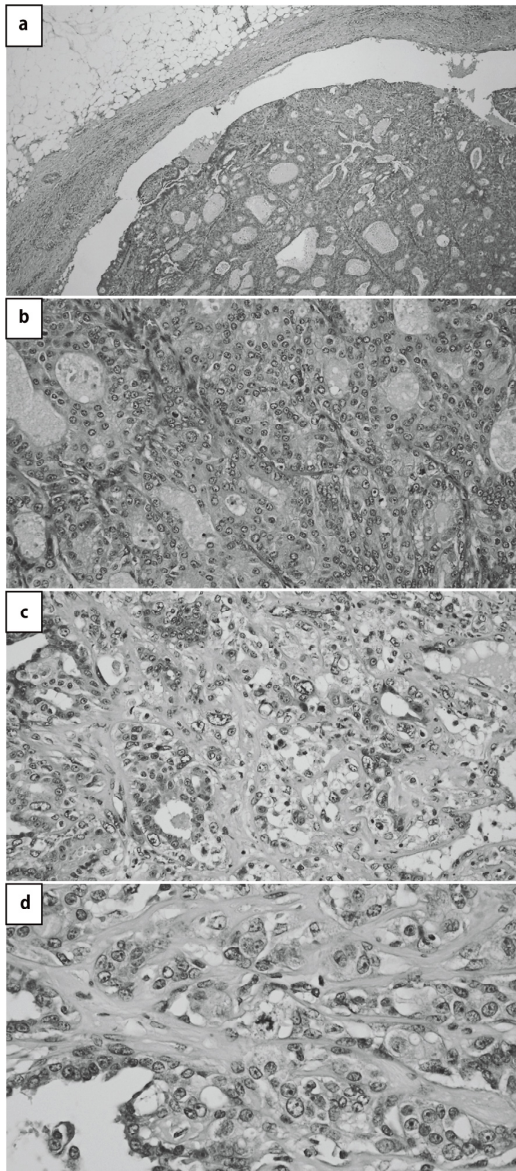


FIG. 2: Microscopic features of the surgical specimen. (a) The proliferative lesion was entirely within the mammary duct. Apocrine epithelium proliferated, showing a cribriform pattern. (b) Apocrine cells showed a high nucleocytoplasmic ratio, frequent mitoses, and sheet-like architecture. (c) Clear cells showed pleomorphic nuclear atypia and proliferated irregularly around the tubules. Bizarre nuclei and frequent mitoses were seen. (d) Atypical mitosis was discernible.

and high mitotic activity of 6/10 high-power fields (HPFs). This area was therefore considered to be apocrine carcinoma. Some tumour cells were proliferating in a tubular fashion, occupying 20% of the tumor, and in a papillary pattern,

accounting for 10% of the tumour, which were similar to those of ductal adenoma. In part of the tubular area, which was 5% of the whole tumour, cells with clear cytoplasm proliferated irregularly around the tubular glandular cells and showed marked nuclear atypia (Fig. 2c). Bizarre nuclei were also seen. This area revealed frequent mitoses in 7/10 HPFs, and atypical mitoses (Fig. 2c,d). Immunohistochemical staining found no p63-positive myoepithelial cells in the nests of atypical apocrine epithelium. The area with clear cell proliferation showed marked nuclear atypia, and p63-positive, smooth muscle actin (SMA)-positive cells were frequently seen (Fig. 3a, b). The highest proliferative activity, assessed by Ki-67 staining, was 42.6%, which was detected in this area of atypical clear cell proliferation (Fig. 3c). p63-positive cells were also seen lining the duct lumen, and the lesion was therefore confirmed as an intraductal tumour. The tumour was partly positive for

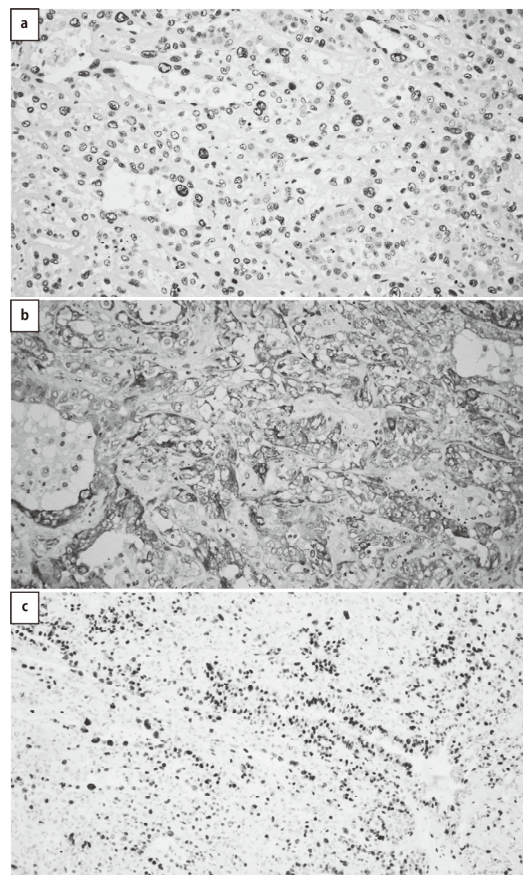


FIG. 3: Immunohistochemistry of the surgical specimen. Clear cells showed positivity for p63 (a) and SMA (b). (c) The Ki-67 index was high in the clear cell proliferative area.

oestrogen and progesterone receptors (<5%), but was HER2 negative. The apocrine epithelium was positive for androgen receptors. Based on morphological and immunohistochemical features, we diagnosed the lesion as malignant transformation of ductal adenoma.

## DISCUSSION

Ductal adenoma is a controversial entity that is sometimes referred to as sclerosing papilloma. WHO considers it a benign tumour,<sup>1</sup> while other authors include it within the papilloma category.<sup>5</sup> Additionally, the distinction between ductal adenoma and adenomyoepithelioma is also controversial. Both share pathological features, including being proliferative lesions with both epithelial and myoepithelial components, although ductal adenoma is present within the mammary ducts, while adenomyoepithelioma reveals prominent myoepithelial proliferation.

To the best of our knowledge, there have been no previous reports of carcinoma arising from ductal adenoma, although malignancies have often been described accompanying adenomyoepithelioma. Sixteen cases of biphasic epithelial–myoepithelial carcinoma (malignant adenomyoepithelioma) have been reported to date.<sup>5-13</sup> However, the criteria for malignancy in adenomyoepithelioma have not yet been clearly defined, and it is possible that the criteria alone do not represent malignant potential, given that adenomyoepithelioma without any malignant features can still metastasize.<sup>14</sup> However, indicators such as invasive proliferation, prominent nuclear atypia, brisk mitotic activity, and necrosis are generally accepted as malignant findings in adenomyoepithelioma.<sup>13,14</sup>

The current case showed two-layered tubular proliferation within a mammary duct, in a vacuum-assisted biopsy specimen. The lesion was accompanied by papillary proliferation of apocrine epithelium, which gave the heterogeneous impression of a benign tumour. However, all three components, glandular, myoepithelial and apocrine cells, showed conspicuous nuclear atypia and sporadic mitoses on detailed observation. A surgical specimen taken 18 months after the biopsy specimen revealed atypical apocrine cells proliferating with a sheet-like and cribriform pattern in most of the lesion. Mitotic activity was detected in 6/10 HPFs, and no myoepithelial cells were seen in the apocrine epithelial nests. We considered this area to be apocrine carcinoma.

Moreover, the myoepithelial component in the current case revealed marked malignant features, including cells with clear cytoplasm, proliferating irregularly around the glandular tubules, positive for myoepithelial markers such as p63 and SMA. The tubular area showed prominent nuclear atypia, atypical mitoses, and high proliferative activity, thus, we consider that the glandular and myoepithelial components together represent epithelial–myoepithelial carcinoma. It is possible that this heterogeneous carcinoma comprising both apocrine carcinoma and epithelial–myoepithelial carcinoma arose from the original ductal adenoma. These features were notable because the area of mixed myoepithelial and glandular cells was originally assumed to be atypical, double-layered tubules in the biopsy specimen. Ductal adenoma may involve myoepithelial hyperplasia, as well as adenomyoepithelioma, and a myoepithelial lining within proliferative tubules is considered a hallmark of a benign tumour.<sup>15</sup> Additionally, because nuclear atypia has been reported in ductal adenoma,<sup>2,4</sup> we diagnosed the current biopsy specimen as ductal adenoma. However, heterogeneous carcinoma subsequently arose from this atypical ductal adenoma, and it is possible that the ductal adenoma in the original biopsy specimen was already malignant, or at least showed clear malignant potential. It is therefore important to be aware that malignancy may arise from ductal adenoma, and accurate diagnosis based on surgical specimens is recommended for similar lesions.

To the best of our knowledge, the malignant potential of ductal adenomas has not previously been reported, although the distinction between ductal adenoma and invasive carcinoma has been considered. However, if ductal adenoma is a variant of papilloma, or closely related to adenomyoepithelioma, then it might be expected to show similar malignant potential. The current novel case highlights the malignant potential of ductal adenoma, revealing a potentially serious diagnostic pitfall, especially in cases diagnosed on the basis of biopsy specimens.

## ACKNOWLEDGEMENT

The authors have no conflict of interest to declare. This study was not supported by any funding agency.

## REFERENCES

1. Foschini MP, Simpson JF, O'Malley FO. Ductal

- adenoma. In: Lakhani SR, Ellis IO, Schnitt SJ, Tan PH, van de Vijver MJ, editors. WHO Classification of Tumours of the Breast. 4th ed. Lyon: IARC; 2012. p. 117.
2. Gusterson BA, Sloane JP, Middwood C, *et al.* Ductal adenoma of the breast – a lesion exhibiting a myoepithelial/epithelial phenotype. *Histopathology*. 1987; 11: 103–10.
  3. Lammie GA, Millis RR. Ductal adenoma of the breast – a review of fifteen cases. *Hum Pathol*. 1989; 20: 903–8.
  4. Okada K, Suzuki Y, Saito Y, Umemura S, Tokuda Y. Two cases of ductal adenoma of the breast. *Breast Cancer*. 2006; 13: 354–9.
  5. Koerner FC. Papilloma and related benign lesions. In: Hoda SA, Brogi E, Koerner FC, Rosen PP, editors. *Rosen's Breast Pathology*. 4th ed. Philadelphia: Wolters Kluwers; 2014. p. 95–152.
  6. Pauwels C, De Potter C. Adenomyoepithelioma of the breast with features of malignancy. *Histopathology*. 1994; 24: 94–6.
  7. Rasbridge SA, Millis RR. Adenomyoepithelioma of the breast with malignant features. *Virchows Arch*. 1998; 432: 123–30.
  8. Simpson RH, Cope N, Skálová A, Michal M. Malignant adenomyoepithelioma of the breast with mixed osteogenic, spindle cell, and carcinomatous differentiation. *Am J Surg Pathol*. 1998; 22: 631–6.
  9. Ahmed AA, Heller DS. Malignant adenomyoepithelioma of the breast with malignant proliferation of epithelial and myoepithelial elements: a case report and review of the literature. *Arch Pathol Lab Med*. 2000; 124: 632–6.
  10. Hungermann D, Buerger H, Oehlschlegel C, Herbst H, Boecker W. Adenomyoepithelial tumours and myoepithelial carcinomas of the breast – a spectrum of monophasic and biphasic tumours dominated by immature myoepithelial cells. *BMC Cancer*. 2005; 5: 92.
  11. Oka K, Sando N, Moriya T, Yatabe Y. Malignant adenomyoepithelioma of the breast with matrix production may be compatible with one variant form of matrix-producing carcinoma: a case report. *Pathol Res Pract*. 2007; 203: 599–604.
  12. Petrozza V, Pasciuti G, Pacchiarotti A, *et al.* Breast adenomyoepithelioma: a case report with malignant proliferation of epithelial and myoepithelial elements. *World J Surg Oncol*. 2013; 11: 285.
  13. Yang Y, Wang Y, He J, *et al.* Malignant adenomyoepithelioma combined with adenoid cystic carcinoma of the breast: a case report and literature review. *Diagn Pathol*. 2014; 9: 148.
  14. Nadelman CM, Leslie KO, Fishbein MC. “Benign,” metastasizing adenomyoepithelioma of the breast: a report of 2 cases. *Arch Pathol Lab Med*. 2006; 130: 1349–53.
  15. Azzopardi JG, Salm R. Ductal adenoma of the breast: a lesion which can mimic carcinoma. *J Pathol*. 1984; 144: 15–23.