

# An infant with cerebellar tumor presenting with torticollis as the only initial symptom

<sup>1</sup>Hye Young Choi MD, <sup>2</sup>Seungnam Son MD, <sup>3</sup>Hong Sik Jo MD, <sup>3</sup>Min-Kyun Oh MD PhD

<sup>1</sup>Department of Radiology, <sup>2</sup>Neurology and <sup>3</sup>Rehabilitation Medicine, Gyeongsang National University Hospital & School of Medicine, Jinju, South Korea

## Abstract

Torticollis is an usual symptom that can be the result of various disorders, such as sternocleidomastoid muscle pathology, bony abnormalities of the cervical spine, disorders of the central or peripheral nervous system, various ocular diseases, and brain tumors, especially in children. A 12-month-old male visited our hospital because of torticollis. He was normal on systemic examination, with no neurological abnormality, and his cervical spine CT was also normal. About 4 weeks later, he revisited the emergency department due to vomiting with altered mental status, and was diagnosed with a cerebellar tumor with hemorrhage. Although torticollis is known to be an important sign of a posterior fossa tumor, associated neurological or ocular symptoms are usually present. We report here a patient with posterior fossa tumor where torticollis was the only initial presenting symptom.

## INTRODUCTION

Torticollis is the abnormal positioning of the head and neck; it can be congenital or acquired. Acquired torticollis in children is caused by wide variety of pathologies, such as cervical bone abnormalities, nasopharyngeal infection, trauma, and ocular disorders. Some of its causes may be more serious, such as tumors of the cervical spinal cord or posterior fossa.<sup>1,2</sup>

Here, we report the case of a 13-month-old child with acquired torticollis who was diagnosed with a posterior fossa tumor one month after the initial visit. This report illustrates the importance of torticollis as a sign of posterior fossa tumor even when there is no other associated symptom. To our knowledge, this is the first reported case of torticollis as the only initial symptom of the posterior fossa tumor in a child.

## CASE REPORT

A 12-month-old male was referred to the rehabilitation clinic due to right-sided torticollis. He was born with a normal presentation and delivery. There was no history of developmental delay, and his right-sided torticollis was noted about one month earlier. There was no family history of neurologic or muscular disease. There was also no abnormality on systemic and neurological examination. Powers in all extremities were full and symmetric. Deep tendon

reflexes were normal and gait revealed no unusual patterns. Other physical examination was normal with the exception of the right-sided torticollis. No neck mass was found and full active and passive ranges of movement were seen without neck pain. Spine CT performed at a different hospital also showed no abnormal finding.

Home-based stretching exercises were recommended and a consultation to an ophthalmology clinic was made to look for ocular torticollis. Although the ocular examination was difficult due to poor cooperation, he had normal and equal pupil sizes and reaction to light. Full ranges of eye movements in all directions and good red reflexes were achieved in both eyes. There was no photophobia or epiphora. It was recommended that he visit a rehabilitation clinic and an ophthalmology clinic one month and 6 months later, respectively.

About 4 weeks after the initial visit, he was re-admitted to the emergency department due to more than 10 episodes of vomiting and an altered mental status. CT of the brain was urgently performed to look for posterior fossa tumor. CT revealed a large enhancing mass with cerebellar hemorrhage (Figure 1). Intraventricular hemorrhage and hydrocephalus were also seen. The cerebellar tumor was suspected to be a medulloblastoma from the imaging findings, and an external ventricular drainage was placed by a neurosurgeon to control the hydrocephalus. His

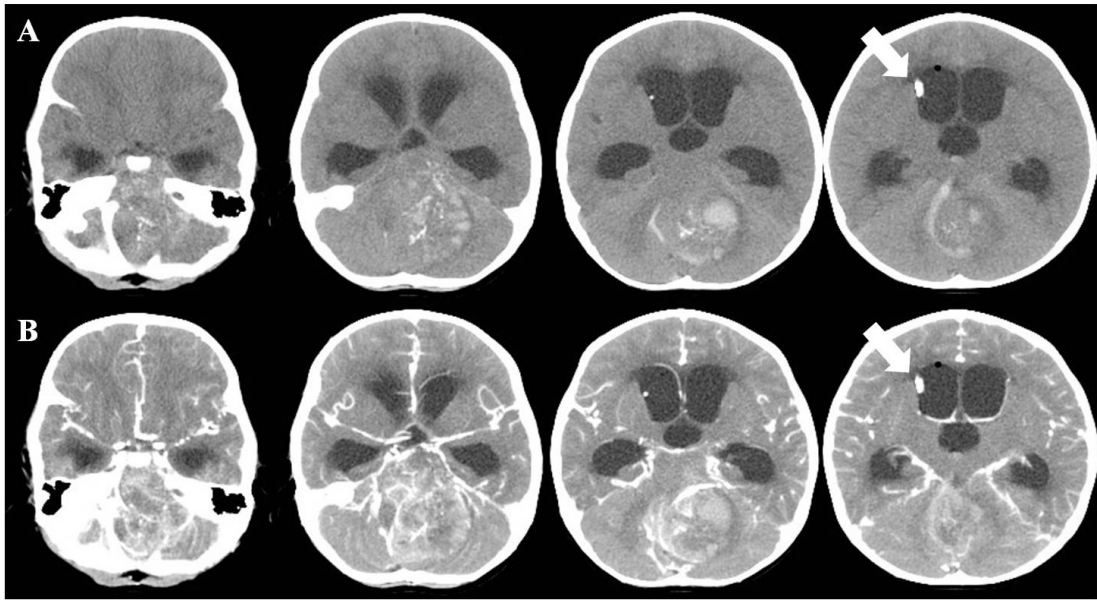


Figure 1. Axial brain computed tomography images obtained in the emergency department: pre-contrast scans (A) and contrast-enhanced scans (B). A mass lesion was suspected, with internal calcification and hemorrhage, in the mid portion of the cerebellum in A and strong enhancement of the lesion is observed in B. Note the enlarged ventricles, due to compression by the mass lesion, and the inserted external ventricular drainage catheter (white arrows).

parents wanted to transfer him to another hospital, so no further management was given and he was transferred.

We re-reviewed his initial spinal CT after his transfer, and could find the tumor on the source images (Figure 2).

### DISCUSSION

The posterior fossa is the bowl-shaped largest and deepest fossa of the cranium, situated below the tentorium. The brainstem (pons, medulla) is

located anteriorly and the cerebellum, including the vermis and cerebellar hemispheres, is located posterolaterally in the posterior fossa.<sup>3</sup>

Tumors arising at the structures in the posterior fossa are referred to as posterior fossa tumors. Extremera *et al.*<sup>4</sup> reviewed 142 patients' records in the neurosurgical department of their hospital, from 1988 to 2006, and reported that the cerebellum (57%) was the most common location of tumors, followed by the fourth ventricle (17%) and the brain stem (13%). Astrocytoma (51%) was

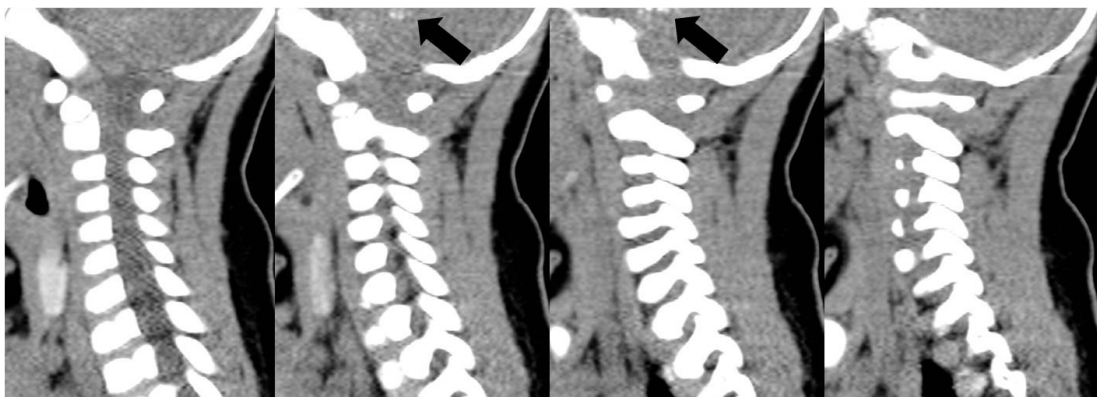


Figure 2. Sagittal source images of cervical spine computed tomography obtained at a different hospital about 4 weeks prior to the emergency department visit. Note the abnormal high-density signals located in the cerebellum (black arrow).

the most prevalent histological type, followed by medulloblastoma (24%), ependymoma (13%), and glioma (4%). The most common presenting features of posterior fossa tumor are vomiting (60%), ataxia (51%), and headache (48%). It was also found that 23% (33/142) of patients with posterior fossa tumor had torticollis, predominantly in patients aged 2-8 years old. Most of the previously reported cases with torticollis as an initial symptom of posterior fossa tumor also had associated neurological or ocular symptoms, such as hemiplegic motor weakness<sup>5</sup>, recurrent vomiting<sup>3</sup>, photophobia<sup>6</sup>, and exaggerated deep tendon reflexes with cerebellar ataxia.<sup>7</sup>

There were two reported cases in which acquired torticollis was the only presenting symptom in children with medulloblastoma.<sup>8</sup> However, both children had accompanying neck pain with the torticollis. The report explained that torticollis might occur because the patients tended to maintain a fixed posture to avoid stretching and irritation of the dura caused by the mass, and neck pain may occur from active resistance when the head was passively flexed forward.

In contrast, our patient showed no neurological sign, ocular symptom, or neck pain. Although torticollis has been considered as one of the manifestations of posterior fossa tumor, torticollis as the only presentation in children has not been ascribed to posterior fossa tumor because of its many underlying etiologies. This may lead to considerable delay in the diagnosis of the tumor. This case shows that it is possible for posterior fossa tumor to manifest only as torticollis.

Several mechanisms have been suggested for the development of torticollis in patients with posterior fossa tumors. This include compensation for diplopia, traction of intracranial structures, herniation of the cerebellar tonsils, or irritation of the spinal accessory nerve because of the impacted cerebellar tonsils in the foramen magnum.<sup>2,9</sup> Also, posterior fossa tumor may grow rapidly.<sup>2</sup> Thus, torticollis may be followed by vomiting or headache, from the intracranial pressure increase.

Extremiera *et al.*<sup>4</sup> have emphasized that torticollis should not be attributed to the posterior fossa tumor if it is the only presenting symptom. In contrast, our case suggests that torticollis can present as the only initial symptom of posterior fossa tumor, with no associated symptom.

In conclusion, careful history taking and neurological examination are necessary in children presenting with torticollis. Physicians should consider the possibility of posterior fossa tumor, even when torticollis is the only symptom.

## REFERENCES

1. Gupta AK, Roy DR, Conlan ES, Crawford AH. Torticollis secondary to posterior fossa tumors. *J Pediatr Orthop* 1996; 16:505-7.
2. Tomczak KK, Rosman NP. Torticollis. *J Child Neurol* 2013; 28:365-78.
3. Osborn AG. Osborn's Brain: Imaging, Pathology, and Anatomy. 1st ed. Philadelphia: Lippincott Williams & Wilkins, 2013: 1055-76
4. Extremera VC, Alvarez-Coca J, Rodríguez GA, Pérez JM, de Villanueva JL, Díaz CP. Torticollis is a usual symptom in posterior fossa tumors. *Eur J Pediatr* 2008; 167:249-50.
5. Caress JB, Nohria V, Fuchs H, Boustany RM. Torticollis acquired in late infancy due to a cerebellar gangliocytoma. *Int J Pediatr Otorhinolaryngol* 1996; 36:39-44.
6. DeBenedictis CN, Allen JC, Kodsí SR. Brainstem tumor presenting with tearing, photophobia, and torticollis. *J AAPOS* 2010; 14:369-70.
7. Agrawal A, Cincu R, Joharapurkar SR, Bhake A, Hiwale KM. Hemorrhage in brain stem cavernoma presenting with torticollis. *Pediatr Neurosurg* 2009; 45:49-52.
8. Turgut M, Akalan N, Bertan V, Erbenli A, Eryilmaz M. Acquired torticollis as the only presenting symptom in children with posterior fossa tumors. *Childs Nerv Syst* 1995; 11:86-88.
9. Kumandaş S, Per H, Gümüş H, *et al.* Torticollis secondary to posterior fossa and cervical spinal cord tumors: report of five cases and literature review. *Neurosurg Rev* 2006; 29:333-8.